

A STUDY OF INCIDENCE AND RISK FACTORS OF RETINOPATHY OF PREMATURITY IN PRETERM INFANTSD. Saminathan¹, B. Mythili², K. Senthil Kumar³, E. Sengodi⁴**HOW TO CITE THIS ARTICLE:**

D. Saminathan, B. Mythili, K. Senthil Kumar, E. Sengodi. "A Study of Incidence and Risk Factors of Retinopathy of Prematurity in Preterm Infants". Journal of Evolution of Medical and Dental Sciences 2015; Vol. 4, Issue 35, April 30; Page: 5995-6001, DOI: 10.14260/jemds/2015/874

ABSTRACT: Retinopathy of prematurity is a disease of the eye that generally affects premature babies receiving intensive neonatal care. Development of ROP is contributed by both oxygen toxicity and relative hypoxia. The primary Aim of the study to find out the incidence of ROP among preterm infants admitted in MGM Govt. Hospital, Trichy from August 2014 to December 2014. The study also evaluates the various risk factors for development of ROP and the association between the two. All preterm babies less than 36 weeks are included in the study. Totally 150 preterm babies were studied. Of this 150 babies 48 babies were diagnosed with the ROP, incidence was 32%. Among the fetal risk factors RDS in 113 babies (75.33%), phototherapy in 86 babies (57.3%), Oxygen administration in 66 babies (44%), Sepsis in 49 babies (32.6%), blood transfusion in 22 babies (14.6%) screened for ROP. Among maternal risk factors, pregnancy induced hypertension in 32 (21.3%), Gestational diabetic in 14(9.3%) mothers of screened babies. In conclusion, timely screening and early management is a key to the management of ROP.

KEYWORDS: A Study of Incidence and risk factors of Retinopathy of Prematurity in Preterm infants.

INTRODUCTION: Retinopathy of prematurity (ROP), previously known as retrolental fibroplasias (RLF) is a disease of the eye that generally affects premature babies receiving intensive neonatal care. It is thought to be due to disorganized growth of retinal blood vessels which results in scarring and retinal detachment. Mild ROP resolves spontaneously but serious cases may lead to blindness. All preterm babies are at risk for ROP, and very low birth weight is an additional risk factor. Development of ROP is contributed by both oxygen toxicity and relative hypoxia.

Childhood blindness is important not only in terms of economic burden but also due its severe social implications. The incidence of childhood blindness globally is 1.4 million of which 40% is preventable.¹ Retinal causes account for 22% of childhood blindness of which retinopathy of prematurity,² figures amongst the most frequent etiologies in middle and high income countries. In western countries, the incidence of retinopathy of prematurity in babies whose birth weight is less than 1000gm and 28 weeks of gestation is 40–60%, laser therapy,³ is required in 5-10% of these cases.

Compared to western countries the reported low incidence of ROP in India is possibly due to the low survival rate of children with birth weight less than 1000gms in rural and semi urban settings or the frequent occurrence of intrauterine growth retardation in Indian mothers who often suffer from anemia and under nutrition. Babies born with a birth weight less than 1500gm have a 20-50% chance of developing ROP of any stage and 7% chances of developing threshold ROP. Infants born with a birth weight less than 750 gm have a 90% chance of developing ROP. In preterm infants with birth weight of 1000-1250gms, around 47% develop ROP (any stage).⁴ ROP regresses spontaneously in most cases however in a few infants with severe disease ROP progresses to retinal detachment and visual loss.

ORIGINAL ARTICLE

AIM & OBJECTIVE OF THE STUDY:

Primary Outcome: To find out the incidence of ROP in preterm infants.

Secondary Outcome: To evaluate the various risk factors for development of retinopathy of prematurity and to assess the association between the ROP and the risk factor.

MATERIALS AND METHODS: This prospective, observational study of 'Analysis of risk factors in the development of retinopathy of prematurity in tertiary care institute was done from Aug. 2014 to Dec. 2014. Informed consent was obtained from parents prior to enrolment.

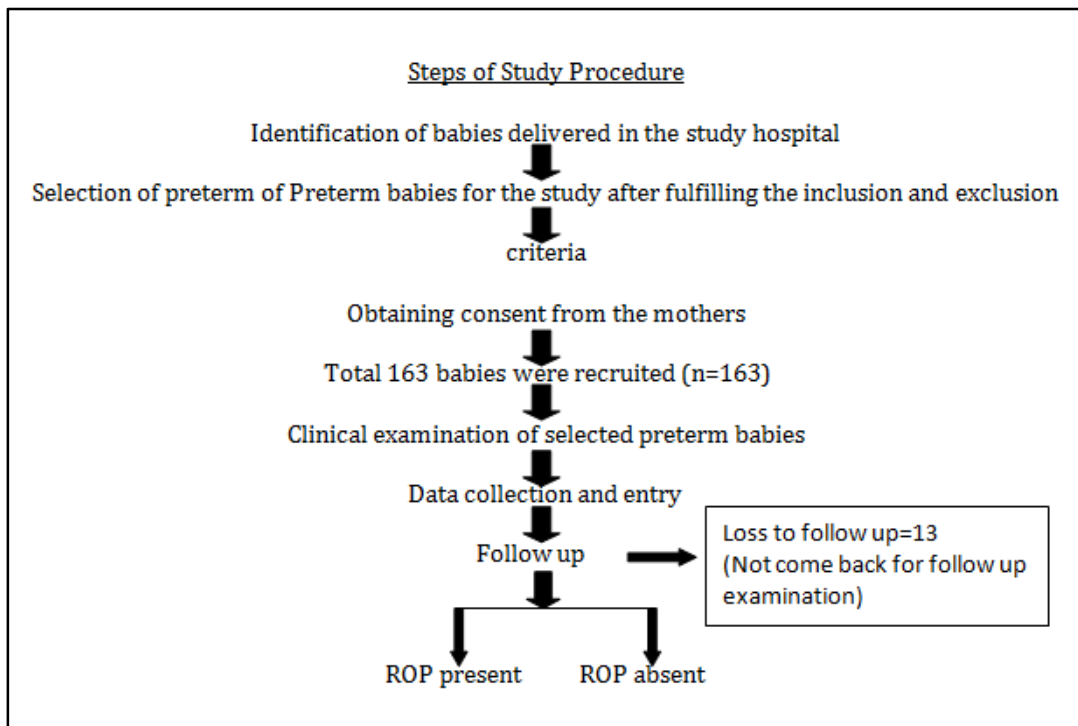
Inclusion Criteria: Gestational age at birth of less than 36 weeks.

Exclusion Criteria:

- Term babies.
- Congenital anomalies.

Calculation of Sample Size: Retinopathy of prematurity (ROP) is estimated to occur in 20-40% of preterm infants. For calculation of a relevant sample size for the current study, a figure of 30% was chosen. To achieve a precision of 8 % (0.08) with a confidence interval of 95%, the sample size was calculated to be $N = [1.96^2 \times 0.3 \times (1-0.3) / (0.08)^2] = 126$ patients. Total 150 preterm babies were studied by consecutive sampling.

Study Protocol:



ORIGINAL ARTICLE

During the study period of 6 months, the preterm babies delivered in the hospital setting were enrolled for the study. Based on inclusion and exclusion criteria selected babies were screened at 31–32 weeks of post conceptional age or 3 to 4 weeks of chronological age whichever was later. “30 days rule” refers to screening at 4 weeks after birth, when post conceptional age cannot be calculated.

Usually screening is not done in the first 2 weeks of life. All preterm babies who satisfied the inclusion criteria underwent ROP screening constituted the study group. The birth details, antenatal details and treatment details of the babies were recorded in the ROP proforma. The screening was carried out in the new born intensive care unit.

The pupils were dilated with a Mixture of phenylephrine 2.5% and tropicamide 0.5% is used to dilate the pupil. It is instilled for 3 times at interval of 10 mins about 1 hr. before the scheduled examination. Care was taken that the baby not fed 1hr before the examination because the child might vomit or aspirate. The nature of examination was explained to the parents and informed consent was obtained. Indirect ophthalmoscope was used for the retinal examination. The eyelids are kept apart by the pediatric eye speculum. Examination was carried out under aseptic precaution with the help of 20 D lens and pediatric depressor to stabilize the globe. None of the baby developed cyanosis, apnea or hypothermia during examination.

The international classification (ICROP) was used to document all retinal examination findings.⁵The findings were noted in ROP proforma where in birth and the treatment details of the baby were already noted. Depending upon the initial findings further follow up examination was decided. Those babies with ROP were given further appointments depending upon the stage of ROP and zone of the disease. Screening was continued till term gestation. Follow-up examinations were completed when the retina was fully vascularized. After inclusion of preterm babies in studies those who lost to follow up were not included in the analysis.

RESULTS:

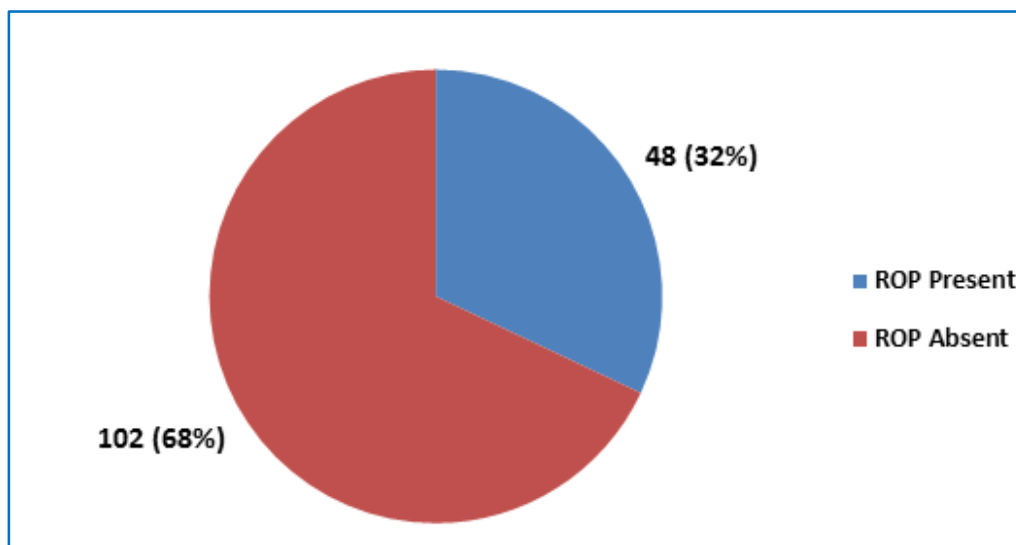


Fig. 1: Incidence of ROP in preterm infants

ORIGINAL ARTICLE

Gestational AGE	ROP		Total
	Present	Absent	
26-30 wks (EPT)	18	4	22
31-34 wks (MPT)	27	68	95
35-36 wks (LPT)	3	30	33
Total	48	102	150

Table 1: Preterm vs. ROP

$X^2=33$ p-value=0.000.

Birth weight category	Retinopathy of prematurity		Total
	Present	Absent	
Extremely low birth weight (ELBW)	6	0	6
Very low birth weight (VLBW)	25	32	57
Low birth weight (LBW)	17	63	80
Normal	0	7	7
Total	48	102	150 (100%)

Table 2: Birth weight vs. ROP

$X^2=23$ p-value=0.000.

Risk Factors		ROP		X ² Value	P-Value
		Present	Absent		
RDS	Present	45	68	12.8	0.000
	Absent	3	34		
CHD	Present	1	11	3.3	0.06
	Absent	47	91		
Oxygen therapy	Present	27	39	4.2	0.03
	Absent	21	63		
Sepsis	Present	20	29	2.5	0.1
	Absent	28	73		
Blood Transfusion	Present	12	10	6.0	0.01
	Absent	36	92		
Phototherapy	Present	29	57	0.2	0.6
	Absent	19	45		
GDM	Present	2	12	2.2	0.13
	Absent	46	90		
PIH	Present	8	24	0.9	0.3
	Absent	40	78		

Table 3: Various Risk factors vs. ROP

Those variables significant (p, 0.05) in bivariate analysis are taken for multivariate analysis.

ORIGINAL ARTICLE

Risk Factors	Adjusted Odds Ratio	95% CI	p-value
Gestational age	Ref cat		
• 35-36 weeks	3.8	0.865-16.8	0.077
• 31-34 weeks	51.3	5.88-449.4	0.000
• 26-30 weeks			
Birth weight (grams)	0.678	0.17-2.6	0.57
RDS	6.7	1.5-30.0	0.012
CHD	0.1	.009- 1.91	0.059
O2 therapy >2 weeks	0.629	.21-1.8	0.401
Sepsis	1.6	0.59-4.3	0.342

Table 4: Multivariate analysis (multiple logistic regressions) of various risk factors

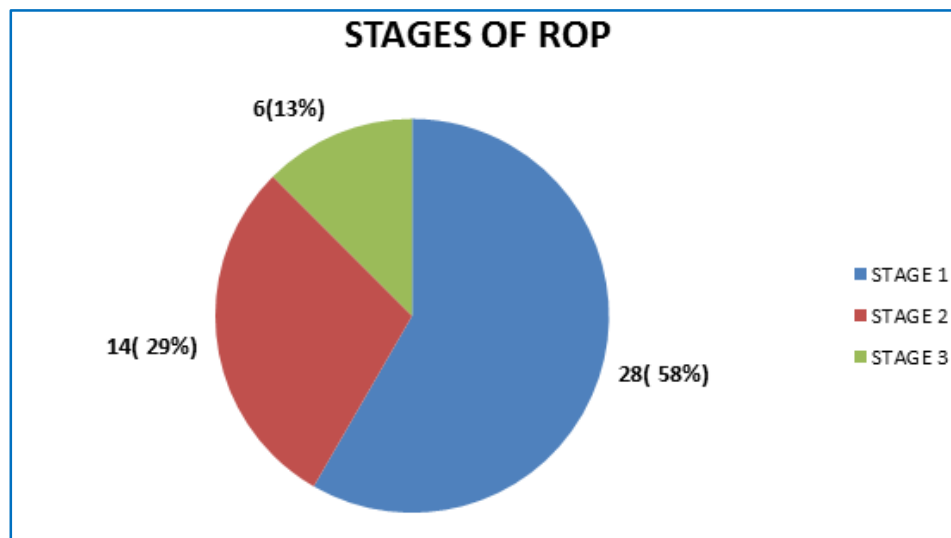


Fig. 2

DISCUSSION: Retinopathy of prematurity is a vasoproliferative disorder predominantly occurring in premature infants. Normal vasculature in the developing retina is interrupted due to several proposed theories. After a latent period, neovascularization may develop due to abnormal vasoactive signal. If this continues abnormally then the progressive retinopathy may result to retinal detachment and blindness. So, timely screening and prompt intervention is of utmost importance.

In this study, 150 babies were screened for ROP. Of these, 48 babies were diagnosed with ROP. Thus, the overall incidence of ROP in this study was 32%. The criteria for screening differ across different units and time. In India previous studies report that overall ROP incidence varies from 20% to 30%.⁶

ORIGINAL ARTICLE

The American Academy of Pediatrics (AAP) recommends ROP screening for babies born at ≤ 28 weeks gestational age and/or ≤ 1500 g birth weight regardless of supplemental oxygen, for babies with birth weight 1500 to 2000 g if supplemental oxygen was administered and the babies with an unstable clinical course. In contrast in India and in other Asian countries ROP is seen in larger BW babies. Previous study in Indian Journal of Ophthalmology from post-graduate institute Chandigarh found a significant percentage of ROP with severe stage in babies with birth weight more than 1250 gms. In India because of the finding of larger babies with ROP, Jalali et al have recommended screening the babies born at ≤ 37 weeks gestational age and with birth weight of 2000 g in the presence of high sickness score. This avoids missing of larger infants with threshold ROP which was not identified using Western screening criteria.⁷

In bivariate analysis there was a significant relationship between occurrence of ROP and RDS ($P=0.000$), Oxygen therapy ($P=0.03$) and Blood transfusion ($P=0.01$). But on multivariate analysis only gestational age and RDS were statistically significant. On the other hand, there was no significant relationship between the occurrence of ROP and congenital heart disease ($P=0.06$), sepsis ($P=0.1$), phototherapy ($P=0.6$), GDM ($P=0.13$), PIH ($P=0.3$).

In this study, among the fetal risk factors the major risk factors were RDS in 113 babies (75.33%), phototherapy in 86 babies (57.3%), oxygen administration in 66 babies (44%), sepsis in 49 babies (32.6%), blood transfusion in 22 babies (14.6%) screened for ROP.

Among maternal risk factors, the major risk factor found were pregnancy induced hypertension (PIH) in 32(21.3%), GDM in 14(9.3%) mothers of the screened babies. It was not statistically significant.

Chaudhari et al,⁸ at KEM hospital, pune conducted a prospective observational study. Out of 552 babies screened, 123 babies had ROP. The ROP incidence was 22.3%. Risk factors for ROP were apnea ($P=0.0001$), septicaemia ($P<0.001$), and oxygen therapy ($P=0.031$).

Gupta et al,⁹ conducted a study at University medical college GTB hospital, Delhi. He revealed that Apnea ($p=0.008$), Exchange transfusion ($p=0.03$), Septicemia ($p=0.04$) and Hyaline membrane disease ($p=0.02$) as a clinically significant risk factors for ROP.

CONCLUSION: In India, ROP is emerging as a leading cause of preventable childhood blindness. The word 'preventable' suggests that there exists an effective treatment which helps to prevent disease progression. The challenge is to simply identify the individuals that would benefit from vision- saving therapy. Timely screening and early management is the key to the management of ROP.

REFERENCES:

1. Report of WHO/IAPE scientific meeting on preventing Blindness in children. Programme for presence of Blindness & international agency of prevention of Blindness Geneva 2000.
2. WHO Bulletin 2001. Childhood Blindness in the contact of vision 2020 – The Right to sight.
3. Flynn J T 1987 Retinopathy of Prematurity PCNA 34 1487 – 1516.
4. Saunders RA, Donahue ML, Christmann LM, et al. Racial variation in retinopathy of prematurity. The Cryotherapy for Retinopathy of Prematurity Cooperative Group. Arch Ophthalmol 1997; 115: 604-8.
5. Snir M., Nissenkorn I., Sherf I, et al 1988 "Visual acuity, strabismus and amblyopia in premature babies with and without retinopathy of prematurity" Ann Ophthalmol 20: 256-58.

ORIGINAL ARTICLE

6. Stout, A. U., Stout, A. J. 2003 “Retinopathy of Prematurity” Pediatric Clin. North Am 50: 77-87.
7. Antonia M. Jousen MD, PhD, Thomas W. Gardner MD, MS, Retinal Vascular Disease, Springer-Verlag Berlin Heidelberg New York, 2007 edition.
8. Chaudharai S, Vidyadhar P, Umesh V et. al. Retinopathy of prematurity in tertiary care centre-incidence risk factors and outcome. Indian Pediatrics 2009; 46: p 219-224.
9. Gupta VP, Dhaliwal U, Sharma R, Gupta P, Rohatgi J. Retinopathy of prematurity—risk factors. Indian J Pediatr 2004; 71: 887-92.

AUTHORS:

1. D. Saminathan
2. B. Mythili
3. K. Senthil Kumar
4. E. Sengodi

PARTICULARS OF CONTRIBUTORS:

1. Professor & HOD, Department of Paediatrics, KAPV Government Medical College, Periyamilaguparai, Trichy, Tamilnadu.
2. Associate Professor, Department of Paediatrics, KAPV Government Medical College, Periyamilaguparai, Trichy, Tamilnadu.
3. Assistant Professor, Department of Paediatrics, KAPV Government Medical College, Periyamilaguparai, Trichy, Tamilnadu.

FINANCIAL OR OTHER

COMPETING INTERESTS: None

4. Junior Resident, Department of Paediatrics, KAPV Government Medical College, Periyamilaguparai, Trichy, Tamilnadu.

NAME ADDRESS EMAIL ID OF THE CORRESPONDING AUTHOR:

Dr. D. Saminathan,
Professor & HOD,
Department of Pediatrics,
KAPV Government Medical College,
Periyamilaguparai, Trichy-620001,
Tamilnadu, India.
E-mail: saminathan_d@yahoo.co.in

Date of Submission: 08/04/2015.
Date of Peer Review: 09/04/2015.
Date of Acceptance: 22/04/2015.
Date of Publishing: 28/04/2015.