

**EXTERNAL FIXATOR IN THE MANAGEMENT OF UNSTABLE PELVIC FRACTURES**S. Devi prasad<sup>1</sup>, Karthik Neelakandan<sup>2</sup>, C. S. Krishnamurthy<sup>3</sup>**HOW TO CITE THIS ARTICLE:**

S. Devi Prasad, Karthik Neelakandan, C. S. Krishnamurthy. "External Fixator in the Management of Unstable Pelvic Fractures". Journal of Evolution of Medical and Dental Sciences 2014; Vol. 3, Issue 37, August 21; Page: 9708-9716, DOI: 10.14260/jemds/2014/3256

**ABSTRACT:** Universally, high- energy trauma is the major cause of mortality and morbidity in the younger age group. Usually pelvic fractures are caused by high energy trauma. Hence it affects not only the musculoskeletal system, but also the soft tissues and viscera contained in the pelvis leading to increased mortality and morbidity. Management of such patients remains a challenge to the trauma surgeon, even in the most sophisticated trauma centers. The aim of our study is to evaluate the role of external fixation in the management of pelvic fractures, both as a resuscitative measure and definitive treatment of unstable pelvic fractures (Type B & Type C). In our study, all patients underwent stabilization with external fixator and the mortality rate was zero with additional internal fixation with reconstruction plating being done in three patients. The primary advantage of external fixation in pelvic injury is to maintain the reduction by which it produces a tamponade effect and results in reduction in haemorrhage, and helps transportation of the patient. External stabilization for unstable pelvic fractures with external fixator is an established treatment procedure and we in our study confirm the usefulness of the procedure in an emergency situation and can be continued effectively as a definitive management for type B & C Pelvic injuries.

**KEYWORDS:** pelvic fracture, external fixator.

**INTRODUCTION:** Universally, high- energy trauma is the major cause of mortality and morbidity in the younger age group. The implication of losing a young active member of the population is obvious in terms of personal, social and economic losses to the family as well as to the nation. The mortality of major pelvic fractures, despite improvements in management, constitutes to be about 10% (McMurtry et al, 1980; Goldstein et al, 86; Hesp et al, 1985)<sup>1, 2, 3</sup>.

Recent literatures on pelvic fractures have emphasized that the incidence of the injury is steadily increasing. Usually pelvic fractures are caused by high energy trauma. Hence it affects not only the musculoskeletal system, but also the soft tissues and viscera contained in the pelvis leading to increased mortality and morbidity. Management of such patients remains a challenge to the trauma surgeon, even in the most sophisticated trauma centers.

Many advances have been made in the general management of poly trauma patients and so trauma surgeon should be well versed not only in the biomechanics of these complicated fractures but also needs wide experience in management of shock, hemorrhage, electrolyte imbalance as well as injury to the urogenital tract and bowel<sup>4</sup>. Many modalities of stabilization of pelvic fractures have been offered but the stabilization of pelvic fractures by external fixation has created a sea change in the management of poly trauma victims.

External fixation plays not only a part of resuscitative measure altering dramatically, the survival rate<sup>5, 6</sup>. Since the stabilization of pelvic fractures reduces the hemorrhage inside the pelvic ring, apart from the temporary role, external fixation also affords definitive treatment.

## ORIGINAL ARTICLE

---

The role of external fixation in the management of pelvic fractures as a temporary measure is recorded by various authors. Many have claimed good results in the functional aspect following external stabilization.

**AIMS AND OBJECTIVES:** The aim of the study is to evaluate the role of external fixation in the management of pelvic fractures, both as a resuscitative measure and definitive treatment of unstable pelvic fractures (Type B & Type C).

**MATERIALS AND METHODS:** Adult patients with unstable pelvic fractures treated with external fixator were taken up for the study. This is a prospective study and patients with pelvic fractures who came to Rajah Muthiah Medical College & Hospital between the periods of May 2006 to September 2008 were included for the study.

**INCLUSION CRITERIA:** All unstable pelvic fractures (Type B & Type C)

**EXCLUSION CRITERIA:** Stable pelvic fractures, associated head injury.

**AGE AND SEX RATIO:** Ten patients were included for the study. The age of the patients ranged from twenty three years to fifty five years. Nine patients were male and one was female.

**MODE OF INJURY:** Motor vehicle accident (nine patients) and fall from height (one patient).

**GENERAL ASSESSMENT:**

**History:** Complete history is taken to assess the mechanism of injury and the pattern of fracture.

**Physical Examination:** Trauma patients were evaluated based on guidelines established by the American college of surgeons (1981). Overall hemodynamic status of the patients was evaluated. The pelvis was assessed by palpation at the anterior superior iliac spines and by gentle compression of iliac wings together to expose instability in internal rotation, and then by gentle distraction of the wings apart to expose instability in external rotation.

The skin including the perineum was examined for lacerations. Any scrotal or labial hematomas caused by pelvic hemorrhage were noted. All trauma patients underwent digital rectal examination and in females examination of the vagina was done, because bony fragments may lacerate through the rectal or vaginal walls, creating an open fracture that cannot be appreciated externally.

**INVESTIGATIONS:** Management of pelvic injury depends on whether it is stable or unstable. To find out this, radiological evaluation is mandatory and appropriate X-rays were ordered which included Anteroposterior view, Inlet & Outlet views. Abdominal Ultrasound and 3D – CT.

**MANAGEMENT PROTOCOL:** Patients in shock, clinically diagnosed unstable pelvic fractures were immediately stabilized by external fixation under anesthesia, either local or general. Management is based on the concept of pelvic ring stability and the type of injury.

**EXTERNAL SKELETAL FIXATION:****Frame design:** 3 types:

1. Rectangular, 2. Trapezoidal, 3. Double pin cluster. We mostly used the rectangular frame.

**Instruments:** Schanz screw (4.5 or 5 mm), Self-holding clamp, Hand drill, Spanner, Connecting tubes or rods.**Technique of External Fixation:** Under anesthesia, the patient is placed in supine position. The anterior superior iliac spines, the inner and outer tables of iliac crest were identified by palpation. Under aseptic precautions with use of hand drill, two or three threaded schanz screws are inserted between the anterior superior iliac spine and iliac tubercle with a space of about 2 cm between each pin and the pins are directed inferomedially.

A straight rod is employed to bridge the pins. The same procedure is repeated on the other side of the pelvis. Then traction is given to correct the migration and compression is applied to reduce the diastasis. Supportive treatment with adequate intra-venous fluids and blood transfusions were given to restore hemodynamic status. General surgical and urological consultations and interventions were given when required.

**Post - Operative Management:** On the day after external fixation the patient is encouraged to turn side to side for nursing purpose and to adapt an upright position in bed, adjustments in alignments are undertaken as and when necessary. Routine pin tract care is initiated.**SECONDARY PROCEDURES:** Rotationally unstable pelvic injuries with significant limb-length discrepancy of more than 1.5 cm. 3.5 mm reconstruction plate was advocated for open reduction and internal fixation. Out of ten patients, three of them were treated with open reduction and internal fixation by using reconstructive plate and in seven patients, anterior external fixator was used as definitive treatment.

One patient, who had liver laceration, underwent emergency laparotomy with peritoneal lavage and omental plugging. Patella tendon repair was carried out in one patient who had complete rupture of the patella tendon in the right limb. One patient had associated fracture shaft and neck of left femur for which recon nail was applied.

**REHABILITATION:** Patients with posterior complex intact, without other major soft tissue injuries are allowed to sit in the first week; to walk with partial weight bearing from six weeks onwards. Patients with posterior complex disruption are given delayed weight bearing between 10 to 12 weeks.

Fixators were removed after 6-8 weeks after the union of fracture which is confirmed by clinical and radiological assessment. Vigorous active exercises for hips were encouraged.

**FOLLOW UP:** Cases were followed up periodically by clinical and radiological assessment for 2 years. The functional outcome was assessed using Majeed's scoring system<sup>7</sup> modified by Lindahl et. Al<sup>8</sup>.

## ORIGINAL ARTICLE

A numerical scoring system is used, six criteria were chosen for functional assessment, after major pelvic fractures with external fixation, which includes evaluation of pain, sitting, sexual intercourse, walking aids, gait unaided and walking distance.

Each of these clinical parameters was scored. Total score were given a clinical grade as excellent, good, fair or poor.

Functional outcome (total score)	Points
Excellent	78 to 80
Good	70 to 77
Fair	60 to 69
Poor	< 60

**RESULTS & ANALYSIS:** Ten patients who presented to our institute with Type B and Type C pelvic ring disruptions according to TILES classification<sup>9</sup>, from May 2006 to September 2008 were considered for this prospective study.

**AGE:** This study has patients of different age groups, among them youngest patients is 23 years and rest of them are between 35 – 50 years.

**TIME OF PRESENTATION SINCE INJURY:** 70% of patients had presented within 2 hours of injury and the rest 30% presented after 2 hours of injury, the earliest patient to report was within 1 hour and thirty minutes and the longest time to present since injury was 6 hours.

Age groups (years)	No. of patients
20 – 30	1
30 – 40	4
40- 50	3
50 – 60	2
<b>AGE INCIDENCE</b>	

Time since injury	No. of patients
1 -2 hrs	7
3 hrs	2
6 hrs	1
<b>TIME OF PRESENTATION SINCE INJURY</b>	

**TYPE OF FRACTURE:** The fractures were classified according to Tiles classification<sup>9</sup>, in which Type B with 6 patients was the commonest and Type C was found in 4 patients.

**ASSOCIATED INJURIES:** Six patients had associated injuries, four patients sustaining other fractures, one patient had liver laceration, one patient had rupture of the right patella tendon and one patient sustained urethral injury.

## ORIGINAL ARTICLE

**ADDITIONAL PROCEDURES:** Additional operative procedures included Recon plating for pubic symphysis in 3 patients, patella tendon repair in 1 patient, Recon nailing for femur for 1 patient and laparotomy with peritoneal lavage and omental plugging in 1 patient.

**DURATION IN FIXATOR:** In one patient it was removed in about 8 weeks and in nine patients the fixator was removed in 6 weeks.

Type of fracture*	No. of patients
Type B	6
Type C	4
<b>TYPE OF FRACTURE</b>	

\* Tile's classification<sup>9</sup>

Associated injuries	No. of patients
Other fractures	4
Liver laceration	1
Rupture of the rt patella tendon	1
Urethral injury	1
<b>ASSOCIATED INJURIES</b>	

Procedures	No. of patients
Recon plating	3
Patella tendon repair	1
Laparotomy with peritoneal lavage and omental plugging	1
Recon nailing for femur	1
<b>ADDITIONAL PROCEDURES</b>	

**WEIGHT BEARING:** Decision about weight bearing and frame removal were made individually for each patient. Non-weight bearing exercise in bed was started at around 8 weeks. Partial weight bearing was started after 12 weeks and patients were gradually allowed full weight bearing over the period of further 4-8 weeks depending upon their clinical and radiological findings.

**COMPLICATIONS:** Two patients developed pin tract infection of external fixator. In one patient, infection healed on treatment with dressings and antibiotics and in another patient infection settled with removal of the external fixator. There were no deep infections.

**OTHER COMPLICATIONS:** Other complications includes pulmonary embolism with foot drop in one case, knee stiffness in two cases and pin loosening in one case.

**FUNCTIONAL OUTCOME:** The functional outcome was assessed using modified Majeed's scoring system.

## ORIGINAL ARTICLE

---

Functional outcome (total score)	Points	No. of patients
Excellent	78 to 80	2
Good	70 to 77	5
Fair	60 to 69	3
Poor	< 60	Nil

**DISCUSSION:** As pelvic fracture is a life threatening emergency appropriate, rapid and careful general assessment and precise radiological studies are carried out to determine the displacement and degree of instability present in order to plan the management.

In type B1 open book injury, stabilization may be indicated to reduce the pelvic volume in the acute phase, and in the rare type B lateral compression injury, external fixation pins may aid in reduction. The mortality of major pelvic fractures, despite improvement in management, continues to be about 10%

In our study of 10 patients, all required stabilization with external fixator and the mortality rate was zero and additional internal fixation with reconstruction plating was done for three patients.

Lange,<sup>10</sup> Pennal,<sup>11</sup> have illustrated that vertical movements occur at the injured symphysis pubis in spite of clinical and radiological parameters that suggest vertical stability of pelvis. It was recommended that superiorly placed 3.5 mm reconstruction plate is not strong enough to provide rigid internal fixation.

Ghanayem et al<sup>12</sup> (1995) have shown that abdominal wall provides stability to an unstable pelvic ring injury via a tension band effect on the iliac wings. Their results demonstrate that a laparotomy further destabilized an open –book pelvic injury and subsequently increased pelvic volume and pubic diastasis.

In our study of ten patients, one patient (10%) had liver laceration for which peritoneal lavage with omental plugging was done. Patient was stabilized with external fixation before laparotomy was done.

The primary advantage of external fixation in pelvic injury is to maintain the reduction by which it produces a tamponade effect and results in reduction in hemorrhage, and helps in transportation of the patient. The disadvantage was found to be minimal which includes pin tract infection and pin loosening.

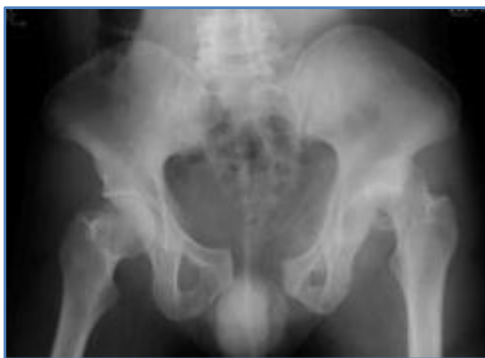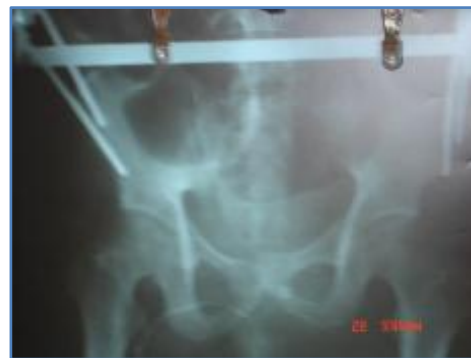Thus an external stabilization for unstable pelvic fracture with external fixator is already an established treatment procedure and we in our study confirm the usefulness of the procedure.

**CONCLUSION:** Fracture pelvis is a major cause for mortality and morbidity and External stabilization with external fixator decreases both morbidity and mortality. It is a simple and minimally invasive method and can be readily applied even under local anesthesia.

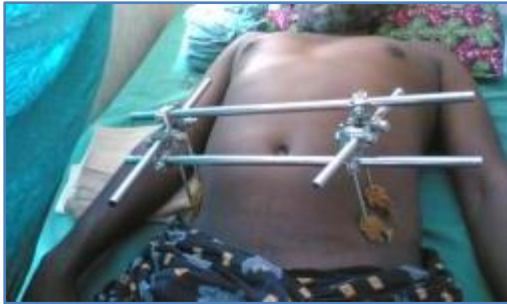Thus an external stabilization for unstable pelvic fractures with external fixator is an established treatment procedure and we in our study confirm the usefulness of the procedure in an emergency situation and can be continued effectively as a definitive management for type B & C Pelvic injuries.

**BIBLIOGRAPHY:**


1. McMurtry R, Walton D, Dickinson D, Keilam J, Tile M. Pelvic disruption in the polytraumatized patient : a management protocol. Clin Orthop 1980; 151 22-30.
2. Goldstein A, Phillips T, Sclafani SJA, et al. Early open reduction and internal fixation of the disrupted pelvic ring. J Trauma 1986; 26:325-33.
3. Hesp WL, van der Werken C, Keunen RW, Goris RJ. Unstable fractures and dislocations of the pelvic ring: results of treatment in relation to the severity of injury. Neth J Surg 1985; 37:148-52.
4. Bassam D, Cephas GA, Ferguson KA, Beard LN, Young JS. A protocol for the initial management of unstable pelvic fractures. Am surg. 1998 Sep; 64(9): 862 – 7.
5. Slatis et al. External fixation of pelvic fractures. Clinical Orthopaedics and Related Research 151, 1980, 73 – 80.
6. J F Kellam. The role of external skeletal fixation in pelvic disruptions. Clinical Orthopedics' and Related Research No. 241 April 1989, 66 – 80.
7. S A Majeed. Grading the outcome of pelvic fractures. Journal of Bone and Joint surgery, 1989, British Volume, Vol 71-B, Issue 2, 304-306.
8. J Lindahl et al. Failure of reduction with an external fixator in the management of pelvic ring injuries. Journal of Bone and Joint surgery [ Br ] 1999;81-B;955-62.
9. Tile M. Classification of pelvic ring disruption. J Am Assoc Orthop Surg 4: 143, 1996.
10. Lange RH, Hansen ST JR. Pubis diastasis. Indications Pelvic ring disruptions with symphysis. Clinical Orthopaedics & Related Research. [JC;dfy] (201): 130 – 7, 1985Dec.
11. Pennal George, Marvin Tile. Pelvic disruption assessment and classification. Clinical Orthopaedics and Related Research 151 Sep 1980 12 – 21.
12. Ghanayem Alexander J, Wilber John H, Lieberman James M, Motta Antonio O. The effect of laparotomy and external fixator Stabilization on pelvic volume in an unstable pelvic injury. Journal of Trauma – Injury Infection & Critical Care. 38 (3): 396 – 401, March 1995.

**CASE 1****Pre - Op X-ray****Post - Op X-ray**

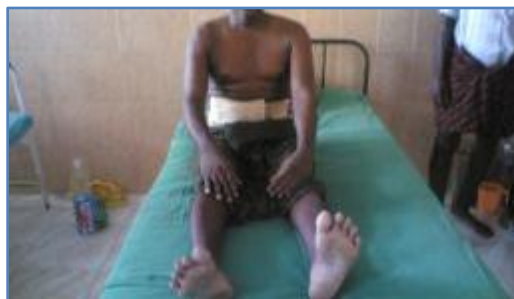# ORIGINAL ARTICLE



**Immediate Post-op**

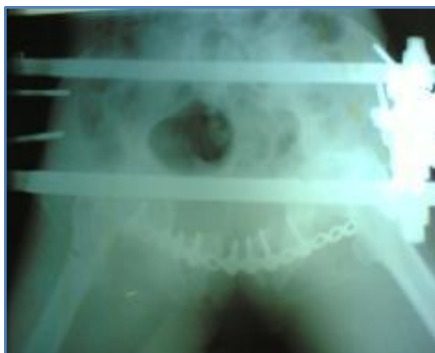

**7 days post-op**

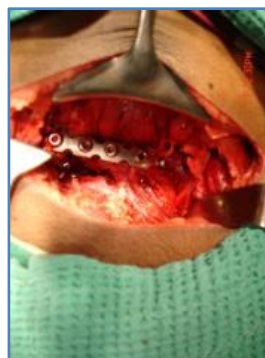

**6 weeks Post-op**

## CASE 2



**External Fixator with Recon plating**



**Intra - Op**



## ORIGINAL ARTICLE

---

### **AUTHORS:**

1. S. Devi prasad
2. Karthik Neelakandan
3. C. S. Krishnamurthy

### **PARTICULARS OF CONTRIBUTORS:**

1. Assistant Professor, Department of Orthopaedics, SRM & RC.
2. Assistant Professor, Department of Orthopaedics, SRM & RC.
3. Professor, Department of Orthopaedics, RMMCH.

### **NAME ADDRESS EMAIL ID OF THE CORRESPONDING AUTHOR:**

Dr. S. Devi prasad,  
Assistant Professor,  
SRM Medical College.  
Email: deviprasadortho@gmail.com

Date of Submission: 11/08/2014.

Date of Peer Review: 12/08/2014.

Date of Acceptance: 18/08/2014.

Date of Publishing: 21/08/2014.