

PRE AURICULAR SINUS: A CLINICAL ANALYSIS OF 62 CASES AND REVIEW OF ITS MICRO SURGICAL MANAGEMENT

S. Indira Devi¹, S. Muneeruddin Ahmed², T. Shankar³, Manish Gupta⁴, K. V. N. Durga Prasad⁵

HOW TO CITE THIS ARTICLE:

S. Indira Devi, S. Muneeruddin Ahmed, T. Shankar, Manish Gupta, K. V. N. Durga Prasad. "Pre Auricular Sinus: A Clinical Analysis of 62 Cases and Review of its Micro Surgical Management". Journal of Evolution of Medical and Dental Sciences 2014; Vol. 3, Issue 62, November 17; Page: 13697-13704, DOI: 10.14260/jemds/2014/3830

ABSTRACT: INTRODUCTION: Pre auricular sinus (PAS) is a common clinical finding seen in the ENT outpatient department. The patients complain only when it is infected, when cheesy material is extruded often from the aural pit. Initial control of infection, incision and drainage of the abscess becomes the primary step in its treatment. This is followed by the attempt to excise the tract to avoid recurrence of cellulitis and abscess. Simple sinectomy leads to recurrence; hence requires microscopic dissection and excision. The present study attempts to analyze the genetic penetration, incidence in various socio-economic groups and at the same time to review the micro surgical management. **MATERIALS AND METHODS:** 62 patients diagnosed with Preauricular sinus attending department of ENT, GGH; Kurnool were analyzed for genetic role in its etiology in addition to the prevalence of the condition according to the social and economic status. Thorough clinical examination and where necessary audiological evaluation to rule out inner ear pathology was done. Bacteriological study was done subjecting the pus and material extruded from the sinus pits. After a surgical profile all the patients except 4 were subjected to Total excision of the sinus tract using circular incision around the sinus pit and extending it posteriorly around the root of the pinna. All were followed for a period of 12 months to evaluate recurrence rate, Infection rate and wound dehiscence. **OBSERVATIONS:** Among the 62 patients there were 37 females and 25 males. The patient's age range was from 9 months to 36 years. 18 patients had undergone surgery at least once before presenting in this study. The commonest organism isolated was Staph aureus followed by bacillus fragilis and pseudomonas aeruginosa. Incomplete gene penetration was noted in 34 out of the 62 patients, as PAS was noticed in parents, siblings and grandparents. Follow up showed no recurrence over 1 year. **CONCLUSIONS:** PAS is a congenital condition within complete genetic penetration; not commonly associated with inner ear or kidney disease. Recurrence is common if only sinectomy is attempted; instead total excision with medial to lateral dissection and post aural extension of incision would give an almost fool proof method to get rid of the sinus once for all.

KEYWORDS: Preauricular sinus, sinus, aural pit, sinus tract, gene penetration of PAS, PAS abscess.

INTRODUCTION: Pre auricular sinus (PAS) was first described by¹ Van Heusinger in 1864 and described it as a congenital condition.² It is a result of defective and incomplete fusion of the 6 hillocks of His.³ It may be probably due to a defect in the 1st brachial arch during the 6th IUL.⁴ Another hypothesis, less accredited, is that the sinus develops during embryonic auricular development from an isolated ectodermal folding. One third of the patients require no intervention; It's surgical excision becomes mandatory once it gets infected.⁵ It presents a high risk of recurrence when treated by a standard surgical technique (simple sinectomy), the incidence of which is reported to be between 19% and 40%. PAS is not an uncommon finding in ENT practice and usually appears like a small pit close to the anterior margin of the first ascending portion of the helix.

ORIGINAL ARTICLE

Sometimes an associated subcutaneous cyst lies in close proximity to the pit related to the tragal cartilage and the anterior crus of the helix.⁶ PAS has its course in pre auricular subcutaneous tissues, often tortuous, with many side branches, upwards and medially. PAS is superficial to temporalis fascia, lateral and superior to the parotid gland and facial nerve.⁴ Its terminal portion is very near, and often adhering to, the cartilage of the first portion of the helix Simple sinectomy leads to recurrence and PAS requires Microscopic excision with a keen eye to look for its ramifications and superior and posterior extensions, and to excise a sliver of tragal cartilage to which it is usually attached.

MATERIAL AND METHODS: 62 patients were diagnosed with PAS from among the patients attending the GGH; attached to Kurnool Medical College, Kurnool. These patients were attending the tertiary referral center of Rayalaseema districts of Andhra Pradesh. The patients were analyzed for family history of aural pits or sinuses, relation to the Social status, economic background and mode of presentation. All the patients were subjected to thorough ENT examination and where doubtful audiological and renal function examination was done to exclude syndrome involvement.

Pus for C/S was sent to isolate the organism and their sensitivity for antibiotics. Surgical profile was done prior to subjecting them for surgery. Except to 4 patients all the patients underwent Excision of PAS following the post aural extension surgical approach and method described by Prasad et al ⁷. The 4 patients who were not operated included those who had no signs of infection or cyst formation. All the patients were followed for a period of 1 year. Only 3 patients had wound dehiscence which was further treated by change of antibiotics. No incidence of hematoma formation and recurrence were noted at the end of 1st year.

OBSERVATIONS: 62 patients between attending unit I of the Department of ENT, Government General Hospital attached to Kurnool Medical College, Kurnool between August 2006 to June 2013 (7years) were diagnosed with PAS from among total out patient census of the General Hospital being 44000 over the same period. The incidence of PAS among the patients attending the GGH was 0.140%. The patients diagnosed with PAS (37) 59.67% females and (25) 40.33% males. The patient's age range was from 9 months to 36 years. 62% of the patients belonged to the age group of 6 to 20 years.

Age-Years	Male	Female	Number of cases	Percentage
0-5	04	05	09	14.51
6-10	06	07	13	20.96
11-15	06	08	14	22.58
16-20	03	07	10	16.12
21-25	03	05	08	12.90
26-30	02	04	06	09.67
31andabove	01	01	02	03.22
Total	25	37	62	

Table1: Age and Sex Incidence of PAS: n=62

62% of the patients belonged to the age group of 6 to 20 years

ORIGINAL ARTICLE

SEX	Number of patients	Percentage
Male	25	40.33
Female	37	59.67

Table 2: Sex ratio:

Side of involvement	Unilateral	Bilateral
Male	09	16
Female	19	18
Total	28	34
Percentage	45.16	54.83

Table3: Side of involvement in Males and Females

Low socio-economic group	23
Middle socio-economic group	22
High socio-economic group	17

Table 4: Incidence of PAS in Socio-economic group

There is no significant difference in the incidence of PAS among the socio-economic groups. Patients operated earlier in the same Hospital were also included in the present study. 62 patients were diagnosed with PAS over a period of 7 years which included 37 females (59.67%) and 25 males (40.33%). 34 patients (54.83%) had Bilateral PAS, among the males were 16 (25.80%) and females were 18 (29.03%). 28 patients presented with unilateral (45.16%) PAS, among them 09 were males (14.51%) and 19 were females (30.64%).

Bilateral PAS incidence was found more among the females when compared to males. Among the 34 patients with bilateral PAS the incidence among the parents was 16 (47.05%). Among the siblings it was found in 6 patients (17.64%). The history of incidence among the grand parents could be elicited only 12 of the 34 patients and it was found to be (35.29%). The patient's age range was from 9 months to 36 years.

Mode of Presentation	Number of patients	Percentage
No signs of infection	6	9.67
Abscess	08	12.90
Cyst formation	09	14.51
Ruptured	09	14.51
Unhealthy skin around pit	12	19.35
Operated once/twice/ 4times:Recurrent	18	29.03

Table 5: Mode of presentation of PAS; n=62

Type of Organism	Number of patients	Sensitivity to Co-amoxicillin	Sensitivity To Amikacin	Sensitivity To Ofloxacin
Staph Aureus	38	19	09	10
Bacillus fragilis	11	05	04	02
Pseudomonas	07	01	04	02
Negative to culture	06	--	--	--

Table 6: Pyogenic organism in PAS

ORIGINAL ARTICLE

Out of 62 patients 6 patients (9.6%) had no history of the pit or sinus getting infected at any given time, but consulted for the sake of aesthetic surgery. 38 patients among the total 62 patients had recurrent attacks of infection of the sinus, abscess formation, under gone Incision and drainage and infected cyst formation.

The number of times the sinus infected and treated medically or treated by incision could not be elicited accurately. Out of 62 patients 18 (29.03%) were consulting for failure of initial surgery and resulting in recurrent infection and abscess formation. 12 patient; 19.35% of the patients had earlier under gone surgery once earlier, 2 patients (3.22%) had under gone surgery twice before and 4 (6.45%) patients had under gone four times. The commonest organism isolated were Staph aureus; 38 (61.29%), Bacillus fragilis was seen in 11 (17.74%), Pseudomonas in 7 (11.29%) and culture was negative in the remaining.

The commonest antibiotic of sensitivity was Co-Amoxyclav; 19 for Staph aureus, 5 for Bacillus fragilis and 1 for pseudomonas organism. Similarly Amikacin was sensitive in 9 cases with Staph aureus, 4 cases of Bacillus fragilis and 4 cases of Pseudomonas. Ofloxacin sensitivity it was seen in 1 patient with Staph aureus, 2 with Bacillus fragilis and 2 with pseudomonas. There was no history of diminished hearing in any of the patients treated. None of the patients had renal or inner ear abnormalities. Microscope was used to excise the sinus with '6' magnification and a superior approach of (7) Prasad et al were used.

DISCUSSION: Patients with PAS present for medical attention only when the aural pits discharge odoriferous putty secretions or pus, abscess formation or cystic swelling near the pit. Patients who have under gone surgery also present with similar complaints if the sinus tract is not excised totally.

The incidence in the present study among the patients attending are feral Hospital is 0.140%. The incidence in USA is 0.1 to 0.9%, 0.47% in Hungary, 0.9% in England and 2.5% in Taiwan.^{8,9} The incidence of recurrence after a standard surgical procedure reported is between 19 and 40%. In the literature, a standard technique has been described (simple sinectomy); an elliptic skin incision around the sinus opening is taken and the ramifications of sinus are dissected from the subcutaneous tissues under vision or by palpation.¹⁰ Coatesworth AP suggests allowing only drainage of pus initially without interfering with underlying tissue to make further excision straight forward.

Suggestions for correct identification of the sinus tracts included use of a small lacrimal probe,¹¹ methylene blue intra-operative injection,^{6,12} Pre-operative sonographic imaging and Pre-operative sinograms.⁴ Each has its own limitations: the lacrimal probe trauma may result in false tract and follow small ramifications cannot be threaded; methylene blue diffusion into tissues makes identification of the smaller branching difficult. Fistulo-graphy needs experienced hands and cannot be done in acute stages, and offers only limited information about the sinus length and direction and nothing about its depth.⁶

These factors also play an important role in limited surgical excision and recurrence. Some surgeons report high recurrence rate in patients who underwent excision under local anesthesia compared to General anesthesia. In the present study, in our experience no such difference could be made out.⁸ In a study by Yeo et al, surgery performed under local infiltrative anesthesia has a higher rate of recurrence than cases receiving general anesthesia. The reasons explained by these authors are probably related to patient's limited compliance with surgical maneuvers and to confounding factors that infiltration itself represents. In the present study authors followed the surgical method employed by Prasad et al in 1990.⁷

ORIGINAL ARTICLE

In this procedure a supra-auricular extension of the elliptical incision around the sinus opening was given. This is based upon the theory that a fistula is, almost always, included in subcutaneous tissues between the temporalis fascia and perichondrium of the helix cartilage. This allows better visualization of the sinus tract, its ramifications, and associated cyst. The scar does not have adverse aesthetic problem. Dissection includes first identifying the temporalis fascia medial to the sinus area. The fascia represents medial and deep limit of the sinus tract. Dissection continues in a medium lateral direction until reaching the helix cartilage. At this juncture, dissection is made below the perichondrial layer.

At the point of maximum adherence of the fistula, excision of a small sliver of the cartilage is always advisable. In this type of dissection, one need not follow the fistula but, being aware of the space in which it develops, all subcutaneous tissue comprised between the temporalis fascia and the helix perichondrium is removed. In this tissue, the sinus is certainly present with its ramifications and the eventual cyst.¹³In a study by Rosslyn Anicete MD et al they found the mean age of the patients was 6.5. The overall recurrence rate was 2.4%; the overall complication rate was 6.3%. Surgical excision with micro scope guidance had significantly low recurrence rate (0.9%) compared to surgical excision with methylene blue dye and probe guidance (4.3%).

The recurrence and complication rates were not significantly affected by race, gender, sex, location of sinus, indication for surgery, history of previous sinus excision, presence of infection during surgery and duration of surgery.¹⁴Incidence of PAS in Nigerian population was 9.3% out of 600 patients in a survey. The age range was 1 to 45 years. The commonest age group was 18-30 years followed by 1-18 years. Males were more commonly affected with a male/female ratio of 1.3to1.0.

The left ear was mostly affected (57%), right ear (36%) and was bilateral in (7%). The sinus were claimed to have been noticed shortly after birth (86%), after 10 years (11%) and never noticed (4%). Presence in other family member in 25%, absent in 21% and never noticed in 54%. Sinus infections of 3-5 episodes in a year were observed in only 7% and no infection in 93%. Complaints of discharge were present in only 11%, hearing loss in only 4%. None had renal complaints. PAS repair was done in only 4 patients (7%).¹⁵

In the study by Hyo Geun Choi, conducted recently in Korea the incidence of unilateral PAS was 1.3% and that of bilateral PAS was 0.3%. Female gender was statistically associated with PAS (adjusted odd ratio, AOR=1.401). There was no statistical difference between right- and left-sided PAS. There was an association between parents and their children for bilateral PAS (AOR of father's bilateral PAS=35.711; AOR of mother's bilateral PAS=7.683), but there was no association found for unilateral PAS. There was no link found between hearing impairment and PAS. The incidence varies by geographic location: 0.1-0.9% in the United States, 1.6-2.5% in Taiwan, and up to 4-10% in some parts of Africa. Associated conditions include deafness and branchio-oto-renal syndrome.¹⁶

In their study Shim H S et al have under taken Early one-stage surgical treatment of infected PAS, with an even acute infection with abscess formation; 136 congenital PAS aged 0-15 years were classified according to the state of their infection at the time of the surgery intra-operatively—Group I (asymptomatic; n=68,50%), Group II (Infected state; n=26, 19%) and Group III (Infected state with abscess formation; n=42,31%). The follow-up period was from 6 months to over 2 years. All patients had no recurrence or significant chronic complications. But the authors have not specified the surgical technique adopted by them.¹⁷ Florian M. Lampert et al used a complete bilateral excision of PAS via a Modified face lift Incision and SMASH fixation.¹⁸

ORIGINAL ARTICLE

Georgia Alexandria Syropoulou et al in their presentation of Uncommon Presentation of PAS in Modern Plastic Surgery, 2012, 2, 61-63, present PAS with a post aural swelling below the left ear lobule; the post aural swelling recurred always after even 7 times excision of the PAS. The authors had to excise both the PAS and post aural swelling simultaneously to avoid recurrence.¹⁹ Bae S C et al in their study showed that a minimal supra-auricular approach with drain less surgical excision of PAS was useful to avoid compression post operatively. After removing the specimen, meticulous subcutaneous suturing and no drain were used.

There was no post operative recurrence or other serious complication.²⁰ Sampath S, Keats B J, Lacassie Y, in their study of "A newly recognized autosomal dominant disorder involving hypertelorism, pre auricular sinus, punctal pits, and deafness mapping to chromosome 14q31, described novel autosomal dominant disorder with variable phenotypic expression in a three-generation family; the major features include hypertelorism, preauricular sinus, deafness, and punctal pits with lacrimal-duct obstruction.

The identification of this family with a distinctive clinical phenotype and linkage to a novel locus at 14q31 supports the existence of a new syndrome of the branchial cleft.²¹ Yilmaz A E et al quoted in their study that the PAS may be bilateral, increasing the likelihood of being inherited, in 25-50% of cases. Pre auricular sinuses are features of other conditions or syndromes in 3-10% of cases, primarily in association with deafness and branchio-oto-renal (BOR) syndrome. When other congenital anomalies coexist with these sinuses, auditory testing and renal ultrasound should be considered.

A girl, who was three months and 20 days old, was presented because of the co-existence of a right infected pre auricular sinus, nephrolithiasis, infantile eczema and a nasal tooth.²² Bajwa H Showed comparing the use of radio frequency thermal ablation versus 'cold steel' excision, for supra-auricular excision of pre auricular sinus; as it allows better peri-operative visualization, easier dissection, minimal bleeding and a lower subsequent recurrence rate.

CONCLUSION: Pre auricular sinus is a congenital disease occurring due to developmental defect in auricular tubercles and 1st brachial arch. Bilateral disease has genetic predisposition of varying penetration. It is common in both sexes but with a slight preponderance to female sex. It is seen in all the social groups irrespective of economic or social status. Aural pits without discharging infected material, abscess formation can be left alone if the patient's age is the limitation for the parents decision to postpone the surgery, otherwise no age is bar for excision.

Simple sinectomy will result in recurrence. Microscopic magnification using a '6' magnification and extending the elliptical incision retroaurally around the superior root of the pinna and Lateral to medial dissection of the superficial fascia and tissue without following the sinus tract is the best treatment of choice. Recurrence rate is nil and infection rate is less than 0-9%. All the patients were isolated cases and not part of any syndrome.

REFERENCES:

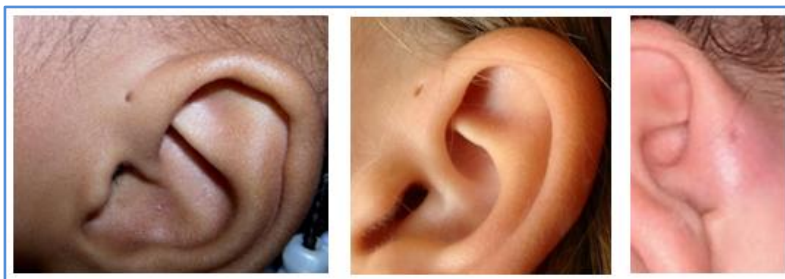
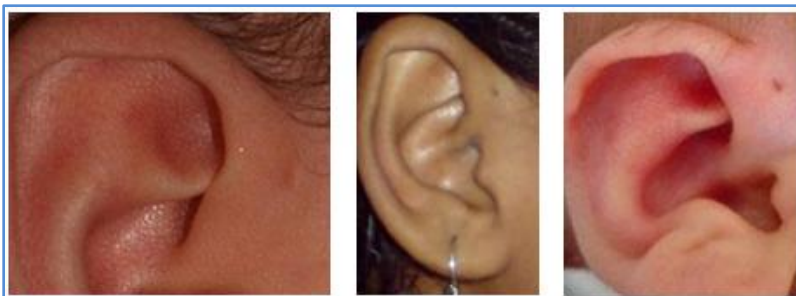
1. Chami Rabih G, Apesos James. Treatment of Asymptomatic Preauricular sinus: Challenging controversial wisdom. *Annals of Plastic Surgery* 23(5); 1989, 406-11.
2. Nofsinger YC, Tom LW, Lawrossa D, Wetmore RF, Handler SD. Preauricular Cysts and Sinuses. *Laryngoscope* 1997 Jul; 107(7): 883-7.

ORIGINAL ARTICLE

3. Tan T, Constantinides H, Mitchell TE. The Preauricular sinus: A review of its etiology, clinical features and management. *International Journal of Pediatric Otorhinolaryngology* 2005; 69:1469-74.
4. G Leopardi, G Chiarella, S Conti, E Cassandro. Surgical treatment of recurring preauricular sinus: supra-auricular approach. *Acta Otorhinolaryngology Ital.* Dec 2008; 28(6): 302–305.
5. Lam HCW, Soo G, Wormald PJ, Van Hasselt CA. Excision of the preauricular sinus: a comparison of two surgical techniques. *Laryngoscope* 2001; 111:317-9.
6. Currie AR, King WWK, Vlantis AC. Pitfalls in the management of preauricular sinuses. *Br J Surg* 1996; 83:1722-4.
7. Prasad S, Grundfast K, Milmore G. Management of congenital preauricular pit and sinus tract in children. *Laryngoscope* 1990; 100:320-1.
8. Yeo S, Jun B, Park S, Lee J, Song C, Chang K, et al. The preauricular sinus: factors contributing to recurrence after surgery. *American J Otolaryngol* 2006;27: 396-400.
9. Baatenburg de Jong R. A new surgical technique for treatment of preauricular sinus. *Surgery* 2005; 137:567-70.
10. Coatesworth AP, Patmore H, Jose J. Management of an infected preauricular sinus, using a lacrimal probe. *J Laryngol Otol* 2003;117:983-4.[PubMed]
11. Martín-Granizo R, Pérez-Herrero MC, Sánchez-Cuellar. A methylene blue staining and probing for fistula resection: application in a case of bilateral congenital preauricular fistulas. *Int J Oral Maxillofacial Surg* 2002;31: 439-41.[PubMed]
12. Tang IP, Shashinder S, Kuljit S, Gopala KG. Outcome of patients presenting with preauricular sinus in a tertiary centre– a five year experience. *Med J Malaysia* 2007; 62:53-5.
13. Rosslyn Anicete, Henry Kun Kiang Tan, Abhilash Balakrishnan. *Otolaryngol Head Neck Surg* August 2010, 143(2) suppl P1.
14. O R Jimoh, B S Alabi, S S Adebayo. Prevalence of PAS among Nigerians. *Medwell Journals- Surgery Journal*, 20083 (3)61-63.
15. Soo-Youn An, Hyo Geun Choi, Joong Seob Lee, Ji Hee Kim, Seung Woo Yoo, Bumjung Park. Analysis of incidence and genetic predisposition of preauricular sinus. *International Journal of Pediatric Otorhinolaryngology*. Published Online: October 25, 2014.
DOI: <http://dx.doi.org/10.1016/j.ijporl.2014.10.027>
16. Shim HS, Kim DJ, Kim MC, Lim JS, Han KT. *European Archives of Otolaryngology*. 2013; 270 (12): 3127-31.
17. Florian M Lampert et al. A novel approach for Complete Excision via a Modified Face Lift Incision. *Modern Plastic Surgery*, 2013,3,76-79.
18. Georgia Alexandria Syropoulou et al. Presentation of Uncommon Presentation of PAS. *Modern Plastic Surgery*, 2012,2,61-63.
19. Bae SC et al. Preauricular sinus: advantage of the drainless minimal supra-auricular approach. *American Journal of Otolaryngology*, 2012,33(4):427-31.
20. Sampath S, Keats BJ, Lacassie Y. A newly recognized autosomal dominant disorder involving hypertelorism, preauricular sinus, punctal pits, and deafness mapping to chromosome 14q31. *American Journal of Genetic A*:2011,155(A),976-85.
21. Yılmaz AE, Sarıfakıoğlu E, Aydemir S, Taş T, Orün E, Aydemir H. European Preauricular sinus, nephrolithiasis, infantine eczema and natal tooth: a new association. *Journal of Dermatology*; 2011Mar-Apr; 21(2): 234-7.

22. Bajwa H, Kumar S. Radiofrequency thermal ablation versus 'coldsteel' for supra-auricular excision of preauricular sinus: comparative study. 2010124(11):1190-3.

"Pre auricular sinus in different age"



AUTHORS:

1. S. Indira Devi
2. S. Muneeruddin Ahmed
3. T. Shankar
4. Manish Guptha
5. K. V. N. Durga Prasad

PARTICULARS OF CONTRIBUTORS:

1. Formerly Professor, Department of ENT, Osmania Medical College, Hyderabad.
2. Formerly Professor, Department of ENT, KMC, Kurnool.
3. Professor, Department of ENT, Osmania Medical College, Hyderabad.

4. Assistant Professor, Department of ENT, Osmania Medical College, Hyderabad.
5. Assistant Professor, Department of ENT, Osmania Medical College, Hyderabad.

NAME ADDRESS EMAIL ID OF THE CORRESPONDING AUTHOR:

Dr. S. Muneeruddin Ahmed,
44/118, Prakash Nagar,
Kurnool-518004,
Andhra Pradesh.
Email: ahmedmunirent@gmail.com

Date of Submission: 05/11/2014.
Date of Peer Review: 06/11/2014.
Date of Acceptance: 12/11/2014.
Date of Publishing: 15/11/2014.