RARE PRESENTATION OF A CASE OF LITTRE'S HERNIA – A CASE REPORT

Bikramjit Pal[1], Sumit Kumar Gupta[2]

HOW TO CITE THIS ARTICLE:
Bikramjit Pal, Sumit Kumar Gupta. "Rare presentation of a case of Littre's hernia – a case report". Journal of Evolution of Medical and Dental Sciences 2013; Vol2, Issue 31, August 5; Page: 5891-5894.

ABSTRACT: Littre's Hernia is an abnormal protrusion of Meckel's Diverticulum through an abdominal opening. Alexis Littre first described the condition in relation to a femoral hernia in 1770 (1). It is a very rare condition and very few cases are reported till date. Meckel's diverticulum is the most common congenital abnormality of the gastrointestinal tract. It is a true diverticulum found in the anti-mesentric border. It is the remnant of the persistent intestinal part of the vitello-intestinal or omphalo-enteric duct and comprises of all intestinal layers (2, 3, 4). It is found in 2% of total population, 2 feet from ileo-caecal junction and 2 inches in length, 2 types of common ectopic tissue (gastric and pancreatic). Meckel's diverticulum may be accompanied in the sac by the ileal loop to which it is attached; rarely, it may undergo incarceration or strangulation, necrosis, and perforation. In children, it is mostly found in umbilical hernias in which case it is more prone to adhere to the sac. Intestinal obstruction may occur due to volvulus, intussusception or very rarely as a complication of Littre's hernia (2, 3, 5). Its diagnosis is usually difficult despite the availability of modern investigative tools. A high index of suspicion is mandatory. In most cases it is an incidental finding. Hernial obstruction and strangulation of Meckel's diverticulum (Littre's Hernia) is a rare phenomenon and representing 10% of all complications of Meckel's diverticulum (6, 7). Surgery is the mainstay of treatment. We herein present an extremely rare case of strangulated Meckel's diverticulum in a Ventral Hernia (Littre's Hernia) which only became evident during surgery. The ventral hernia developed following emergency appendicectomy operation done for acute appendicitis 5 months back.

KEY WORDS: Littre's Hernia; Meckel's Diverticulum; Strangulated Ventral Hernia.

CASE REPORT: A 47 years old male patient was admitted through Emergency with complaints of diffuse abdominal pain with distension, intermittent vomiting, dyspepsia and anorexia for last 2 days. There was no history of loose motion, fever or bleeding per rectum. The patient had undergone emergency appendicectomy five months back.

On clinical examination, tachycardia (110 / minute) was noted, blood pressure was 146/90 mm. of Hg and slightly dehydrated; a very tender irreducible lump was found at the region of scar (right lower paramedian incision) of previous appendicectomy operation; absent peristaltic sounds. The cough impulse was absent. Examination of other systems was unremarkable.

Straight X-ray abdomen showed multiple distended bowel loops with fluid levels; Ultrasound scan suggested an obstructed loop of intestine at the hernia site.

The diagnosis of strangulated ventral hernia was made and emergency surgery was planned after resuscitation with IV fluids and antibiotics.

Abdomen was opened through the scar of the previous appendicectomy operation; careful and meticulous dissection revealed the hernia sac which was opened; foul smelling dirty fluid was mopped up and the constricting ring-like formation in the anterior sheath was cut. The sac contained the inflamed Meckel's diverticulum with a part (about 5 cm) of ileum. The whole of

Meckel's diverticulum with the strangulated part of ileum was resected and end to end anastomosis was performed in 2 layers. Thorough peritoneal toileting was done with normal saline. Anatomical repair and double breasting of the sheath with polypropylene was done for the ventral hernia. The post-operative period was uneventful and the patient was discharged after 6 days.

DISCUSSION: Alex Littre, a French surgeon, was the first to report in 1700 three cases of obstructed femoral hernia containing a diverticulum of the small intestine. Meckel's diverticulum was first reported by Fabricius Hildanus in 1809 and Johann Friedrich Meckel described it in detail in 1812 and suggested its congenital origin (6, 9, 10). Since then the hernia sacs containing only Meckel's diverticula are termed as Littre's hernia. Although Littre's original report related to femoral hernias, 50% of the Meckel's diverticula are in inguinal hernias, 20% in femoral, 20% in umbilical and remaining 10% in other miscellaneous hernias (6, 7, 8). In our case, it was present in ventral hernia developed following appendicectomy operation. Lower right paramedian incision was made for the said operation, presumably for better approach by the surgeon but searching for Meckel's diverticulum as a routine procedure during appendicectomy might have been omitted.

The diagnosis of a strangulated Littre's Hernia is unlikely to be made preoperatively as the presenting signs and symptoms are more subtle and evolve more slowly than those of strangulated small intestine (6, 7, 9). A high index of suspicion is needed to diagnose it correctly. The symptoms and signs of intestinal obstruction occur late. Obstruction can occur if the base of the diverticulum is broad enough to cause narrowing of the intestinal lumen. A tender mass at the hernia site with nausea, vomiting and abdominal pain being the main symptoms. The swelling over the hernia site may be small at first, and may be missed as the cause of symptoms. Peritonitis is rare.

Surgery is the mainstay of treatment (6, 9). The diverticulum is locally excised and small intestine sutured transversely. If the base of diverticulum is wide or the intestine appears non-viable, resection of the involved loop of ileum with end to end anastomosis may be required (6) which was done in our case followed by repair of the hernia.

"Meckel's is a great mimic that must be considered in all cases of intra abdominal disease in which the cause is not readily apparent" (10, 11). Most of them are silent which are incidentally (9) discovered during autopsy, exploratory laparotomy and barium meal studies. The treatment of incidental discovery of Meckel's diverticulum is controversial (12). In some cases, it may present with symptoms and signs of acute appendicitis and so it is prudent to check distal ileum for Meckel's diverticulum and if it is found, it should be removed with appendix.

REFERENCES:

1. Bennett DH: Hernias, Umbilicus and Abdominal wall; Bailey and Love's Short Practice of Surgery; 24th Ed. Arnold London;2004
2. Evers BM: Small Intestine; Sabiston Textbook of Surgery; 17th Ed. Saunders 2004
3. Michael NM: Diverticular disease of the small bowel; Oxford Textbook of Surgery; OUP 1994
4. Whang EE: Small Intestine; Schwartz's Principles of Surgery; 8th Ed. McGraw Hill; 2005
5. Mutch MG: Small Intestine; The Washington Manual of Surgery; 3rd Ed. Lippincott Williams & Wilkins; 2002
6. Trupo FJ et al: A Meckel's diverticulum in a femoral hernia: a Littre's hernia; South Med J; 1987

7. Pearlman JA et al: Femoral hernia with strangulated Meckel's diverticulum; Am J Surg; 1980
8. Andrew DR et al: Meckel's diverticulum – rare complications and review of literature; JR Army Med Corps; 1994
9. Fa-Si-Oen PR et al: Complications and management of Meckel's diverticulum – A review; Euro J Surg; 1999
10. Brown CK et al: Meckel's diveticulum; Am J Emerg Med; 1998
11. Martin JP et al: Meckel's diverticulum; J Am Fam Physician; 2000
12. Pinerotte et al: Surgical management and complications of Meckel's diverticulum in 90 patients; Euro J Surg 168; 2002.



Meckel's Divericulum after dissecting out from Littre's Hernia sac.

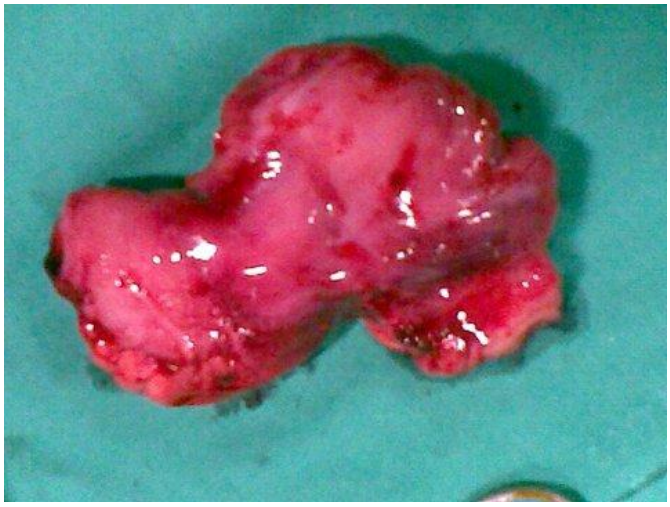

The resected specimen of Meckel's diverticulum.



Littre's Hernia sac containing Meckel's Diverticulum.



Per-operative photograph showing Meckel's Diverticulum just before resection.

AUTHORS:

1. Bikramjit Pal
2. Sumit Kumar Gupta

PARTICULARS OF CONTRIBUTORS:

1. Assistant Professor, Department of Surgery, KPC Medical College & Hospital, Kolkata.
2. Assistant Professor, Department of Surgery, KPC Medical College & Hospital, Kolkata.

NAME ADRRESS EMAIL ID OF THE CORRESPONDING AUTHOR:

Dr. Bikramjit Pal,
Hiland Park, Apt. No. 15A2, Peak Tower,
E.M. Bypass, Kolkata 700094.
Email- bikramjit_paul@yahoo.co.in

Date of Submission: 24/06/2013.
Date of Peer Review: 25/07/2013.
Date of Acceptance: 27/07/2013.
Date of Publishing: 01/08/2013