DOI: 10.14260/jemds/2015/2037

ORIGINAL ARTICLE

THYROID NEOPLASMS AND PERITUMORAL MORPHOLOGY IN THYROIDECTOMY SPECIMENS

Padmavathi M[1], Jyothi A. Raj[2]

HOW TO CITE THIS ARTICLE:
Padmavathi M, Jyothi A. Raj. "Thyroid Neoplasms and Peritumoral Morphology in Thyroidectomy Specimens". Journal of Evolution of Medical and Dental Sciences 2015; Vol. 4, Issue 82, October 12; Page: 14320-14328, DOI: 10.14260/jemds/2015/2037

ABSTRACT: Thyroid neoplasms represent the most common malignancies of the endocrine system. They are known to occur in association with benign lesions of the thyroid, like multinodular goitre and Hashimoto thyroiditis. **AIMS AND OBJECTIVES:** To study the neoplasms of thyroid and their peritumoral morphology. **MATERIALS AND METHODS:** All thyroidectomy specimens received in the Department of Pathology, RRMCH over a period of three years from June 2011 to May 2014 were included in the study. Thyroidectomies for non-neoplastic lesions were also extensively sampled and morphologically studied, with focus on peritumoral morphology, in neoplasms. **RESULTS:** Of the one hundred and fifty four thyroidectomy specimens received over three years, one hundred and thirteen (73.4%) were non- neoplastic, and forty one were neoplastic (26.6%). Colloid goitre and lymphocytic infiltrate were the most common features in the peritumoral thyroid tissue, followed by multinodular goitre. Hashimoto thyroiditis and Hurthle cell change were noted in 11.5% of cases. Tumors were multicentric in 11.5% of cases. Malignancy was detected in eight of the fifty nine thyroidectomies performed for multinodular goitre. Of the thirty four surgeries for Hashimoto thyroiditis, four were reported as malignant on histopathology. **CONCLUSION:** All thyroidectomies, including those operated for benign lesions, need to be extensively sampled and morphology studied due to the possibility of occult malignancy. Larger series need to be studied to find a causal association between the two.

KEYWORDS: Thyroidectomies, Morphology, Non- neoplastic, Neoplastic.

INTRODUCTION: Most thyroid lesions present as solitary or multiple nodules. Their differential diagnoses range from the non- neoplastic nodular goitres to the benign and malignant neoplasms. Thyroid cancers represent the most common malignancies of the endocrine system, accounting for approximately 1% of all malignancies.[1] They occur primarily in young and middle aged. These neoplasms can be primary or secondary: follicular- derived primary epithelial tumors are common. Of these, papillary carcinomas account for nearly 85% of primary thyroid malignancies.[2]

Benign lesions like multinodular goitre and Hashimoto thyroiditis are commonly associated with thyroid neoplasms. The incidence of carcinoma in multinodular goitre has been found to vary from 4% to 17%. Papillary carcinomas are commonly associated with multinodular goitre, chronic thyroiditis, and Graves' disease.[2]

MATERIALS AND METHODS: All thyroidectomies received in the Department of Pathology, RRMCH during a period of three years from June 2011 to May 2014 were included in the study. These specimens, including those operated for non-neoplastic lesions, were extensively sampled and their microscopy studied, with focus on peritumoral morphology, in neoplasms.

DOI: 10.14260/jemds/2015/2037

RESULTS: Of the one hundred and fifty four thyroidectomy specimens received over a period of three years (From June 2011 to May 2014), one hundred and thirteen were non- neoplastic (n=113, 73.4%), and forty one were neoplastic (n= 41, 26.6%) (Figure 1). Among the neoplastic lesions, seven cases (n=7, 17.1%) were benign and thirty four cases (n=34, 82.9%) were malignant.

All benign neoplasms were follicular adenomas (n=7, 17.1%), which showed an age predominance in the second to fourth decades of life (Figures 2, 3 & 4).

Twenty six cases of papillary carcinoma (63.4%), five cases (12.1%) of follicular neoplasms of undetermined significance, and three (7.3%) cases of follicular carcinoma were reported. Papillary carcinomas were the most common malignancies, with most cases (n=10) reported between 21 to 30 years. Follicular carcinomas showed an equivocal age distribution.

Of the forty one neoplasms, twelve were pre- operatively diagnosed as non- neoplastic; following surgery and histopathological examination, these turned out to be neoplasms (Figures 5, 6 & 7).

Neoplasms were detected in eight of the fifty nine thyroidectomies performed for multinodular goitre. These included five cases of papillary carcinoma, one case each of follicular carcinoma, follicular carcinoma of undermined significance, and follicular adenoma (Figures 8A & 9).

Of the thirty four surgeries performed for Hashimoto thyroiditis, four cases were reported as neoplastic on histopathology. The most common neoplasm was papillary carcinoma (n=2) followed by one each of follicular carcinoma and follicular adenoma (Figure 8B).

Following extensive histopathological evaluation of the resected specimens, various morphologic patterns were noted in the thyroid tissue surrounding tumors. Of the 41 neoplasms reported, lymphocytic infiltrate (23.3%) and colloid goiture (23%) were the most common features in the surrounding thyroid tissue, followed by multinodular goitre (19.2%). Hashimoto thyroiditis and Hurthle cell change were noted in 11.5% of cases. Tumors were multicentric in 11.5% of cases (Figure 10).

DISCUSSION: The thyroid gland develops from an evagination of the developing pharyngeal epithelium that descends as part of the thyroglossal duct from foramen caecum at the base of the tongue to its normal position in the anterior neck.[3]

The functional units of the thyroid gland are the follicles, which are lined of a single layer of cuboidal epithelial cells bound by a basement membrane. It is divided by thin fibrous septae into lobules composed of twenty to forty evenly dispersed follicles filled with thyroglobulin, the storage form of thyroxine (T4) and tri-iodothyronine (T3).[4]

Thyroid gland is affected by a variety of pathologic lesions including conditions associated with excessive release of thyroid hormones (hyperthyroidism), those associated with thyroid hormone deficiency (hypothyroidism), and mass lesions of thyroid.[5,6]

Thyroid diseases are major health problems both in developed and developing countries. They are more common in hilly terrain and away from the seacoast. 5-10% of them are malignant.[7] Iodine deficiency is a predisposing factor for goitre, while radiation exposure to the neck is a risk factor for papillary carcinoma.[8]

Thyroid nodules are seen in 4-7% of population.[9] They are four times more frequent in females. Their prevalence increases with age due to iodine deficiency and exposure to radiation; they are more common in the third, fourth and fifth decades of life.[10]

DOI: 10.14260/jemds/2015/2037

Benign tumors are common. Although cancers are relatively rare, they represent the most common malignancies of the endocrine system. Among epithelial tumors, carcinomas of follicular cell origin are more numerous than those of C- cell origin. Most carcinomas of follicular cell origin are indolent malignancies, with 10- year survivals exceeding 90%.[11] From a clinical standpoint, the possibility of neoplastic disease is of major concern in patients who present with thyroid nodules.

Thyroid cancer occurs primarily in young and middle aged adults and is rare in children. It is two to four times more frequent in females than in males, but this sex difference is far less pronounced in children and older adults. This observation suggests that a specific susceptibility gene with sex hormone receptor elements may be involved in the pathogenesis of thyroid carcinomas.[1]

Follicular carcinoma is linked to dietary iodine deficiency, and with genetic influences could account for its link with a history of nodular goitre. Papillary carcinoma shows a significant association with lymphocytic thyroiditis, probably as a result of carcinoma provoking an autoimmune response and also as a possible pathogenetic mechanism.[1]

The biologic basis for separating nodules from adenomas is dependent on their clonality and up to 60% of lesions in multinodular goitre have been shown to be monoclonal.[1]

Minimally invasive follicular carcinomas can be indistinguishable from adenomas and adenomatous goitres, for lack of evidence of definitive invasion. Such tumors may be called 'follicular tumors of uncertain malignant potential' after adequate sampling.[1]

In a study done by Ahmed Z et al.,[5] out of 100 cases of thyroid lesions 69 cases were non-neoplastic and 31 cases were neoplastic. Among the neoplastic lesions, follicular adenoma was the most common benign neoplasm (22 cases) and papillary carcinoma was the most common malignant neoplasm (6 cases). Incidence of thyroid lesions was found to be high between the 3rd and 6th decades, with a peak during 4th decade.

Pradeep Kumar NS et al.,[7] studied a total of 342 thyroidectomy specimens over a period of nine years, of which 312[91.23%] were females and 30[8.77%] were males. Of the 342 cases, ninety eight [28.66%] cases were adenomas. Malignancy was observed in 75[21.93%] cases, of which seventy were classified as papillary carcinoma, while the other five were classified as follicular carcinoma.

Darwish AH et al.,[9] studied 110 thyroidectomy specimens, with seventeen cases (15.5%) of follicular adenoma and twenty six cases (24%) of thyroid malignancy.

In a study done by Praveen Kumar et al.,[12] of the one hundred and eighty two surgeries performed for benign multinodular goitre, fifteen had malignancy. The most common was papillary carcinoma of thyroid (10 cases), followed by follicular carcinoma (3 cases). Micropapillary carcinoma smaller than 1cm, was detected in 2 patients.

Campos LAAF, et al.,[13] studied three hundred and fifteen thyroidectomies, of which forty one were papillary carcinomas and forty five were nodular goitres. Of the remaining two hundred twenty nine cases, chronic thyroiditis was reported in 12.25% cases. Eleven of the forty one cases of papillary carcinoma also showed concurrent Hashimoto thyroiditis (26.8%).

In our study, of the fifty nine thyroidectomies performed for multinodular goitre, malignancy was detected in eight of them on histopathology. The most common malignancy was papillary carcinoma (n=5) followed by one case each of follicular carcinoma, follicular carcinoma of undermined significance, and follicular adenoma.

Thirty four (n= 34) surgeries were performed for Hashimoto thyroiditis: four of them (n=4, 11.7%), were malignant on histopathology. Papillary carcinoma was reported in two, followed by one each of follicular carcinoma and follicular adenoma.

Papillary carcinoma comprises approximately 80-85% of malignant epithelial tumours of the thyroid, in geographic regions where sufficient iodine is present in diet.

Scattered lymphocytic infiltrates are often seen at the periphery of thyroid neoplasms. It is believed to result from local antigenic perturbation to altered antigen on the tumour cells.[11]

Recently two independent studies have shown high prevalence of RET/PTC in benign thyroid tissue affected by Hashimoto thyroiditis. It has been suggested that immunohistochemical detection of RET/PTC can be helpful in early diagnosis of papillary thyroid carcinomas.[2]

Activating RAS mutations occur in a few hyperplastic nodules. Observations such as monoclonal origin of some hyperplastic nodules, occurrence of cytogenetic abnormalities, aneuploidy and oncogenic mutations indicates that hyperplastic nodules over a long time may become neoplastic.[8]

CONCLUSION: Papillary carcinoma is the most common malignancy reported as frequently associated with multinodular goitre as with Hashimoto thyroiditis.

Peritumoral thyroid tissue shows a spectrum of morphological changes, including multinodular goitre, Hashimoto thyroiditis and Hurthle cell change.

All thyroidectomies, including those operated for benign lesions, need to be extensively sampled and morphologically studied due to the risk of occult malignancy.

Further, larger series need to be studied to find a causal association between the two.

REFERENCES:

1. DeLellis RA, Williams ED. Thyroid and Parathyroid Tumours. Chapter 2. In: World Health Organisation Classification of Tumours, Pathology and Genetics, Tumours of Endocrine Organs. DeLellis RA, Lloyd RV, Heitz PU, Eng C. Eds. IARC Press: Lyon; 2004: 49-52.
2. Zubair WB, Virginia AL. The thyroid gland. Chapter 42. In: Silverberg's principles and practice of Surgical Pathology and Cytopathology; Vol 2, 4th ed. Silverberg SG, DeLellis RA, Frable WJ, Livolsi VA, Wick MR. Eds. Churchill Livingstone, Elsevier: Philadelphia; 2006:2127-2132.
3. Maitra A. The Endocrine System. Chapter 24.In:Robbins and Cotran Pathologic Basis of Disease, 7th ed. Vinay Kumar, Abbas A, Fausto N, Aster J. Eds. Saunders Elsevier: Philadelphia; 2011:164-65.
4. Young B, Lowe JS. The Endocrine Gland. Chapter 17. In: Wheater's Functional Histology; 5th ed. Young B, Lowe JS, Stevens A, Heath JW, Eds. Elsevier: Philadelphia; 2006:333.
5. Ahmed Z, Chaudary R, Umaru N. Study of Prevalence of Thyroid Lesions in Coastal Region of Karnataka. Journal of Evolution of Medical and Dental Sciences 2013; 2(36): 6995-702.
6. Salama SI, Abdulla LS, Al-Qahtani MH, Al-Maghrabil JA. Histopathological Pattern of Thyroid Lesions in Western region of Saudi Arabia. The New Eygptian Journal of Medicine 2009; 40(6): 580-85.
7. Pradeepkumar NS, Singh R, Joseph NM. Emerging Trends in Thyroid Diseases in Tsunami hit coastal areas of Puducherry and Cuddallore, India. Journal of Evolution of Medical and Dental Sciences 2012; 1(5):857-63.

8. Rosai J. Thyroid Gland. Chapter 9. In: Rosai and Ackerman's Surgical Pathology, vol 1, 9th ed. Juan Rosai. Elsevier: Missouri; 2005:515-568.
9. Darwish AH, Al Sindi KA, Kafsi JE. Pattern of Thyroid Diseases-A Histopathological Study. Bahrain Medical Bulletin 2006; 28(4):1-6.
10. Hussian N, Anwar M, Nadia N, Ali Z. Patterns of Surgically Treated Thyroid Diseases in Karachi. Biomedica 2005; 21:18-20.
11. Baloch ZW, Livolsi VA. Pathology of thyroid and parathyroid disease, chapter 13. In: Sternberg's Diagnostic Surgical Pathology, vol 1,4th ed. Mills SE, Carter D, Greenson JK, Oberman HA, Victor R, Stoler MH, Eds. Lippincott Williams and Wilkins: Philadelphia; 2004: 562-569
12. Praveen Kumar K, D'Souza C. The incidence of thyroid carcinoma in multinodular goitre: retrospective analysis in a Medical College Hospital. International Journal of Biomedical Research 2014; 05 (02): 90-91. ISSN: 0976-9633 (Online) Journal DOI: 10.7439 /ijbr CODEN: IJBRFA. www.ssjournals.com
13. Campos LAAF, Picado SM, Guimarães AV, Ribeiro DA, Dedivitis RA. Thyroid papillary carcinoma associated to Hashimoto's thyroiditis. Braz J Otorhinolaryngol [Internet] 2012 Dec [cited 2015 Sep 08]; 78(6): 77-80. Available from: http://www.scielo.br/scielo.php?script=sci_arttext&pid=S1808-86942012000600013&lng=en. http://dx.doi.org/10.5935/1808-8694.20120037.

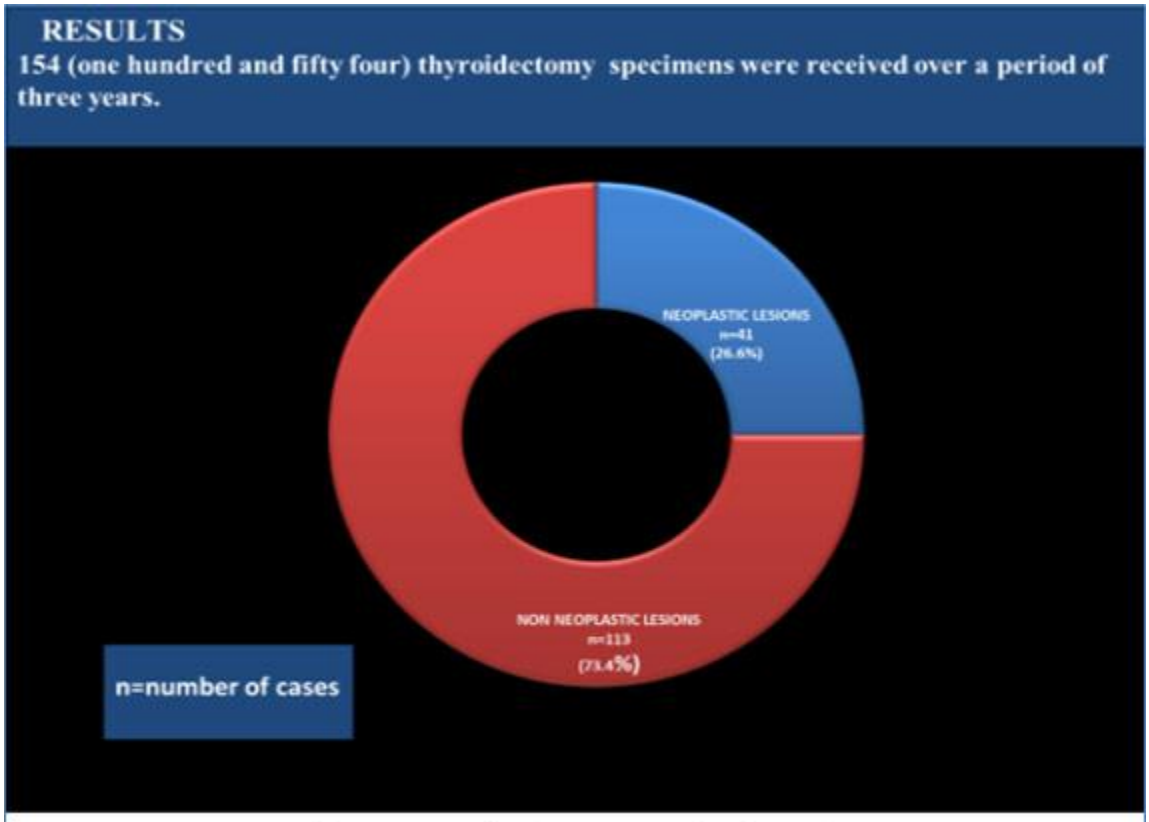

Figure 1: Ratio of non- neoplastic and neoplastic lesions (113:41) in the thyroid

DOI: 10.14260/jemds/2015/2037

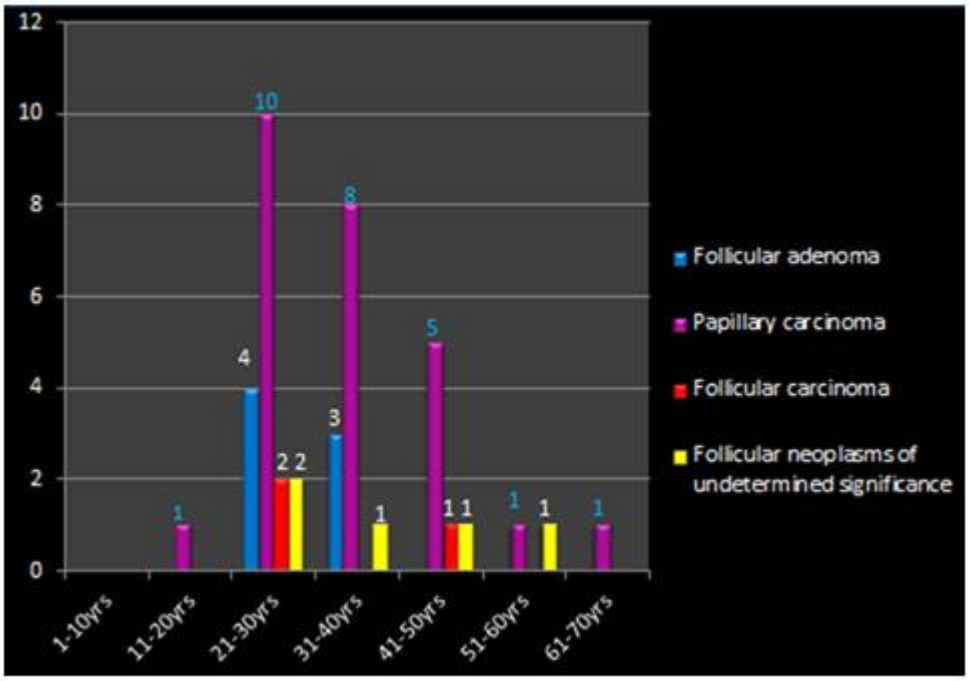

Figure 2: Age incidence of thyroid neoplasms



Fig. 3: Follicular adenoma: cut surface of a lobe of thyroid showing a well circumscribed grey white nodule

DOI: 10.14260/jemds/2015/2037

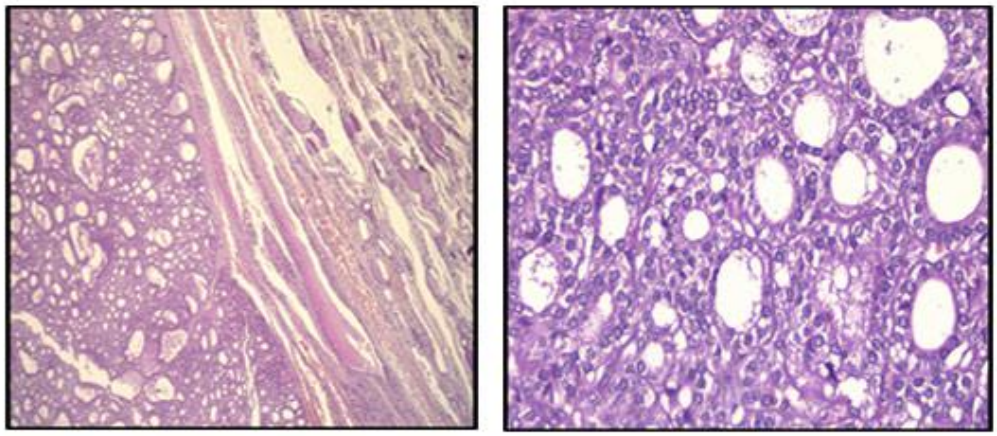

Figure 4A, B: Follicular adenoma, thyroid: Photomicrographs of an encapsulated tumor showing evidence of follicular cell differentiation (H&E; A- 10x, B- 20x)

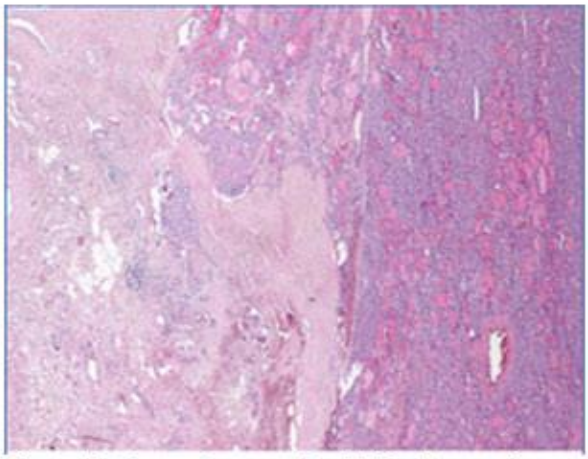

Figure 5: photomicrograph of follicular carcinoma of thyroid showing capsular invasion (H&E, 20x)

Fig. 6A,B,C: Papillary carcinoma, thyroid: cut surface showing solid and cystic areas

DOI: 10.14260/jemds/2015/2037

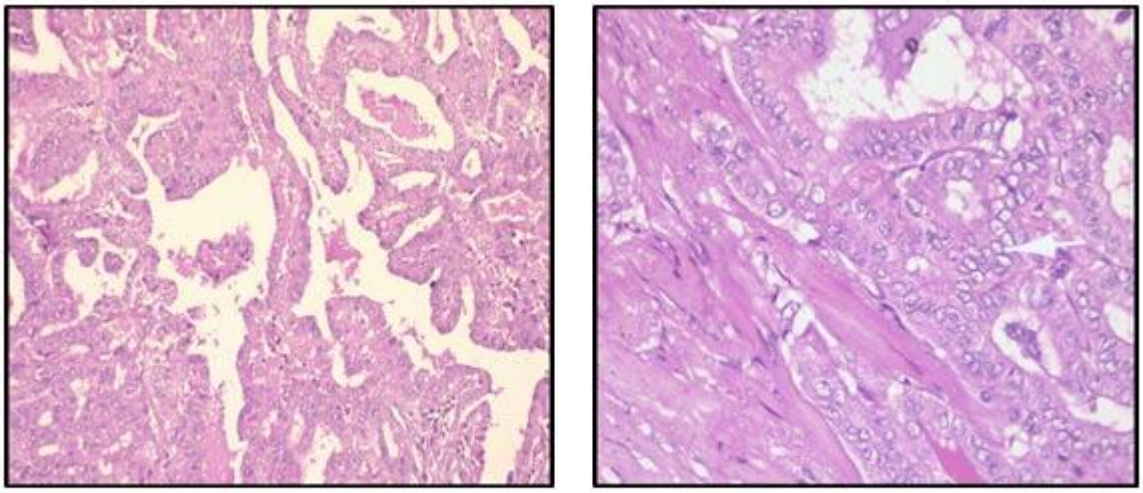

Figure 7: Papillary carcinoma, thyroid

Fig 7A: photomicrograph showing papillary fronds with delicate fibrovascular cores (H&E,10x)

Fig 7B: photomicrograph showing overlapping, optically clear nuclei (H&E, 10x)

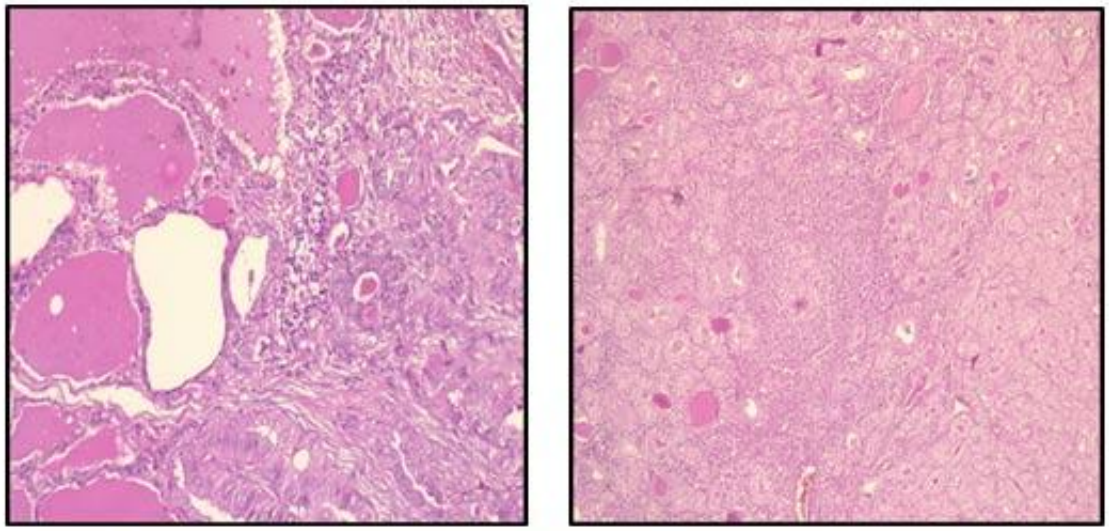

Figure 8: photomicrographs of papillary carcinoma, thyroid, with associated multinodular goiter in A (H&E, 20x) and Hashimoto thyroiditis in B (H&E, 10x)

DOI: 10.14260/jemds/2015/2037

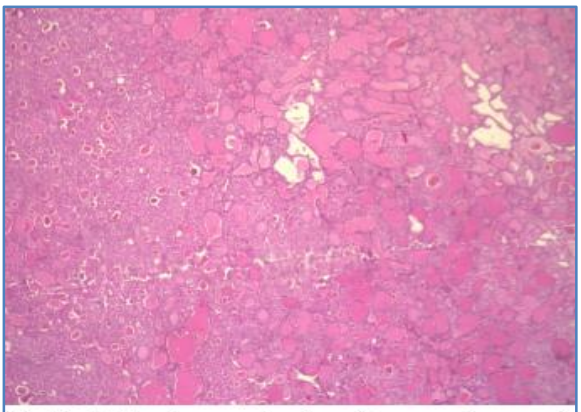

Fig. 9: photomicrograph of papillary carcinoma of thyroid associated with multinodular goitre and Hurthle cell nodule (H&E, 20x)

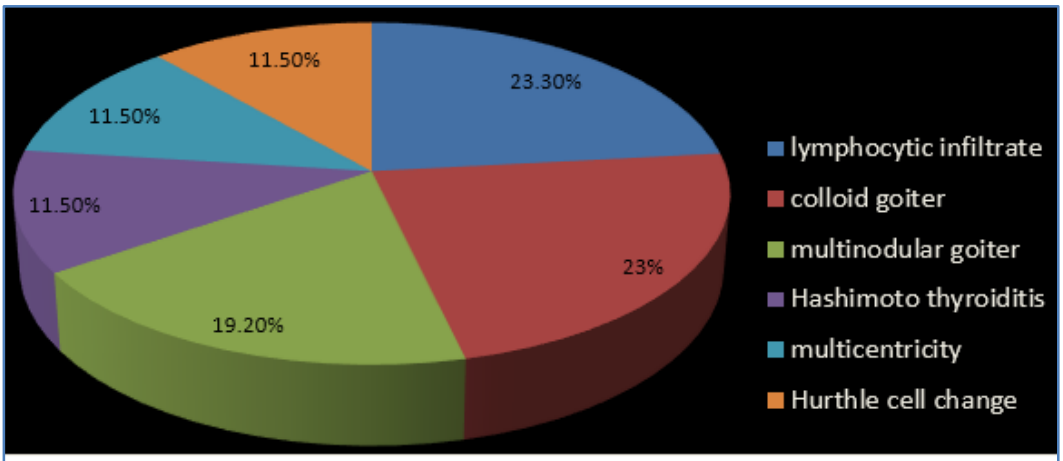

Fig. 10: Peritumoral morphology in thyroid neoplasms

AUTHORS:

1. Padmavathi M.
2. Jyothi A. Raj

PARTICULARS OF CONTRIBUTORS:

1. Post Graduate, Department of Pathology, Rajarajeswari Medical College and Hospital, Bangalore.
2. Professor, Department of Pathology, Rajarajeswari Medical College and Hospital, Bangalore.

FINANCIAL OR OTHER COMPETING INTERESTS: None

NAME ADDRESS EMAIL ID OF THE CORRESPONDING AUTHOR:
Dr. Jyothi A. Raj,
Professor,
Department of Pathology,
Rajarajeswari Medical College and Hospital,
Mysore Road, Bangalore.
E-mail: jyoki255@yahoo.co.in

Date of Submission: 17/09/2015.
Date of Peer Review: 18/09/2015.
Date of Acceptance: 01/10/2015.
Date of Publishing: 09/10/2015.