

**STUDY OF DISTRIBUTION OF SUBSCAPULAR ARTERY BRANCHES IN MALES AND FEMALES**

Sreenivasulu. Kanaka<sup>1</sup>, E. Ravi Theja<sup>2</sup>, P. Moula Akbar Basha<sup>3</sup>, R. Somasekhar<sup>4</sup>, G. Kanchanalatha<sup>5</sup>, K. S. Haniman<sup>6</sup>

**HOW TO CITE THIS ARTICLE:**

Sreenivasulu. Kanaka, E. Ravi Theja, P. Moula Akbar Basha, R. Somasekhar, G. Kanchanalatha, K. S. Haniman. "Study of Distribution of Subscapular Artery Branches in Males and Females". Journal of Evolution of Medical and Dental Sciences 2015; Vol. 4, Issue 56, July 13; Page: 9764-9769, DOI: 10.14260/jemds/2015/1409

**ABSTRACT: INTRODUCTION:** the subscapular arterial tree may be used as a source of microvascular grafts to replace damaged or diseased portions of arteries, particularly in the hand and forearm. The use of muscle patches, myocutaneous, osteomuscular and even muscle fascia in reconstructive surgery of the head, neck and limbs is becoming increasingly frequent. The muscles of the scapular and axillary regions, mainly the serratus anterior and the latissimus dorsi, are among those most commonly used in reparative surgery. The current importance of knowledge of blood supply to the muscles of the scapular region and the controversies that persist in the literature were the reasons for our study of the subscapular artery focusing on new objectives which has not yet been dealt with thoroughly in the existing literature. **AIMS AND OBJECTIVES:** The motive for this research was the use of the muscles of the scapular region in transposition, transplantation and reparative surgery and the need for more detailed knowledge of the blood supply to these muscles. The development of reparative surgery has demanded more detailed anatomical knowledge of the blood supply and innervation of muscles in general and of those with more significant surgical application in particular. Anatomy textbooks do not describe these structures with the necessary depth, either because they were designed at a time when this type of surgery was only in its early stages, or because descriptions of the structures mentioned above were not their main objective. It is our sincere hope that this study proves useful for surgeons specializing in reparative surgery. **MATERIALS AND METHODS:** We have studied the axillary artery and its branches in 30 cadavers, of both sexes, aged 26 to 70 years, through routine dissection on the axillary regions on both sides. **RESULTS:** Our research showed collateral branches to the following muscles: serratus anterior (54% in males, 30 % in females), teres major (26% in males, 40% in females) and sub scapularis (20% in males and 30 % in females). Terminal branches to the following muscles: serratus anterior (50% in males, 64 % in females), latissimus dorsi (50% in males and 26% in females). In males serratus anterior muscle receiving two branches at 2<sup>nd</sup> (collateral branch) and 5<sup>th</sup> (Terminalbranch) inter coastal spaces where as in females serratus anterior muscle receiving two branches (both are terminal) at 5<sup>th</sup> inter coastal spaces. **CONCLUSIONS:** the site of termination into muscular branches to serratus anterior and latissimus dorsi is higher in males when compared to females. No of collateral branches (Three) more in females when compared to males. In this study the serratus anterior receives two branches (one collateral and one terminal) in males whereas females also present two branches but both of them are terminal.

**KEYWORDS:** Sub scapular artery, Collateral branches, Terminal branches.

**INTRODUCTION:** The motive for this research was the use of the muscles of the scapular region in transposition, transplantation and reparative surgery and the need for more detailed knowledge of the blood supply to these muscles. In addition, the subscapular arterial tree may be used as a source

## ORIGINAL ARTICLE

---

of microvascular grafts to replace damaged or diseased portions of arteries, particularly in the hand and forearm.

The use of muscle patches, myocutaneous, osteomuscular and even muscle fascia in reconstructive surgery of the head, neck and limbs is becoming increasingly frequent. The, the subscapular arterial tree may also be used as a source of microvascular grafts to replace damaged or diseased portions of arteries, particularly in the hand and forearm.<sup>1,2,3</sup> The development of reparative surgery has demanded more detailed anatomical knowledge of the blood supply and innervation of muscles in general and of those with more significant surgical application in particular. Anatomy textbooks do not describe these structures with the necessary depth, either because they were designed at a time when this type of surgery was only in its early stages, or because descriptions of the structures mentioned above were not their main objective.

The muscles of the scapular and axillary regions, mainly the serratus anterior and the latissimus dorsi, are among those most commonly used in reparative surgery.<sup>4,5,6,7</sup> Despite the importance of the applications, the books that referred to in the research revealed much uncertainty concerning the blood supply to these muscles. Van Thienen mentions the angular artery, while Fontaine et al. reaffirm the anatomical variations of the arteries mentioned above and add their description of a case of blood supply of the serratus anterior by the first intercostal artery.<sup>8</sup> The current importance of knowledge of blood supply to the muscles of the scapular region and the controversies that persist in the literature were the reasons for our study of the subscapular artery focusing on new objectives which has not yet been dealt with thoroughly in the existing literature. It is our sincere hope that this study proves useful for surgeons specializing in reparative surgery.

**MATERIAL AND METHODS:** Thirty adult corpses, of both sexes, aged 26 to 78 and preserved in formalin 10% formed the subject of the study. The dissections were performed on the axillary regions on both sides, 60 axillary arteries in all. The subscapular artery was carefully dissected, accompanying its collateral branches as far as the thinnest. We have studied the variations in distribution of its branches in males and females and site of termination into branches to serratus anterior muscle and latissimus dorsi muscle.

**RESULTS:** The subscapular artery was present in 96.7% of cases as the right branch of the axillary artery. Where it was absent (3.3%), the circumflex scapular artery and the thoracodorsal artery originated directly from the axillary artery. Our study mainly focused about the number, distribution of collateral and terminal branches in males and females. We have also studied the site of termination in males and females. We have also studied the number of branches in relation to muscles. The site of termination into muscular branches to serratus anterior and latissimus dorsi is higher in males when compared to females (Table 3, Fig. 1 & 2). No of collateral branches (Three) more in females when compared to males (Fig. 1 & 2, Table1). In males serratus anterior muscle receiving two branches at 2<sup>nd</sup> (Collateral branch) and 5<sup>th</sup> (Terminalbranch) inter coastal spaces where as in females serratus anterior muscle receiving two branches (Both are terminal) at 5<sup>th</sup> inter coastal spaces (Fig. 1 & 2).

## ORIGINAL ARTICLE

	<b>Distribution of collateral branches in males</b>	<b>Distribution of collateral branches in females</b>
Serratus anterior	54%	30%
Teres major	26%	40%
subscapularis	20%	30%
	No=3	No=2-3

**Table 1: Comparative study of no and distribution of collateral branches in males and females**

	<b>Distribution of terminal branches in males</b>	<b>Distribution of terminal branches in females</b>
Serratus anterior	50%	64%
Lattissimus dorsi	50%	26%
	No=2	No=3

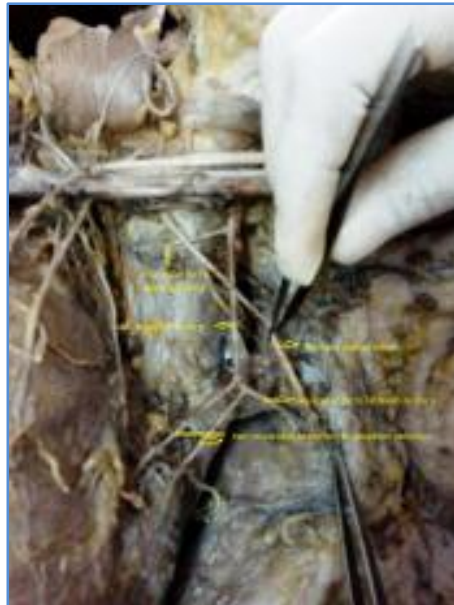**Table 2: Comparative study of no and distribution of terminal branches in males and females**

<b>Name of artery</b>	<b>Area of distribution in males</b>	<b>Area of distribution in females</b>
Branches to serratus anterior	2 <sup>nd</sup> & 5 <sup>th</sup> inter coastal spaces	4 <sup>th</sup> and 5 <sup>th</sup> inter coastal spaces
Muscular	To latissimus dorsi	To latissimus dorsi

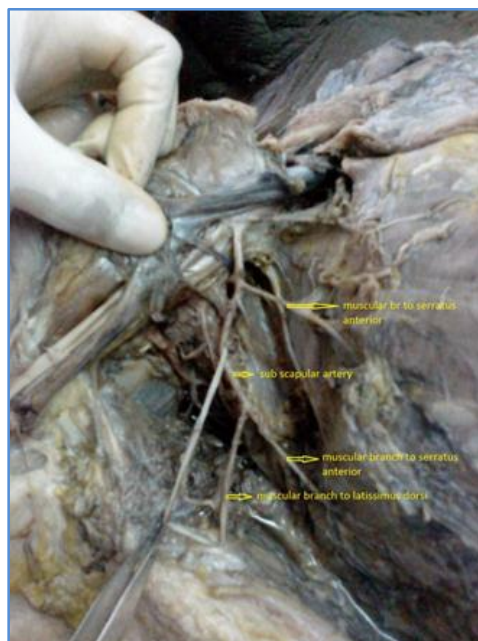
**Table 3: Area of distribution of terminal branches in males and females**

<b>Name of artery</b>	<b>Site of division in males</b>	<b>Site of division in females</b>
Sub scapular artery	Higher	Lower

**Table 4: Site of termination of sub scapular artery in males and females**



**Fig. 1: Sub scapular artery, its collateral and terminal branches in female**



**Fig. 2: Sub scapular artery, its collateral and terminal branches in male**

## ORIGINAL ARTICLE

---

**DISCUSSION:** It was noticed that the subscapular artery was present in 96.7% of cases and originated laterally to the pectoralis minor muscle in 76.7% of cases. Its branches were collateral (To serratus anterior, sub scapularis and teres major) and terminal (To serratus anterior and latissimus dorsi). In the present study we have found that no of collateral branches are more in males and no of terminal branches more in females. In males, distribution of collateral branches leading to the following muscles: serratus anterior (54%) and teres major (26%) and sub scapularis (20%). The distribution of collateral branches in females leading to the following muscles: serratus anterior (30%), and teres major (40%) and sub scapularis (30%). In males, distribution of terminal branches leading to the following muscles: serratus anterior (50%), and latissimus dorsi (50%). The distribution of terminal branches in females leading to the following muscles: serratus anterior (64%), and latissimus dorsi (26%).

Serratus anterior muscle received one collateral and one terminal branch in males whereas females also receiving two branches but both are terminal. Rowsell has mentioned the consistent presence of a branch of the thoracodorsal artery to the serratus anterior muscle. The branches to serratus anterior were of sufficient dimensions to support either a latissimus dorsi flap or a serratus anterior flap<sup>9</sup>. Valnicek has described that three major arterial branching patterns of the subscapular artery were observed with one, two, and three major branches to the serratus anterior in 60 percent, 29 percent, and 9 percent of the cases, respectively. Van Thienen CA has described that distribution of collateral branches to serratus anterior (44%), subscapularis (23%) and teres major (3%). Terminal branches distribution as the following. Serratus anterior (44%), latissimus dorsi (41%).<sup>10</sup>

**CONCLUSION:** In general, our results are similar to the findings in the literature consulted as far as the subscapular artery is concerned.<sup>8</sup> Our research showed collateral branches to the following muscles: serratus anterior (54% in males, 30 % in females), teres major (26% in males, 40% in females) and sub scapularis (20% in males and 30 % in females). Terminal branches to the following muscles: serratus anterior (50% in males, 64 % in females), latissimus dorsi (50% in males and 26% in females). No of collateral branches (three) more in females when compared to males. In this study the serratus anterior receives two branches (one collateral and one terminal) in males whereas females also present two branches but both of them are terminal. The site of termination into muscular branches to serratus anterior and latissimus dorsi is higher in males when compared to females.

### REFERENCES:

1. Aviv JE, Urken M, Vickery C, Weinberg H, Buchbinder D, Biller F. (1991) The combined latissimus dorsi-scapular free flap in head and neck reconstruction, Arch Otolaryngol Head Neck Surg, 117: 1242–1250.
2. Tansatit T, Chokrungravanont P, Wanidchaploi S, Sanguansit P (2007) The anatomy of the thoracodorsal artery in perforator flap for resurfacing shallow defect. J. Med Assoc Thai, 90: 947–955.
3. Valnicek SM, Mosher M, Hopkins J. K, Rockwell W. B. (2004) the subscapular arterial tree as a source of microvascular arterial grafts. Plast Reconstr Surg, 116: 680–682.
4. Romanes GJ (1972) Cunningham's textbook of anatomy. 11 ed. Oxford University Press, London, pp. 879.

## ORIGINAL ARTICLE

5. Essentials of human anatomy vol 3 superior and inferior extremities by A. K. Dutta 4<sup>th</sup> edition, pg. no- 47, 48.
6. Human anatomy vol. 1- upperlimb and thorax by B. D. Chourasia, 5<sup>th</sup> edition, pg. no- 55-57.
7. Gray's anatomy; the anatomical basis of clinical practice, 9<sup>th</sup> edition, pp. 842–845.
8. Fontaine S, Decker G, Goldschmidt D. (1994) Anomalous blood supply to the serratus anterior muscle flap. Br J. Plast Surg, 47: 505–506.
9. Rowsell AR, Davies DM, Eisenberg N, Taylor GI (1984) the anatomy of the subscapular-thoracodorsal arterial system: study of 100 cadaver dissections. Br J Plast Surg, 47: 505–506
10. Van Thienen C. A, Deraemaeker R. (1990) Colgajo de serrato anterior y escapula. Rev Argent Cirug, 58: 233–236.

### AUTHORS:

1. Sreenivasulu. Kanaka
2. E. Ravi Theja
3. P. Moula Akbar Basha
4. R. Somasekhar
5. G. Kanchanalatha
6. K. S. Haniman

### PARTICULARS OF CONTRIBUTORS:

1. Associate Professor, Department of Anatomy, Viswabharathi Medical College, Kurnool.
2. Assistant Professor, Department of Anatomy, Viswabharathi Medical College, Kurnool.
3. Assistant Professor, Department of Anatomy, Viswabharathi Medical College, Kurnool.

### FINANCIAL OR OTHER

**COMPETING INTERESTS:** None

4. Assistant Professor, Department of Anatomy, Viswabharathi Medical College, Kurnool.
5. Professor, Department of Anatomy, Viswabharathi Medical College, Kurnool.
6. Professor & HOD, Department of Anatomy, Viswabharathi Medical College, Kurnool.

### NAME ADDRESS EMAIL ID OF THE CORRESPONDING AUTHOR:

Dr. Sreenivasulu. Kanaka,  
# 87-1377-13, Seshadri Nagar,  
Near Nandyal Check Post, Kurnool-518002.  
E-mail: sreenivas.knk@gmail.com

Date of Submission: 16/06/2015.

Date of Peer Review: 17/06/2015.

Date of Acceptance: 04/07/2015.

Date of Publishing: 10/07/2015.