

CLINICAL STUDY AND MANAGEMENT OF CHOLEDOCHOLITHIASISSuresh Chandu¹**HOW TO CITE THIS ARTICLE:**

Suresh Chandu. "Clinical Study and Management of Choledocholithiasis". Journal of Evolution of Medical and Dental Sciences 2014; Vol. 3, Issue 49, October 02; Page: 11736-11743, DOI: 10.14260/jemds/2014/3541

ABSTRACT: BACKGROUND AND OBJECTIVES: Choledocholithiasis complicates the working and management of cholelithiasis necessitating additional diagnostic procedures, increasing morbidity and mortality. CBD stone generally remain asymptomatic but when symptoms start appearing, cause a lot of suffering. There are various treatment modalities available presently. The objective of our study was to study the incidence, various modes of clinical presentations and different modalities of treatment in common bile duct stones. **MATERIALS AND METHODS:** 35 Patients were prospectively studied from July 2012 to June 2014 as in-patients in Victoria Hospital. **RESULTS:** CBD stones occurred predominantly in elderly females and presented from subclinical jaundice to complications in the form of biliary pancreatitis and cholangitis. USG abdomen with LFT was able to diagnose majority of the CBD stones preoperatively. Per operative cholangiogram was used selectively in case USG was inconclusive, ERCP was used in patients presenting with severe obstructive jaundice, pancreatitis, cholangitis, minimal CBD ductal dilation. Open exploration was the main focus with a wide variety of procedures performed according to specific indications. **CONCLUSION:** CBD was more common in elderly female patients probably due to neglected gall bladder stones. CBD stones can occur from occult asymptomatic stones only with altered LFT to symptomatic presentation in the form of cholangitis, pancreatitis. USG abdomen was inexpensive and easily available imaging modality to diagnose CBD stones with per operative cholangiogram being needed in minority of the cases. While ERCP was good in treating complications of CBD stones and early stages of the disease; the more advanced stage of the disease with gross CBD ductal dilation and multiple stones open CBD exploration were more productive.

KEYWORDS: CBD; USG abdomen; LFT; Per op Cholangiogram; ERCP; Open CBD exploration.

INTRODUCTION: Cholelithiasis is a common surgical problem which makes cholecystectomy one of the most frequently performed surgical procedures. CBD stones complicate the working and management of cholelithiasis, necessitating additional diagnostic and therapeutic procedures and adds to morbidity and mortality of gall stone disease.

Common bile duct stones are present in approximately 5% of the patients undergoing elective cholecystectomy and 10% of patients with acute cholecystitis. No single blood test or combination of blood tests can predict whether or not a CBD stone is present. Intraoperative cholangiography is a gold standard for diagnosis¹, but CBD stones can be diagnosed preoperatively with ultrasound, ERCP or MRCP.

If CBD stones are diagnosed preoperatively, several different treatment modalities can be utilized. The factors that determine the optimal approach include the patient's age and general condition. It is also important to consider the local expertise of the Surgeon and the gastroenterologist in managing CBD stones. Hence the algorithm for managing these patients will vary from one locale to another. There are specific indications that mandate CBD open exploration and therefore, the practicing surgeon must be well versed in these techniques.

ORIGINAL ARTICLE

Although the stones in the CBD may be silent, the development of symptoms is potentially serious; obstructive jaundice, ascending cholangitis, acute pancreatitis are all associated with serious morbidity and at times, mortality which need immediate attention.

METHODOLOGY: The present study was carried out on patients between July 2012 and June 2014, admitted in Victoria Hospital attached to Bangalore Medical College and Research Institute, Bangalore. 42 patients were admitted. 7 patients were used only to study demographic data and were excluded from management protocol as they were not matching inclusion criteria. 35 patients remained in the study.

Detailed clinical history and examination were performed in all cases as per the proforma. Diagnostic investigations – ultrasonography abdomen, LFT were done in all cases. Perop cholangiogram was selectively used when USG was negative for CBD stones, but history and biochemical parameters were suggestive of CBD stones.

Procedural investigations like Hb%, coagulation profile, TC, DC, RBS, Blood urea, serum creatinine, chest X ray and ECG were performed in all cases. Bile cultures were obtained in all cases.

Inclusion Criteria:

1. All the cases of Common bile duct stones with the patient's age >12 years.
2. Pre-op USG diagnosis of ductal dilation >8mm with or without CBD stones. Multiple stones in gallbladder with dilated cystic duct.
3. CBD stones complicating as obstructive jaundice, cholangitis, pancreatitis.

Exclusion Criteria:

1. Patient age ≤12 yrs.
2. CBD <8mm without stone on USG has very low predictive yield by even invasive imaging like per op cholangiogram.

Choice of treatment modality was Open CBD exploration because of our vast experience and adequate facility to perform the same in our institution. ERCP was selectively used only when patient could afford it and there was a definite indication with its usefulness far exceeding the other (open CBD exploration) available therapeutic procedures.

All patients received prophylactic antibiotics in the form of Amikacin and Metronidazole to cover Gram negative and anaerobic organisms. Later antibiotics were changed depending upon the bile culture report. All patients were screened for any coagulopathy and treated appropriately with Vitamin K or fresh frozen plasma depending upon the severity and urgency of the procedure. All patients were adequately hydrated and flushed with mannitol to prevent hepatorenal syndrome.

For open surgery with T-tube closure; discharge was done after the 10th day T-tube cholangiogram was negative for stones and dye in the duodenum was present. Patients with biliary enteric anastomosis were discharged when they were taking oral diet, feeling symptomatically better and the suture wound had healed. Some patients with surgical site infection had extended stay till the surgical wound was dry and healing.

Patients who had undergone ERCP were discharged when feeling symptomatically better and taking oral diet adequately. For laparoscopic CBD explorations protocol similar open CBD was

ORIGINAL ARTICLE

followed since T-tubes were also used in them. Closed suction drains were used in all open and laparoscopic CBD exploration cases. It was kept in subhepatic space and removed after 48 hrs or when the collection was non-bilious and less than 30 ml in 12 hrs.

All patients were followed up on outpatient basis with repeated assessment of patients' symptomatic status, physical exam, liver function tests and abdominal ultrasonography. The interval of follow was 1 week, 2 weeks, 1 month, 2 months, 6 months, 12 months, 18 months and 24 months.

Statistical analysis in the form of percentages, means, confidence intervals, standard deviations, sensitivity, specificity, positive predictive value were calculated to analyze the significance of the diagnostic investigations and the impact of the therapeutic procedures.

RESULTS:

Age Incidence: Age of the patients varied from 22 to 70 years. The mean age for male was 50.92 years and for female, it was 51.74 yrs. (Graph 1).

Sex Incidence: Out of the 35 patients, 13 (37.14%) were male and 22 (62.85%) were female.

Duration of Hospital Stay: 23 patients (65.7%) stayed in the hospital for a duration ranging from 8 to 14 days. Whereas only 4 patients (11.5%) had a stay extending beyond 21 days, no patient was discharged prior to 7 days of admission.

Presenting Symptoms: Most of the patients had pain abdomen and /or jaundice with a mean total bilirubin of 3mg/dl. (Table 1, Graph 2).

Usg Features: 32 patients (91.4%) had thickened/contracted gall bladder suggestive of chronic cholecystitis. Similarly either sludge or stones were present in 32 patients (91.4%).one patient had a sonologically normal gall bladder with CBD stones which was later confirmed to be primary CBD stones.

One patient had undergone cholecystectomy earlier and one patient did not have a gallbladder found during the surgery and not visualized during the radiological investigations as well. The mean CBD diameter was 14.32 mm with most patients having CBD diameter either between 10 to 12 mm (23.5%) or greater than 20mm (23.5%).The highest recorded CBD diameter was 25mm. (Table 2).

Cholangiogram: Per op cholangiogram was used in 3 cases with negative USG for CBD stones and had specificity of 100%.However per op cholangiogram was false positive in one case in post exploration cholangiogram bringing its specificity to 83.33% in this scenario.

ERCP: It had success of clearing the CBD of all the stones in 71.4% of the cases. It failed in 2 cases (28.5%) for which a temporary stent was left followed by open CBD exploration. One patient (14.2%) developed post ERCP pancreatitis.

TREATMENT:

Open Surgery: 28 patients (80 %) were subjected to open CBD exploration which also include 2 failed cases of ERCP. 22 patients (80%) underwent CBDE with T-tube closure. 4 patients (13.3%) underwent choledochoduodenostomy either when sludge was present or the CBD diameter was more than 30mm. 19 patients (67.8%) was more than 20mm.1 case (3.5%) underwent

ORIGINAL ARTICLE

cholechojejunostomy as the patient had a scarred duodenum from acid peptic disease and had undergone Gastrojejunostomy earlier. Another patient underwent the same procedure for impacted calculi at the duodenal papilla. No hepaticojejunostomy was performed for any patients.(Table 3).

COMPLICATIONS: 4 patients (14.28%) developed infection of surgical wound as a result of contamination from the biliary tract. Bile leak was seen in 1 patient (3.5%) due to T-tube dislodgement. 4 patients (14.28%) developed lower respiratory tract infection (LRTI).

Laparoscopic CBD Exploration: 2 cases (66.6%) had successful clearance of the laparoscopic clearance of the CBD following laparoscopic cholecystectomy. 1 case though underwent successful laparoscopic cholecystectomy, had to have open CBD exploration due to an unfavorable anatomy.

Follow Up: 68.57 % (24 patients) have been followed up till the time of submission of this study. 14.7% (5 cases) were lost from follow up after 2 months. While mortality is nil in both open and minimally invasive procedures the morbidity of open procedure was more accounting for 20.58% of the net morbidity of 32.35%.

DISCUSSION: Common bile duct stones are present in approximately 5% of patients undergoing elective cholecystectomy and 10% of patients with acute cholecystitis. No single blood investigation or combination of blood investigations can predict whether or not a common bile duct stone is present. Intraoperative cholangiography is the gold standard of diagnosis but CBD stone can be diagnosed preoperatively with ultrasound, ERCP, or magnetic resonance Cholangiopancreatograph.¹

If choledocholithiasis is diagnosed preoperatively, several different modalities can be utilized. The factor that determine the optimal approach include patient's age and condition, the presence of jaundice or cholangitis and size of the duct and stone. It is also important to consider the local expertise of the surgeon and gastroenterologist in managing common duct stones. Hence, algorithm for managing these patients will vary from one locale to another.

The natural history of choledocholithiasis is unpredictable. Small stones may pass spontaneously into the duodenum without causing symptoms, or they may obstruct the pancreatic duct temporarily, induce an episode of pancreatitis, and pass into the duodenum with relief of symptoms. Stones that do not pass into the duodenum may reside in the bile duct for long, symptom free periods, then suddenly precipitate an episode of jaundice or cholangitis.²

During the study period, 512 cases of documented cholelithiasis were admitted out of these 45 had evidence of common bile duct stones. Thus incidence of CBD stone in milieu of cholelithiasis was 8.78%.

According to Gerard, the overall incidence of CBD stones was 8% of the cases with cholelithiasis 61.

The female to male ratio was 1.5. According to Girard RM,³ the female to male ratio was 1.72.

According to Wani NA⁶⁴ et al, 94% had pain in the right upper abdomen. According to Acosta JM et al, gall stones are responsible for 50% of all cases of pancreatitis⁴. Conversely, 4 – 8% of patients with gall stones develop pancreatitis. This was in accordance to our study of pancreatitis in 2 cases (5.8%).

ORIGINAL ARTICLE

Clinical jaundice was present in 16 patients (45.7%) with positive predictive value of 64%. This was roughly in accordance to meta-analysis by Abboud⁵ (1996) et al which showed jaundice having positive predictive value of 39% for choledocholithiasis. According to that study, the specificity of cholangitis in predicting CBD stones was 99%.

Mean serum total Bilirubin was 3.022 and 95% confidence interval 3.05 – 3.01. The sensitivity of elevated bilirubin in predicting CBD stones in our study was 88.2%. This is more than study done by Abboud⁵ et al of 69% sensitivity probably due to advanced presentation of cases with prolonged and significant cholestasis.

The abdominal USG was able to detect gall stones in gall bladder in all cases (100%) which is in agreement with Zinner MJ et al which states that the presence of associated gall bladder stone can be confirmed >98% of patient with gall stones and dilation of the intrahepatic biliary system can be identified in most.⁶

The Specificity of ERCP in confirming CBD stones was 100%, which compares with that of Frey et al of 98%⁷. Sensitivity could not be determined as ERCP was only selectively used. All patients underwent ERCP with endoscopic sphincterotomy and stone extraction by either Dormia basket or Fogarty balloon.

The success of ERCP in clearing the CBD of stones was 5 out of 7 cases (71.4%), which is in agreement with Freeman Met al,⁸ which states that complete clearance of all CBD stones is achieved endoscopically in 71-75% of the patients with the first procedure and 84 – 95% of the patients with multiple endoscopic procedures.

Approximately 30% of the patients will require intraop cholangiogram at the time of cholecystectomy. Cholangiography was accurate in 100% of the cases in our studies compared to Girard et al,³ of 88%.

Overall as a part of biliary enteric drainage choledochoduodenostomy was chosen. This is in accordance with Schein and Gliedmann⁹ which states that choledochoduodenostomy is a safe and simple operation with low morbidity and mortality especially in elderly patients than transduodenal sphincteroplasty.

While mortality is nil in both open and minimally invasive procedures the overall morbidity of open procedure was more accounting for 20.0% (7/35) than minimally invasive 11.42% (4/35) and net morbidity was 31.42% (11/35). Component morbidity have already been discussed. 0% Mortality in open.

CBD exploration (Pappas et al¹⁰) and endoscopic (Shivak¹¹), laparoscopic CBD (Petelin¹²) have been recorded which is in agreement with our study.

CONCLUSION: The management of CBD stones has been subject to much debate during the past several years, especially with the advent of new laparoscopic techniques and greater expertise of endoscopic procedures.

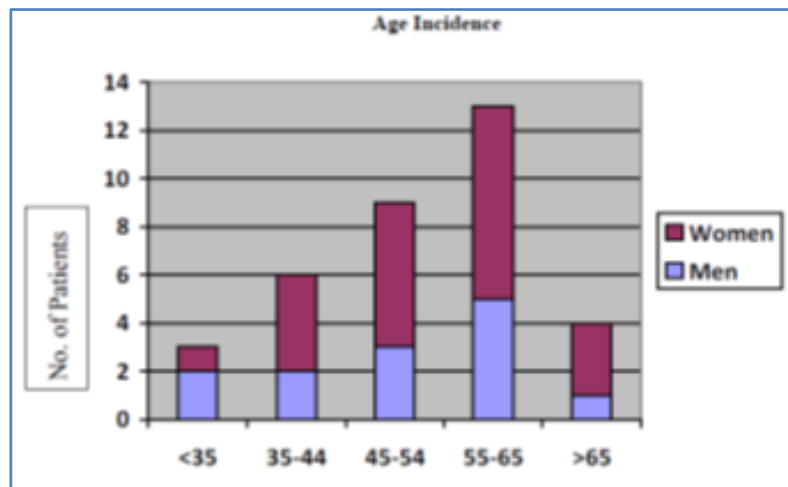
This study was undertaken to get a clinical perspective of CBD stones in the milieu of GB stones and to determine the optimal approach for the management with the age of the patient, general condition, complicating factors, availability of endoscopy and minimally invasive procedure, determining the algorithm of treatment. The end result of our study was the developing of a management protocol in our setting.

ORIGINAL ARTICLE

To conclude, there can be no definite algorithm for the management of CBD stones as the patients' age, underlying general condition being the only standardizable factor with facilities for endoscopic, laparoscopic management being variably available from institution to institution and hence, necessitating tailoring the management of CBD stones depending upon the Institution's resources.

REFERENCES:

1. Cameron J L. Current surgical therapy.8th ed. Philadelphia: Elsevier- Mosby; 2004: 403-404.
2. Blumgart L H. Surgery of the liver, biliary tract and pancreas.4th ed. Philadelphia: Saunders-Elsevier; 2007.
3. Girard RM, .Stones in the common bile duct: surgical approaches. In Blumgart LH, Fong (eds). Surgery of the liver and biliary tract.3rd ed. Philadelphia: Saunders; 2000: 737.
4. Acosta JM, Ledesma CL. Gall stone migration as a cause of acute pancreatitis. New Eng J Medicine 1974; 290: 484-487.
5. Abboud PA, Malet PF, Berlin JA et al. Predictor of common bile duct stone prior to cholecystectomy:a meta –analysis. Gastrointest Endosc 1996; 44: 450-455.
6. Zinner MJ et al. Maingot, s Abdominal operations.10th ed. Stamford (CT): Appleton and Lange; 1997: 1739-1753.
7. Frey CF, Burbige EJ, Meinke WB, et al. Endoscopic retrograde cholangiopancreatography. Am J Surg 1982; 144: 109-114.
8. Freeman M, Nelson D, Sherman S, et al.Complication of Endoscopic biliary sphincterotomy. N Eng J Med 1996; 335: 909.
9. Schein CJ, Gliedman ML.Choledochoduodenostomy as an adjunct to choledocholithotomy. Surg Gynecol Obstet 1981; 152: 797-804.
10. Papas TN, et al.100 consecutive common duct exploration without mortality 1990. Ann Surg; 211: 260-262.
11. Sivak MV. Endoscopic management of bile duct stones.Am J Surg 1989; 158: 228-240.
12. Petelin J. Laproscopic approach to common duct pathology 1993.Am J Surg; 165: 487.

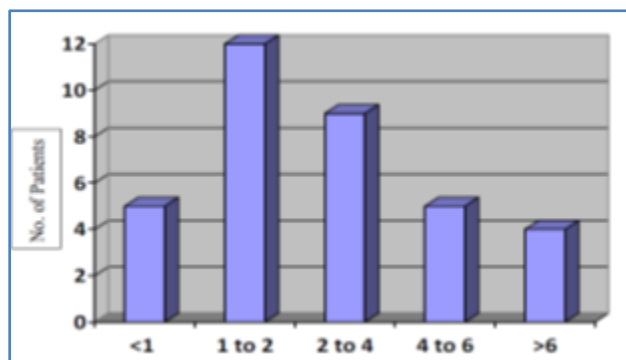


Graph 1: Age incidence

ORIGINAL ARTICLE

Presenting symptom	No. of patients (%)
Pain	33(94.2)
Jaundice	20(57.1)
Fever	12(34.2)
Pancreatitis	2(5.71)

Table 1: Clinical features



Graph 2: Total bilirubin level

Findings	No. of patients	%
Wall thickening	33	94.2
Stones	29	82.8
Sludge	6	17.1
No gall bladder	1	2.85
Dilation of Intrahepatic ducts	35	100

Table 2: USG features

Procedure	Number (n = 28)	%
CBDE + T-tube Closure	22	78.5
CBDE + Choledochoduodenostomy	4	14.2
CBDE + Choledochojunostomy	2	7.14

Table 3: Open procedure

ORIGINAL ARTICLE

AUTHORS:

1. Suresh Chandu

PARTICULARS OF CONTRIBUTORS:

1. Associate professor, Department of General Surgery, Bangalore Medical College and research institute, Bangalore.

NAME ADDRESS EMAIL ID OF THE CORRESPONDING AUTHOR:

Dr. Suresh Chandu,
#201, B Block,
Elite Meenakshi Classic Apartment,
27th Main, 1st Sector,
HSR Layout, Bengaluru-560102.
Email: dr.sureshchandu@gmail.com

Date of Submission: 15/09/2014.
Date of Peer Review: 16/09/2014.
Date of Acceptance: 24/09/2014.
Date of Publishing: 01/10/2014.