

CEREBRAL HYDATID DISEASE: CT AND MR IMAGING FINDINGSAjay Kumar¹, Sanjeev Suman², Priyanka³, G. N. Singh⁴, Rishikant Singh⁵**HOW TO CITE THIS ARTICLE:**

Ajay Kumar, Sanjeev Suman, Priyanka, G. N. Singh, Rishikant Singh. "Cerebral Hydatid Disease: CT and MR Imaging Findings". Journal of Evolution of Medical and Dental Sciences 2014; Vol. 3, Issue 58, November 03; Page: 13062-13070, DOI:10.14260/jemds/2014/3737

ABSTRACT: OBJECTIVE: Cerebral hydatid disease is very rare, representing only 2% of all cerebral space occupying lesions even in the countries where the disease is endemic. The aim of this paper is to describe the characteristic features of cerebral hydatid disease in computed tomography (CT) and magnetic resonance imaging (MRI). **METHODS:** Here is a case 25yr/m who presented to neurosurgery OPD with complaints of headache, vomiting, right sided weakness and seizures for 2 weeks. CT and MRI were the imaging modalities to reach the diagnosis which was pathologically confirmed postoperatively as hydatid disease. **RESULTS:** CT and MR imaging findings of E. granulosus lesions were well defined, smooth thin-walled, spherical, homogeneous cystic lesions with no contrast enhancement, no calcification, and no surrounding oedema. **CONCLUSION:** Although cystic cerebral hydatid disease is well demonstrated by CT and MR examinations, CT is superior in detecting calcification in the cyst, when present, MR is better in demonstrating cyst capsule, detecting multiplicity and defining the anatomic relationship of the lesion with the adjacent structures, and it is more helpful in surgical planning.

KEYWORDS: cerebral hydatid disease; echinococcosis; computer tomography (CT); magnetic resonance imaging (MRI).

INTRODUCTION: Hydatid disease (echinococcosis) is a worldwide zoonosis produced by the larval stage of the Echinococcus tapeworm. In humans, the two main types of hydatid disease are caused by E. Granulosus and E. multilocularis. The disease is endemic in many parts of the world, particularly in the Middle East, Australia, New Zealand, South America and central and south Europe, as well as in Turkey.

In India, the hydatid disease is more commonly seen in the Kurnool district of Andhra Pradesh, Madurai district of Tamil Nadu and in Punjab. Various series of intracranial hydatids from India have reported its incidence as 0.2% of all intracranial space occupying lesions. These regions are all noted for the raising of sheep and cattle. It is important to be aware of the condition even in non-endemic parts of the world, where only occasional cases are encountered, because of the rapid movement of large human groups from endemic to non-endemic areas.

The diagnosis of hydatid cyst relies on serologic tests and imaging techniques. Cerebral hydatid disease is more common in paediatric population. This high incidence in children is probably related to patent ductus arteriosus. Most Hydatid cysts are acquired in childhood but are not diagnosed until the 20's or 30's. The growth of hydatid cysts is usually slow and asymptomatic, and clinical manifestations are caused by compression of the involved organ.

Cysts may be single or multiple, uni or multiloculated, and thin- or thick walled. More specific signs include visualisation of a calcified wall, presence of daughter cysts, and membrane detachment. Cerebral hydatid cysts are extremely rare, forming only 2% of all intracranial space-occupying lesions. Most cysts are supratentorial.

ORIGINAL ARTICLE

They can occur anywhere within the brain, but are especially located in the middle cerebral artery territory. The parietal lobe is the most frequently involved region.

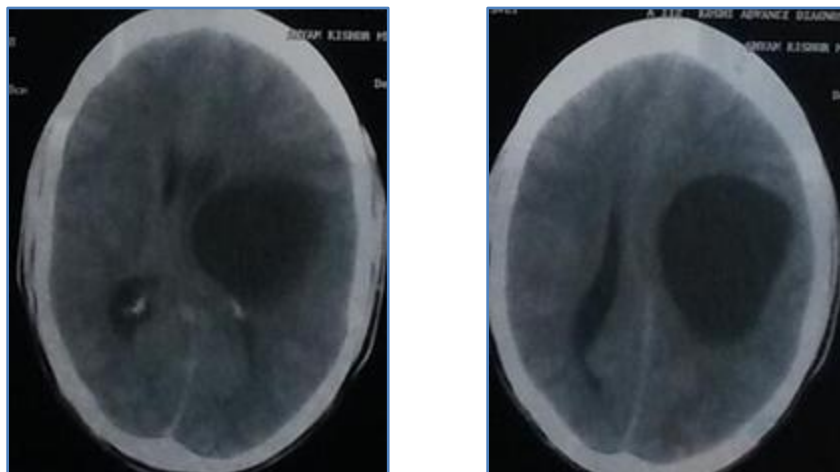
Several diagnostic methods have been employed, but CT has been providing definitive results up to recent years. The exact location, size and number of hydatid cysts in the brain can be determined with a CT scan. However, MR is becoming more and more widely used as a diagnostic tool, as it can show some details that are not be seen on CT. We present the features of CT and MR findings of our cases with cerebral hydatid disease.

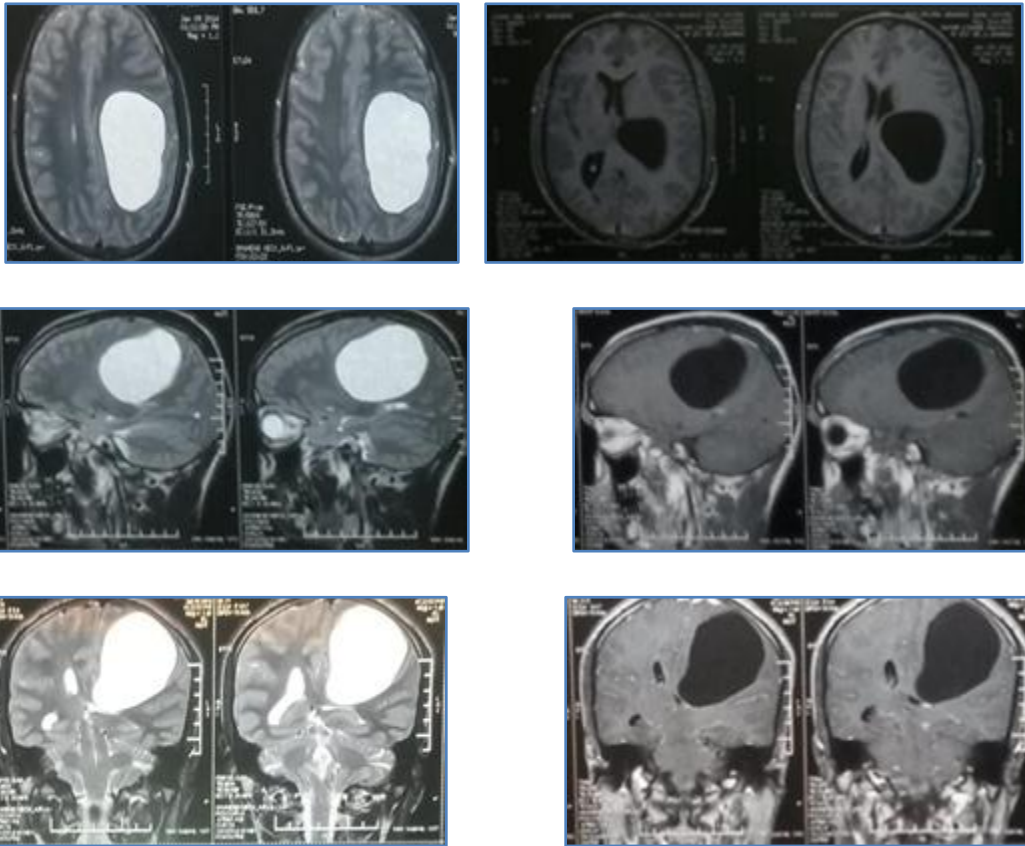
METHODS: A 25 year male from Madhepura presented to neurosurgery OPD with complains of headache, vomiting for 2 weeks. Right sided weakness and seizures were also present. O/E patient was conscious, oriented with GCS 15/15. All the vitals were stable. Non-contrast CT and MRI were done.

On CT and MR, the number, location, internal structure and contour of the lesions, the presence of contrast enhancement, calcification, and surrounding oedema were detected. Histopathological confirmation was done pathologically with specimens obtained by neurosurgery in patient. Gold standard for the diagnosis of cerebral hydatid cyst was histopathological examination results. As a follow-up protocol, our patient was called for postoperative CT. Patient underwent a chest x-ray and abdominal ultrasound to reveal any hydatid disease in the lung and/or the liver.

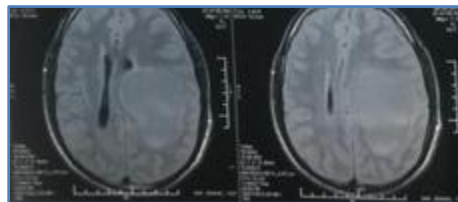
CT demonstrated large, smooth, thin-walled, spherical well-defined, non-associated oedema and non-enhancing homogeneous lesions, which have an inner density similar to CSF. MR demonstrated well-defined round (spherical) hypointense lesions on T1-weighted images and hyperintense lesions on T2-weighted images. The walls of the cysts were hypointense on T1- and T2-weighted images. No calcification, no surrounding oedema, and no contrast enhancement were seen on CT and MR in non-complicated cystic echinococcosis lesion.

CT Brain: A large, well defined, thin walled, axial cystic lesion is seen in left parietal region causing compression of ipsilateral lateral ventricle.

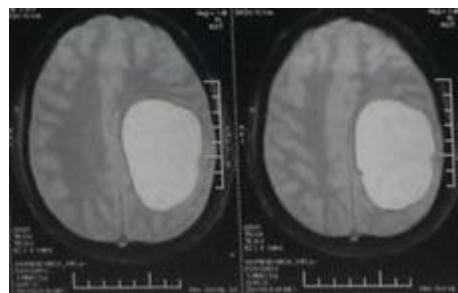


MRI Brain:

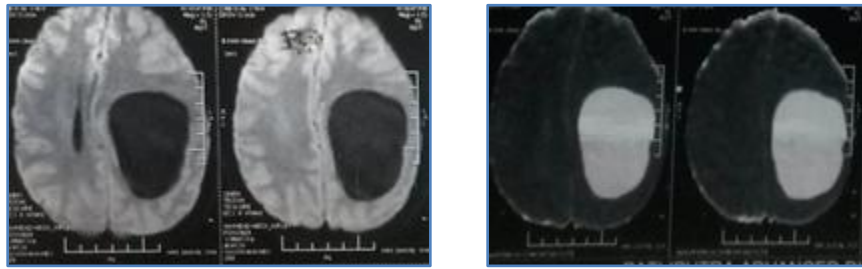
A large well defined rounded axial T1 weighted post contrast axial, lesion is seen in left parietal region, coronal, saggital images shows lesion to be hypointense with no enhancement. T2 weighted axial, saggital, coronal images shows lesion to be hyperintense.



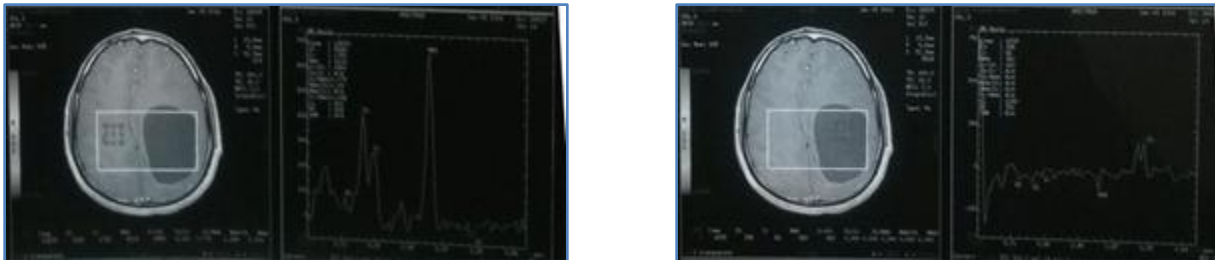
Lesion is iso-hyperintense on T2 FLAIR image.



Gradient echo sequences shows lesion to be hyperintense. No blooming is seen.



On DWI and ADC map no restriction of diffusion is seen.



MRS shows depressed Creatinine, N-Acetyl aspartate and choline and large peak of lipid lactate

DISCUSSION: Hydatid disease, although rare, is usually seen in endemic areas of sheep-raising countries. Humans acquire the disease mostly during childhood.

- **Notable sites include**

- * hepatic hydatid infection - commonest organ.
- * pulmonary hydatid infection - 2nd commonest organ.
- * splenic hydatid infection.
- * CNS hydatid infection.
- * retroperitoneal hydatid infection.
- * renal hydatid infection.
- * bony hydatid infection.

They may reach a considerable size before the patient becomes Symptomatic.

The cerebral hydatid cysts are slow growing and present late when they increase in size and become large. There is no consensus on the growth rate of the hydatid cysts of the brain and has been variably reported between 1.5-10cm/year.

- **Etiopathogenesis:** There are two main strains which are:

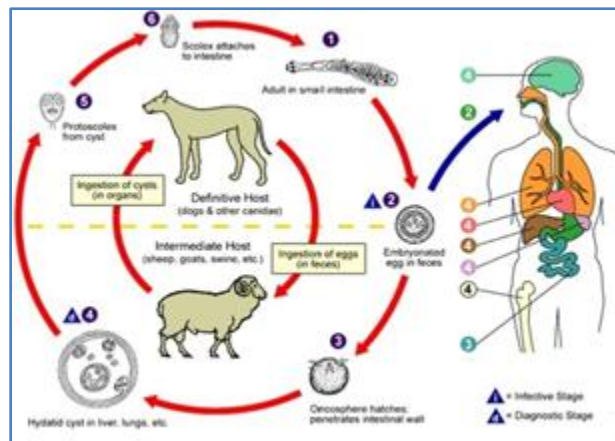
- * Echinococcus granulosus: commoner
- * definitive host: dog/ occasionally another carvinore
- * intermediate host: sheep
- * Echinococcus alveolaris/ multilocularis: less common but more invasive.

ORIGINAL ARTICLE

- **Cyst structure:** The cysts usually have three components:
 - * pericyst: Composed of inflammatory tissue of host origin
 - * ectocyst: cyst membrane allows passage of nutrients
 - * endocyst: inner germinal layer gives rise to brood capsules (daughter vesicles), scolices

- **Cyst classification:** Based on morphology the cyst can be classified into 4 different types²:
 - * type I - simple cyst with no internal architecture.
 - * type II - cyst with daughter cyst(s) + matrix.
 - * type IIa - round daughter cysts at periphery.
 - * type IIb - larger, irregularly shaped daughter cysts occupying almost the entire volume of the mother cyst.
 - * type IIc - oval masses with scattered calcifications and occasional daughter cysts
 - * type III - calcified cyst (dead cyst).
 - * type IV - complicated cyst: e.g. ruptures cyst.

Humans get infected through the faeco-oral route by ingestion of food or milk contaminated by dog faeces containing ova of the parasite or by direct contact with dogs. The eggs lose their enveloping layer in the stomach, releasing the embryos. The embryos pass through the wall of the gut into the portal system and are carried to the liver where most larvae get entrapped and encysted. Some may reach the lungs and occasionally, some may pass through the capillary filter of the liver and lungs and get entry into the systemic circulation. These may even reach the brain.



The cyst of alveolar echinococcosis differs from that of cystic echinococcosis in that it grows by external budding of the germinal membrane with progressive infiltration of the surrounding tissue. Cerebral cystic echinococcosis is most commonly seen in children and young adults (approximately 50–70%). Lunardi et al. and El-Shamam et al., reported that cerebral hydatid cysts are commonly seen in children especially in males and young adults.

Beskonaklı et al, reported a reasonable explanation for this as young male children were more closely occupied with animals than girls or adults and were not as aware of the importance of hygienic principles. The average age of patients with cerebral alveolar echinococcosis is significantly higher than in cystic echinococcosis.

ORIGINAL ARTICLE

Symptoms: The patients with intracranial hydatid cysts usually present with focal neurological deficit and features of raised intracranial pressure; the latter may be due to the large size or due to interference with pathway of CSF flow. Headache and vomiting are the most commonly reported symptom. Other symptoms such as hemiparesis, seizures, visual field alteration and gait disorders, may vary with the location of the cyst. Papilloedema is usually present in patients with intracranial hydatid cysts at the time of diagnosis.

Location: Lesions of cerebral hydatid disease are usually distributed in the territory of the middle cerebral artery, especially in the parietal lobe. Most of the cysts are located in the supratentorial regions and very rarely in the posterior cranial fossa, or ventricles. The less common sites reported are skull, cavernous sinus, eyeball, pons, skull, extra dural, cerebellum and ventricles.

Cerebral cystic echinococcosis lesions are usually single. Multiple cerebral cystic echinococcosis is very rare.

Intracranial hydatid cyst may also be classified as primary or secondary.

- * The primary cysts are formed as a result of direct infestation of the larvae in the brain without demonstrable involvement of other organs. In primary multiple cysts, each cyst has a separate pericyst with brood capsule scolices and these originate from multiple larvae affecting brain after crossing the gastrointestinal tract, liver, lungs and right side of heart without affecting them. The primary cysts are fertile as they contain scolices and brood capsules, hence rupture of primary cyst can result in recurrence. Primary multiple cysts are uncommon
- * The secondary multiple cysts results from spontaneous, traumatic or surgical rupture of the primary intracranial hydatid cyst and they lack brood capsule and scolices. The secondary intracranial hydatid cysts are therefore, infertile and the resultant risk of recurrence after their rupture is negligible.

Both CT and MRI demonstrate a spherical and well-defined, smooth, thin walled, homogeneous cystic lesion with fluid density similar to the cerebrospinal fluid, with or without septations or calcification. On unenhanced CT, the cyst wall was iso dense or hyper dense to brain tissue. The cyst wall usually showed a rim of low signal intensity on both T1- and T2-weighted images. Calcification of the wall was rare, being less than 1%. The presence of daughter cysts is considered pathognomonic but has been rarely reported. Compression of the midline structures and ventricles are seen in most of the cases, however surrounding oedema and rim enhancement are usually absent in untreated or uncomplicated cases. Obvious mass effect is seen in most larger lesions.

Differential diagnosis: Includes cystic lesions such as porencephalic cyst, arachnoid cyst, cystic tumor of the brain and pyogenic abscess. In contrast to hydatid cysts, porencephalic cyst and arachnoid cysts are not spherical in shape and not surrounded entirely by brain substance. Arachnoid cysts are extra-axial masses that may deform adjacent brain. Porencephalic cysts result from insults to normal brain tissue and are lined by gliotic white matter that could easily be demonstrated with MR imaging. Cystic tumours of the brain could be differentiated by the enhancement of the mural nodule, if any, and periphery of the tumour.

ORIGINAL ARTICLE

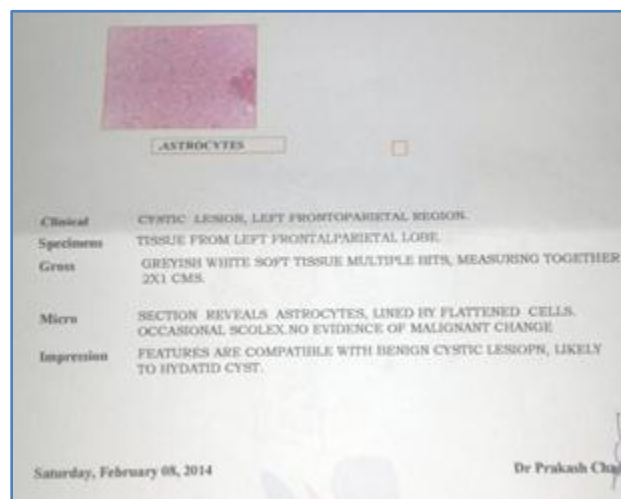
When a pyogenic abscess shows a cyst-like central necrotic area; peripheral oedema is almost always present, the rim enhances intensely following contrast administration and satellite lesions are commonly present, all of which could be demonstrated on both CT and MR images. Clinical and laboratory findings could also aid in the differential diagnosis of the patients with cerebral abscess formation. Cerebral cysticercosis should also be kept in mind in the differential diagnosis of cerebral echinococcosis. Serologic analysis in most cases is negative; pathohistologic analysis is the most reliable method of diagnosis.

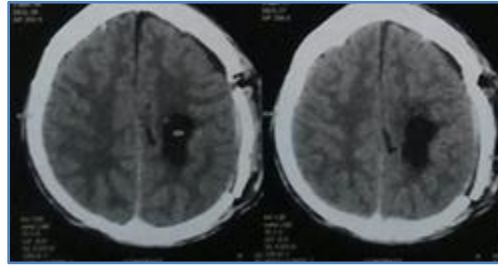
Proton MR Spectroscopy (PMRS) and diffusion-weighted (DWI) MR imaging has recently been used to distinguish between cerebral abscess and cystic or necrotic brain tumor. The differentiation between cystic or necrotic brain tumor and cerebral abscess has been well documented. However, there are a few reports of its use in differentiation in other types of cystic lesions. Cases of hydatid cysts demonstrated resonances from lactate, alanine acetate and succinate and a high resonance for pyruvate and in patient with perifocal oedema choline resonance is seen. In three cases of arachnoid cysts only small lactate resonance was observed. Neoplasm of the brain characteristically demonstrates an increase in choline compounds and lactate with a decrease in NAA.

TREATMENT: The lesion was removed surgically by adopting pericystic hydraulic during left F/T/P craniotomy. There was no intra-operative morbidity. No postoperative complications were noted and there was no mortality.

For pericystic hydraulic method, after anaesthetic and surgical consent, the patient is anesthetized and position is made. Large craniotomy flap is made depending on the size and site of the lesion. Bone is extremely thin in these cases. Careful osteoplastic bone flap is made and dura opened in a wide cruciate incision. Cyst is dissected below cortex by doing small corticotomy. With the help of Foley's catheter, irrigation is started to the cleavage line in the brain-cyst interface. Patient is brought down the heart level and the anaesthetist is asked to perform valsalva manoeuvre. Surgery area of brain is covered with normal saline soaked cottonoid to prevent spillage in case of rupture. Cyst is removed and dura is closed water tight. Bone flap is put back and Patient is dressed after wound.

Specimen was sent for histopathological examination which confirmed it to be hydatid cyst.





A small residual disease is seen in left parietal region.

In conclusion, CT and MR imaging, alone or combination, are helpful in the diagnosis of cerebral hydatid disease. Although CT is superior in detecting calcification of the cyst wall or septa, when present, MR is better in detecting multiplicity and defining the anatomic relationship of the lesion with the adjacent structures and helps in surgical planning. MR provides additional information and details that cannot be seen by CT. It provides additional information in the exact localisation of the cyst.

When present, in complicated or recurrent disease, surrounding oedema can better be demonstrated with MR imaging owing to the inherent capability of the imaging modality in revealing subtle differences in the tissue content. When a well-defined spherical cystic intracerebral lesion with obvious mass effect, but no surrounding oedema and no contrast enhancement following contrast administration is detected on CT and MRI, hydatid disease should be taken into consideration in countries where the disease is endemic.

If perilesional oedema and thin rim enhancement are observed either complicated hydatid cyst or other cystic lesions of the brain should be considered in the differential diagnosis. CT and MR findings in cerebral echinococcosis are more characteristic than in cerebral alveolar echinococcosis, but characteristic CT and MR findings of multiloculated cystic alveolar echinococcosis should also be remembered for the differential diagnosis.

REFERENCES:

1. Atalar M. Hydatid Cyst: A Pictorial Review of Radiological Appearances: Journal of Clinical and Analytical Medicine 2011
2. Ali M, Mahmood K, Khan P; Hydatid cysts of brain; J Ayub Med Coll Abbottabad 2009;21(3)
3. Yas, ar Buktea, Serdar Kemanog˘lub, Hasan Nazarog˘lua, Umit Ozkanb, Adnan Cevizb, Masum Sims, eka; Cerebral hydatid disease: CT and MR imaging finding; Swiss Med Wkly 2004; 134: 459 –467.
4. Gossios KJ, Kontoyiannis DS, Dascalogiannaki M, Gourtsoyiannis NC. Uncommon locations of hydatid disease: CT appearances. Eur Radiol 1997; 7:1303–8.
5. Diren HB, Ozcanli H, Boluk M, Kilic C. Unilocular orbital, cerebral and intraventricular hydatid cysts: CT diagnosis. Neuroradiology 1993; 35:149–50.
6. Haliloglu M, Saatci I, Akhan O, Ozmen MN. Besim A. Spectrum of imaging findings in pediatric hydatid disease. AJR Am J Roentgenol 1997; 169: 1627–31.
7. Tunaci M, Tunaci A, Engin G, Ozkorkmaz B. Ahishali B. Rozanes I. MRI of cerebral alveolar echinococcosis. Neuroradiology 1999; 41:844–6.

ORIGINAL ARTICLE

8. Tuzun M, Hekimoglu B. Hydatid disease of the CNS: imaging features. *AJR Am J Roentgenol* 1998; 171:1497–500.
9. Bensaid AH, Dietemann JL, Filippi de la Palavesa MM, Klinkert A, Kastler B, Gangi A, et al. Intracranial alveolar echinococcosis: CT and MRI. *Neuroradiology* 1994; 36: 289–91.
10. Osborn AG. Miscellaneous tumors, cysts and metastases. In: Patterson AS, ed. *Diagnostic Neuroradiology* St. Louis, Mo: Mosby; 1994:639–48.
11. Osborn AG. Infections of the brain and its linings. In: Patterson AS, ed. *Diagnostic Neuroradiology* St. Louis, Mo: Mosby; 1994:688–94.
12. Kim YJ, Chang KH, Song IC, Kim HD, Seong SO, Kim YH, et al. Brain abscess and necrotic or cystic brain tumor: discrimination with signal intensity on diffusion-weighted MR imaging. *AJR Am J Roentgenol*. 1998; 171: 1487–90.
13. Shukla-Dave A, Gupta RK, Roy R, Husain N, Paul L, Venkatesh SK, Rashid MR, et al. Prospective evaluation of in vivo proton MR spectroscopy in differentiation of similar appearing intracranial cystic lesions. *Magn Reson Imaging* 2001; 19:103–10.

AUTHORS:

1. Ajay Kumar
2. Sanjeev Suman
3. Priyanka
4. G. N. Singh
5. Rishikant Singh

PARTICULARS OF CONTRIBUTORS:

1. Senior Resident, Department of Radiology, PMCH, Patna.
2. Senior Resident, Department of Radiology, PMCH, Patna.
3. Junior Resident, Department of Radiology, PMCH, Patna.
4. HOD, Department of Radiology, PMCH, Patna.

5. Senior Resident, Department of Neurosurgery, GMCH, Guwahati.

NAME ADDRESS EMAIL ID OF THE CORRESPONDING AUTHOR:

Dr. Ajay Kumar,
78, Narmada Apartments,
Exhibition Road,
Patna-800001.
Email: kajay8719@gmail.com

Date of Submission: 16/08/2014.
Date of Peer Review: 18/08/2014.
Date of Acceptance: 29/10/2014.
Date of Publishing: 31/10/2014.