

VOLAR PLATING OF DISTAL RADIUS FRACTURE: A RETROSPECTIVE ANALYSISVictor Moirangthem¹, Bharat Kumar R. J², Vijayanand R. R³, Narayana Reddy M⁴**HOW TO CITE THIS ARTICLE:**

Victor Moirangthem, Bharat Kumar R. J, Vijayanand R. R, Narayana Reddy M. "Volar Plating of Distal Radius Fracture: A Retrospective Analysis". Journal of Evolution of Medical and Dental Sciences 2015; Vol. 4, Issue 52, June 29; Page: 9094-9102, DOI: 10.14260/jemds/2015/1318

ABSTRACT: BACKGROUND: Treatment of distal radius has undergone remarkable changes since the time of Abraham Colles. Conservative treatment with cast application has given way to operative techniques for better outcome in high demand young individuals. Volar plating for distal end radius fractures is an effective technique which allows early mobilisation with restoration of radial inclination, radial length, articular congruity and palmar tilt. **MATERIALS AND METHODS:** This study was performed in chettinad hospital and research institute between January 2013 and March 2014. 24 patients with closed isolated distal end radius fractures treated with open reduction and internal fixation with plates and screws by volar approach were followed up retrospectively for a minimum period of one year. There were 17 men and 7 women. Mean age was 44 years (Range, 22-75 years). The fractures were classified based on the AO system. There were 4 A2, 12 B3, 5 C1, 3 C2 fracture types. **RESULTS:** All the patients were evaluated with standard anteroposterior and lateral radiographs and CT scans in case of intraarticular fractures. In all patients plating of distal end radius done by volar approach. Patients were followed postoperatively for one year radiologically and clinically by modified clinical scoring system by Green and O'Brien. Five patients had excellent results, thirteen patients had good results with twenty five percent restriction of wrist function. Five patients had fair results. One patient had postop wound infection which required implant removal and external fixator application. **CONCLUSION:** With proper patient selection and accurate surgical techniques, volar plating continues to be a useful method of treatment for distal end radius fractures with minimal complications and allowing early return of patients to normal activities.

KEYWORDS: volar plating, distal end radius fracture,

INTRODUCTION: From the earliest description of distal radius fracture by Abraham Colles¹ until now, the various methods of treatment of distal radius fracture have undergone remarkable changes and are still evolving. Although cast treatment gives good functional outcome in geriatric patients,^{2,3} it has given way to operative methods for better outcome in high-demand younger patients. A multiple array of surgical techniques for fixation of distal radius fracture are available which include pins and plaster, spanning external fixator, percutaneous pinning and various types of plates and screws.⁴ Volar plating of Barton fracture introduced by Ellis⁵ continues to be a useful addition in the armamentarium for treatment of distal radius fractures. Many studies have shown the effectiveness of this technique in allowing early mobilization with restoration of radial length, radial inclination, articular congruity, and palmar tilt.^{6,7,8,9} The purpose of this retrospective study is to analyse the functional and radiological outcomes of patient with isolated distal radius fracture treated with plating using a volar approach.

MATERIALS AND METHODS: Between January 2013 and March 2014, 24 patients with closed isolated distal radius fractures who underwent open reduction and internal fixation with plates and screws through standard volar approach at Chettinad Hospital & Research Institute were included in

ORIGINAL ARTICLE

the study. All of these patients underwent the procedure within a week after the injury and were followed up for a minimum duration of one year. There were 17 men and 7 women. Mean age was 44 years (Range, 22-75 years). The fractures were classified based on the AO system. There were 4 A2, 12 B3, 5 C1, 3 C2 fracture types. The modes of injuries were motor vehicle accidents in 19 patients and fall on the outstretched hand in the remaining patients. Out of the 24 patients only one patient had a bilateral fracture. The fracture involved the right wrist in 12 patients and left wrist in 11 patients. All the fractures were screened with standard radiographs of the wrist which included anteroposterior and lateral projections and CT scan for intra-articular fractures.

Patient Demographic Profile					
Case	Age (years)	Gender	Mode of Injury	Laterality	AO type
1	48	Male	Motor vehicular accident	Right	A2
2	75	Male	Fall on outstretched hand	Left	C1
3	40	Male	Motor vehicular accident	Right	B3
4	25	Male	Motor vehicular accident	Right	A2
5	29	Male	Motor vehicular accident	Both	B3
6	51	Male	Motor vehicular accident	Left	B3
7	30	Male	Motor vehicular accident	Left	B3
8	63	Female	Fall on outstretched hand	Right	A2
9	28	Male	Motor vehicular accident	Left	C2
10	30	Male	Motor vehicular accident	Right	C1
11	48	Female	Motor vehicular accident	Right	C2
12	32	Male	Motor vehicular accident	Left	B3
13	74	Female	Fall on outstretched hand	Left	B3
14	49	Female	Motor vehicular accident	Left	C1
15	45	Female	Motor vehicular accident	Right	A2
16	60	Male	Motor vehicular accident	Right	C1
17	56	Female	Fall on outstretched hand	Right	B3
18	22	Male	Motor vehicular accident	Left	B3
19	39	Male	Motor vehicular accident	Left	C1
20	58	Male	Motor vehicular accident	Right	B3
21	62	Female	Fall on outstretched hand	Left	B3
22	40	Male	Motor vehicular accident	Right	C2
23	32	Male	Motor vehicular accident	Left	B3
24	30	Male	Motor vehicular accident	Right	B3

Table 1

The surgical procedure was performed under regional anaesthesia (Interscalene block). We used a standard volar approach for distal radius where the incision is made between flexor carpi radialis and radial artery. Deep dissection proceeds with reflection of the pronator quadratus using an L-shaped incision to expose the fracture line. The fracture was reduced with longitudinal traction and digital pressure over the dorsal aspect. Temporary K-wires were used to maintain the reduction and to facilitate placement of a volar plate. Care was taken to avoid screws penetrating the radiocarpal joint and screw tips protruding excessively over the dorsal aspect. After checking the

ORIGINAL ARTICLE

fracture reduction and the implants under image intensifier, the skin was closed using interrupted non-absorbable suture. The pronator quadratus was usually repaired before skin closure. Tourniquet was not used for the procedure. The limb was immobilised in a short arm plaster splint until suture removal on the tenth post-operative day. Active finger movements were initiated early followed by wrist mobilisation after three to four weeks.

At the time of the latest follow-up all the patient were evaluated both clinically and radiologically for final outcome. Antero-posterior and lateral radiographs were studied in terms of the following parameters which include volar tilt, radial inclination, radial length, and articular congruency. These films were compared with preoperative films and with previous follow-up films to assess the correction of the original deformity and to recognize any postoperative loss of reduction. The functional outcome of these patients were recorded and graded based on the modified clinical-scoring system of Green and O'Brien.¹⁰

Modified Clinical-Scoring System of Green and O'Brien		
Category	Score(Points)	Findings
Pain (25 points)	25	None
	20	Mild, occasional
	15	Moderate, tolerable
	0	Severe or intolerable
Functional status (25 points)	25	Returned to regular employment
	20	Restricted employment
	15	Able to work but unemployed
	0	Unable to work because of pain
Range of motion (25 points)	25	Percentage of normal 100
	15	75-99
	10	50-74
	5	25-49
	0	0-24
	25	Dorsiflexion-plantar flexion arc (injured hand only) 120° or more
	15	91°-119°
	10	61°-90°
	5	31°-60°
	0	30° or less
Grip Strength (25 points)	25	Percentage of normal 100
	15	75-99
	10	50-74
	5	25-49
	0	0-24
Final result		
Excellent	90-100	
Good	80-89	
Fair	65-79	
Poor	<65	

Table 2

ORIGINAL ARTICLE

RESULTS: Five patients at the end of one year had mild pain but they were able to return to their earlier jobs with unrestricted wrist movements and normal grip strength. These patients were grouped as excellent. Thirteen patients in addition to occasional pain had less than twenty five percent restriction of wrist movements compared to the opposite uninjured wrist but were able to return to their normal employment and hence given good rating. The wrist had mild pain in another five patients with reduced grip strength and restricted wrist movements more than fifty percent as compared to the normal side. These patients had to change job and showed a fair recovery of function. One patient developed surgical site infection which was managed with multiple debridements, plate removal with wrist spanning external fixator and finally ended up with stiff wrist and finger movements, occasional pain and paraesthesia along the course of median nerve which settled down with non-operative management and this patient got a poor outcome.

The latest follow-up radiographs showed a mean palmar tilt of 5°(Range, 5°- 12° dorsal to palmar), radial inclination averaged 18°(Range, 13° to 23°), mean radial shortening 1.5 mm (Range, 0–3mm), and articular congruity averaged 1mm.

The average duration of follow-up of these patients is eighteen months (Range, twelve–twenty four months). The mean time to radiological fracture healing was seven weeks (Range, six–eight weeks). None of the patient had tendon related problems.

Final Clinical Score as given in the modified Clinical-Scoring System of Green and O'Brien					
Case	Pain Score	Functional Status	Wrist ROM	Grip Strength	Final Result
1	20	25	25	25	95
2	20	25	15	25	85
3	20	25	15	25	85
4	20	25	25	25	95
5	20	25	15	25	85
6	20	25	15	25	85
7	20	25	15	25	85
8	20	25	25	25	95
9	20	20	10	15	65
10	20	25	15	25	85
11	20	20	10	15	65
12	20	25	15	25	85
13	20	25	15	25	85
14	20	20	10	15	65
15	20	25	25	25	95
16	20	20	10	15	65
17	20	25	15	25	85
18	20	25	15	25	85
19	20	20	10	15	65
20	20	25	15	25	85
21	20	25	15	25	85
22	15	15	10	10	50
23	20	25	25	25	95
24	20	25	15	25	85

Table 3

Final Radiological measurements				
Case	Palmar Tilt(Degrees)	Radial Inclination (Degrees)	Radial Shortening (mm)	Articular Congruity (mm)
1	10° palmar	23°	0	0
2	5° palmar	18°	0	0
3	8° palmar	20°	0	1
4	10° palmar	22°	0	0
5	8° palmar	18°	1	1
6	5° palmar	20°	0	0
7	5° palmar	18°	1	1
8	10° palmar	22°	0	0
9	3° dorsal	14°	1	1
10	8° palmar	16°	0	1
11	3° dorsal	18°	1	0
12	5° palmar	18°	1	0
13	8° palmar	20°	0	1
14	3° dorsal	16°	1	0
15	12° palmar	20°	0	0
16	0° neutral	18°	1	0
17	5° palmar	20°	0	1
18	5° palmar	18°	1	0
19	0° neutral	18°	1	1
20	5° palmar	20°	0	0
21	5° palmar	18°	0	0
22	5° dorsal	13°	3	1
23	12° palmar	22°	0	0
24	5° palmar	20°	0	0

Table 4

DISCUSSION: The treatment of fracture distal end of radius with the use of plating through a volar approach has been shown to give a good functional as well as a radiological outcome based on the results of various studies.^{6,11,12,13} Volar plating is simpler to perform due to relatively spacious flat volar anatomy of distal end of radius and it allows early restoration of wrist and finger movements. With proper placement of the distal screws late collapse and loss of palmar tilt can be minimised⁶. The use of low-profile volar plate, correct screw length along with repair of the pronator quadratus to brachiradialis aponeurosis lowers the incidence of late frictional tear of the flexor as well as the extensor tendons.^{11,14}

The results of this retrospective study are comparable with those reported by various authors in terms of early functional recovery and acceptable radiological parameters.^{3,6,11} The modified Green and O'Brien Score showed 5(21 Percent) excellent, 13(54 Percent) good, 5(21 Percent) fair, and 1(4 Percent) poor results at the latest follow-up. Arora, et al³ reported 31(27%) excellent, 54(47%) good, 23(20%) fair, and 6(5%) poor results in their multicenter study. Similarly, Drobetz et al⁶ had excellent in 23(46%), good in 11(22%), moderate in 12(24%) and poor in 4(8%) patients.

ORIGINAL ARTICLE

Except for one patient who developed surgical site infection that necessitated plate removal and conversion to a bridging external fixator, almost all of the patients included in this study had good relief of pain and were able to return to productive jobs.

The limitations of this study are small sample size and short duration of follow-up which may explain the absence of post-traumatic osteoarthritic changes in patients with intra-articular fractures as seen in studies with longer duration of follow-up.¹⁵

Volar plating is not the recommended for certain fractures of distal end of radius especially the B2 and C3 types.^{6,12,13}

Based on the results of this study and after reviewing relevant literatures, it was found that with proper selection of fracture types and using accurate surgical techniques, volar plating continues to be an useful method for treatment of fracture distal end of radius with minimal complications and at the same time allows the patient an early return to normal life.

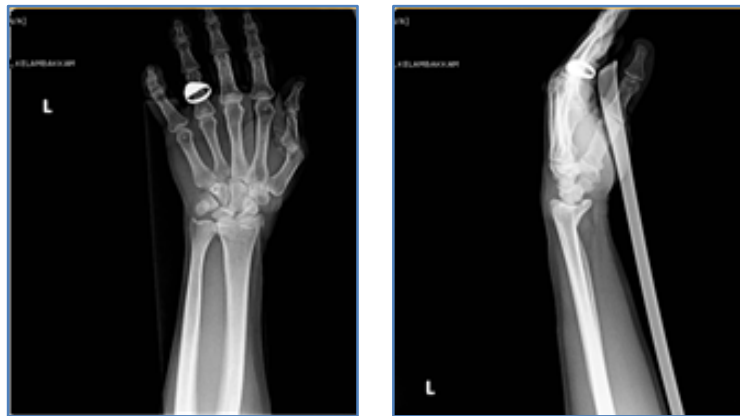
BIBLIOGRAPHY:

1. Colles, Abraham. "On the fracture of the carpal extremity of the radius." *The New England Journal of Medicine, Surgery and Collateral Branches of Science* 3.4 (1814): 368-372.
2. Egol, K. A., et al. "Distal radial fractures in the elderly: operative compared with non-operative treatment." *The Journal of Bone & Joint Surgery* 92.9 (2010): 1851-1857.
3. Arora, Rohit, et al. "A comparative study of clinical and radiologic outcomes of unstable colles type distal radius fractures in patients older than 70 years: non-operative treatment versus volar locking plating." *Journal of orthopaedic trauma* 23.4 (2009): 237-242.
4. Wolfe, S.W. *Green's Operative Hand Surgery*. 6th ed. Philadelphia: Churchill Livingstone, 2010, Print.
5. Ellis J. "Smith's and Barton's fractures: a method of treatment". *The Journal of Bone & Joint Surgery Br* 47 (1965): 724-727.
6. Drobotz, H., and E. Kutscha-Lissberg. "Osteosynthesis of distal radial fractures with a volar locking screw plate system." *International orthopaedics* 27.1 (2003): 1-6.
7. Rozental, Tamara D., and Philip E. Blazar. "Functional outcome and complications after volar plating for dorsally displaced, unstable fractures of the distal radius." *The Journal of hand surgery* 31.3 (2006): 359-365.
8. Chung, Kevin C., et al. "Treatment of unstable distal radial fractures with the volar locking plating system." *The Journal of Bone & Joint Surgery* 88.12 (2006): 2687-2694.
9. Constantine, Kostas J., Mark C. Clawson, and Peter J. Stern. "Volar neutralization plate fixation of dorsally displaced distal radius fractures." *Orthopedics* 25.2 (2002): 125-128.
10. Bradway, John K., Peter C. Amadio, and William P. Cooney. "Open reduction and internal fixation of displaced, comminuted intra-articular fractures of the distal end of the radius." *The Journal of Bone & Joint Surgery* 71.6 (1989): 839-847.
11. Orbay, Jorge L., and Diego L. Fernandez. "Volar fixation for dorsally displaced fractures of the distal radius: a preliminary report." *The Journal of hand surgery* 27.2 (2002): 205-215.
12. Wright, Thomas W., Mary Beth Horodyski, and Dean W. Smith. "Functional outcome of unstable distal radius fractures: ORIF with a volar fixed-angle tine plate versus external fixation." *The Journal of hand surgery* 30.2 (2005): 289-299.

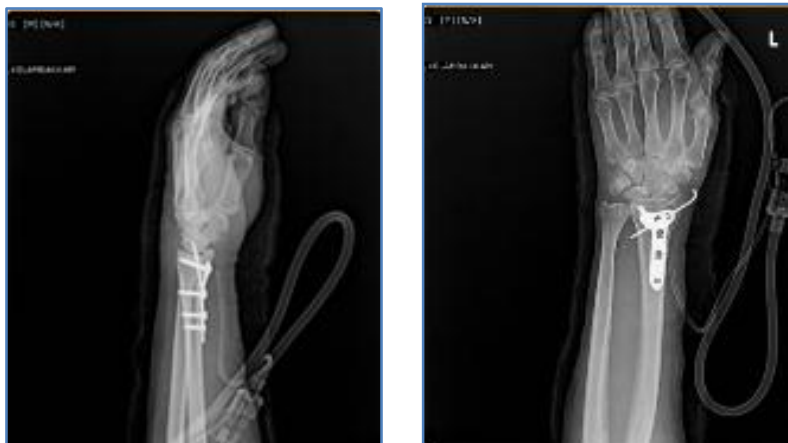ORIGINAL ARTICLE

13. Ruch, David S., and Anastasios Papadonikolakis. "Volar versus dorsal plating in the management of intra-articular distal radius fractures." *The Journal of hand surgery* 31.1 (2006): 9-16.
14. Bell, J. S. P., R. Wollstein, and N. D. Citron. "Rupture of flexor pollicis longus tendon A COMPLICATION OF VOLAR PLATING OF THE DISTAL RADIUS." *Journal of Bone & Joint Surgery, British Volume* 80.2 (1998): 225-226.
15. Knirk, Jerry L., and JESSE B. Jupiter. "Intra-articular fractures of the distal end of the radius in young adults." *The Journal of Bone & Joint Surgery* 68.5 (1986): 647-659.

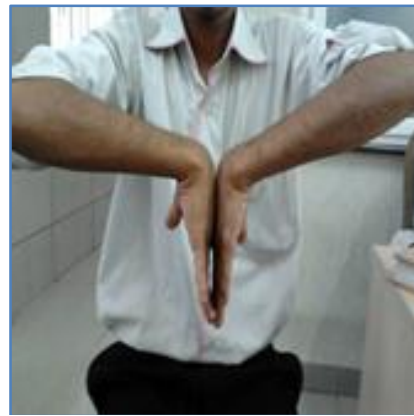CASE 1:



PRE OP

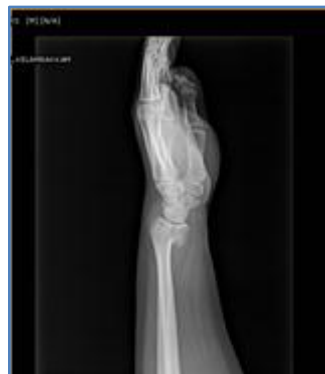
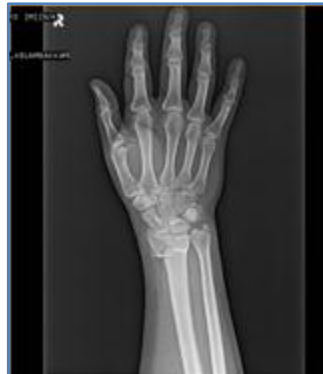
ORIGINAL ARTICLE

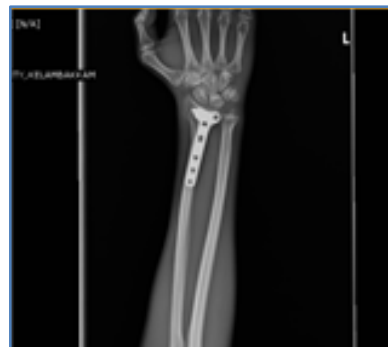

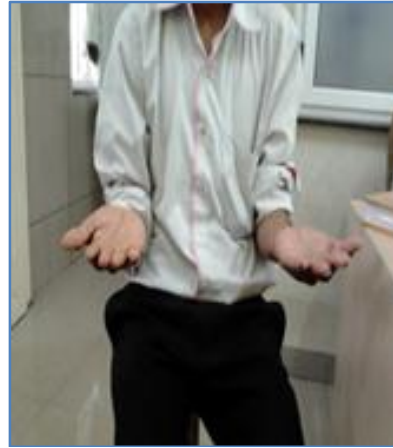POST OP

CASE 2:



PRE OP





POST OP

AUTHORS:

1. Victor Moirangthem
2. Bharat Kumar R. J.
3. Vijayanand R. R.
4. Narayana Reddy M.

PARTICULARS OF CONTRIBUTORS:

1. Associate Professor, Department of Orthopaedics, Chettinad Hospital & Research Institute.
2. Assistant Professor, Department of Orthopaedics, Chettinad Hospital & Research Institute.
3. Senior Resident, Department of Orthopaedics, Chettinad Hospital & Research Institute.

FINANCIAL OR OTHER

COMPETING INTERESTS: None

4. Professor & HOD, Department of Orthopaedics, Chettinad Hospital & Research Institute.

NAME ADDRESS EMAIL ID OF THE CORRESPONDING AUTHOR:

Dr. Victor Moirangthem,
3B, Staff Villas, Chettinad Hospital &
Research Institute, Rajiv Gandhi Salai,
Kelambakkam-603103,
Kanchipuram, Tamilnadu.
E-mail: victormoirangthem@gmail.com

Date of Submission: 08/06/2015.
Date of Peer Review: 09/06/2015.
Date of Acceptance: 22/06/2015.
Date of Publishing: 26/06/2015.