

CASE REPORT

PLEOMORPHIC SALIVARY ADENOMA OF SUBLINGUAL SALIVARY GLAND: A CASE REPORT

Diptanshu Mukherjee¹, Swagatam Banerjee², Sekhar Bandyopadhyay³, Saikat Mondal⁴,
S. N. Bandyopadhyay⁵

HOW TO CITE THIS ARTICLE:

Diptanshu Mukherjee, Swagatam Banerjee, Sekhar Bandyopadhyay, Saikat Mondal, S. N. Bandyopadhyay. "Pleomorphic Salivary Adenoma of Sublingual Salivary Gland: A case report". Journal of Evolution of Medical and Dental Sciences 2014; Vol. 3, Issue 72, December 22; Page: 15316-15319, DOI: 10.14260/jemds/2014/4061

ABSTRACT: INTRODUCTION: Pleomorphic adenoma (PA) is rarely seen in the submandibular gland and even more rarely in the sublingual gland. It is characterized by its pleomorphic or mixed appearance with clearly recognizable epithelial tissue intermingled with tissue of mucoïd, myxoid and chondroid appearance of glandular origin. We present a case of a pleomorphic adenoma of the sublingual salivary gland, which is quite rare. **CASE REPORT:** A 23 year old female presented with a painless swelling in the sublingual region for the last 1 year. Clinical examination revealed a 3cm x 4cm swelling in the submandibular region which was firm in consistency with a lobulated surface. FNAC was done from the swelling and it was diagnosed as a case of pleomorphic salivary adenoma. The patient was posted for surgery. After appropriate dissection, the swelling was identified and it was meticulously removed. Histopathological examination confirmed it as a case of pleomorphic salivary adenoma. **CONCLUSION:** Pleomorphic adenoma rarely affects the sublingual salivary gland. However, the differential diagnosis should always consider the possibility of such a tumour while evaluating a swelling in that region.

KEYWORDS: Salivary Gland Adenoma, Pleomorphic; Salivary Gland Diseases; Salivary Gland Neoplasms; Sublingual Gland.

MESH TERMS: Salivary Gland Adenoma, Pleomorphic; Salivary Gland Diseases; Salivary Gland Neoplasms; Sublingual Gland.

INTRODUCTION: Pleomorphic adenoma (PA) is the most common benign salivary gland neoplasm. As per medical literature, the parotid gland is the most commonly affected gland.^[1] However, it is rarely seen in the submandibular gland and even more rarely seen in the sublingual gland.^[2] Approximately 80-90% of the tumour of the sublingual salivary glands are malignant.^[1] Pleomorphic adenoma of the submandibular and sublingual gland is quite uncommon and comprises the remaining 8-10% of the tumours.^[3]

PA, as the name suggests, is characterized by its pleomorphic or mixed appearance with clearly recognizable epithelial tissue intermingled with tissue of mucoïd, myxoid and chondroid appearance of glandular origin. They usually present as a slowly growing, painless but firm swelling that does not cause ulceration of the overlying skin.

Although commonly seen in the parotid gland, they can also involve the submandibular, sublingual and even the minor salivary glands of the cheek, lips, palate, etc.^[4] Surgery is the mainstay of treatment and recurrence rate is very low in PA.^[1] We present a case of an asymptomatic swelling of the sublingual region which was later confirmed to be a case of a pleomorphic adenoma of the sublingual salivary gland.

CASE REPORT

CASE REPORT: A 23 year old female presented with a painless swelling in the sublingual region for the last 1 year (Fig 1). It was gradually increasing in size but not associated with any difficulty in chewing and salivation. Clinical examination revealed a 3cm x 4cm swelling in submandibular region which was firm in consistency with a lobulated surface. During bimanual palpation, it was felt to mimic a sublingual gland.

FNAC was done from the swelling and it was diagnosed as a case of pleomorphic salivary adenoma. A Computed Tomography (CT) scan of the swelling was done and it revealed a distinct homogeneous lesion of 2.8cm x3.5 cm size in the sublingual region with the mass extending inferiorly to the upper border of the hyoid bone. We opted for surgical excision of the mass by sublingual approach.

After appropriate dissection, the swelling was identified and it was meticulously removed so as to prevent damage to adjacent structures (Fig. 2). The wound was closed in layers and the postoperative recovery was uneventful.

The excised specimen was 2.5cm x 3cm in size (Fig 3). It was subsequently sent for histopathological examination which showed a large number of epithelial and myoepithelial type cells amidst a myxoid stroma suggestive of pleomorphic salivary adenoma. (Fig. 4)

DISCUSSION: Sublingual salivary gland pleomorphic adenomas have been rarely reported till now. Compared to the incidence of pleomorphic adenomas in the parotid gland, these are found in the ratio of about 1 per 100 parotid cases.^[5] Majority of the sublingual tumours are malignant in nature but few cases of PA and other tumours like oncocytoma and myoepitheliomas have also been reported.^[6] Sublingual benign tumours generally present as a swelling in the sublingual area as in our case but sometimes it may present as an intraoral mucosal lesion causing discomfort and pain during mastication.^[7] Sublingual salivary gland tumours may mimic lesions like lymphoma, retention cyst, sialolithiasis, sialoadenitis, etc. because they produce a similar type of swelling. Dermoid cyst and lipoma which are much more common in the sublingual region than PA may cause confusion regarding the clinical diagnosis.

Fine needle aspiration cytology (FNAC) is the initial investigation of choice in sublingual PA because incisional biopsy can lead to seeding of tumour cells in surrounding tissue. Fine needle aspiration biopsy and frozen biopsy would be better in a suspected case of PA because the typical histological pattern is often absent on fine needle aspiration cytology. Confirmation of diagnosis of PA can only be done after proper histopathological examination of the excised tumour.^[4,6] In our case, an FNAC was done and it showed the tumour to be suggestive of a pleomorphic salivary adenoma. Subsequently, the tumour was confirmed as a pleomorphic salivary adenoma on histopathological examination.

Treatment of choice in submandibular gland tumours is surgical excision. Tumour free margins need to be obtained to avoid recurrence, especially in cases of pleomorphic adenomas.^[8] In case of malignancy, if nodes are palpable, concomitant selective neck dissection has to be carried out. Meticulous dissection needs to be done in malignant cases as the tumour may be adherent to the surrounding lingual vessels and hypoglossal nerve. In our case, a meticulous dissection was carried out but the tumour was well encapsulated and not adherent to surrounding nerves and vessels.

CASE REPORT

CONCLUSION: Pleomorphic adenoma rarely affects the sublingual salivary gland. However, the differential diagnosis should always consider the possibility of such a tumour while evaluating a swelling in that region.

REFERENCES:

1. Eneroth CM. Salivary gland tumors in the parotid gland, submandibular gland, and the palate region. *Cancer*. 1971; 27(6):1415-8.
2. Okura M, Hiranuma T, Shirasuna K, Matsuya T: Pleomorphic adenoma of the sublingual gland: report of a case. *J Oral Maxillofac Surg* 1996; 54: 363–366.
3. Nagler RM, Laufer D: Tumors of the major and minor salivary glands: review of 25 years of experience. *Anticancer Res* 1997; 17: 701–707.
4. Vicente OP, Marqués NA, Aytés LB, Escoda CG. Minor salivary gland tumors: a clinicopathological study of 18 cases. *Med Oral P Patol Oral Cir Bucal*. 2008 Nov; 13(9): 582-8.
5. Zdanowski R, Dias FL, Barbosa MM, Lima RA, Faria PA, Loyola AM, Souza KCN: Sublingual gland tumors: clinical pathologic and therapeutic analysis of 13 patients treated in a single institution. *Head Neck* 2011; 33: 476–481.
6. Eveson JW, Cawson RA: Salivary gland tumors: a review of 2, 410 cases with particular reference to histopathological types, site, age and sex distribution. *J Pathol* 1985; 146: 51–58.
7. Rinaldo A, Shaha EA, Pellitteri PK, Bradley, Ferlito A: Management of malignant sublingual salivary gland tumors. *Oral Oncol* 2004; 40: 2–5.
8. Simpson RHW. Myoepithelial tumours of the salivary glands. *Curr Diagn Pathol* 2002; 8: 328.
9. Rapidis AD, Stavrianos S, Lagogiannis G, Faratzis G. Tumors of the submandibular gland: clinicopathologic analysis of 23 patients. *J Oral Maxillofac Surg* 2004; 62: 1203.
10. Sun G, Yang X, Tang E, Wen J, Lu M, Hu Q: The treatment of sublingual gland tumours. *Int J Oral Maxillofac Surg* 2010; 39: 863–868.

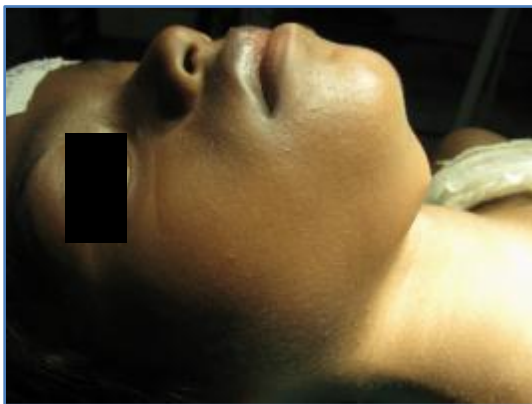

Fig. 1

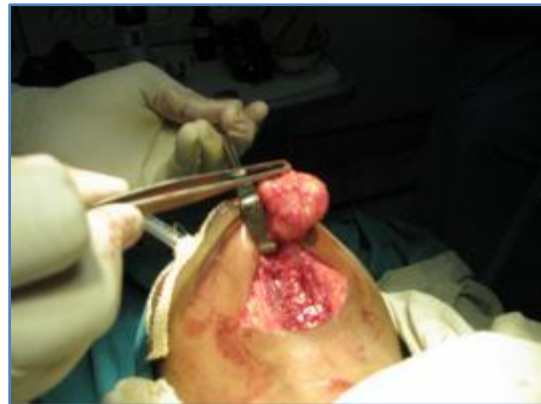

Fig. 2

CASE REPORT

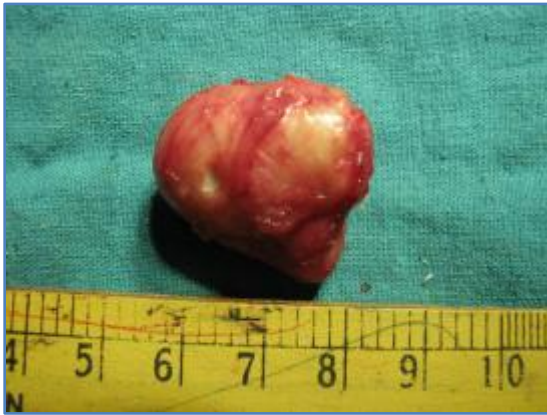

Fig. 3

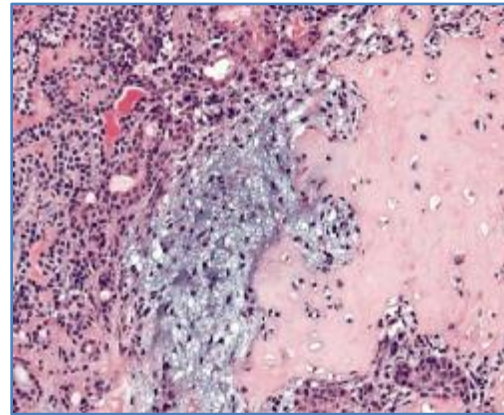


Fig. 4

AUTHORS:

1. Diptanshu Mukherjee
2. Swagatam Banerjee
3. Sekhar Bandyopadhyay
4. Saikat Mondal
5. S. N. Bandyopadhyay

PARTICULARS OF CONTRIBUTORS:

1. RMO-Cum-Clinical Tutor, Department of ENT, Medical College, Kolkata.
2. Senior Resident, Department of ENT, Medical College, Kolkata.
3. Medical Officer, Department of ENT, North Bengal Medical College.
4. Junior Resident, Department of Pathology, Medical College, Kolkata.

5. Professor, Department of ENT, Medical College, Kolkata.

NAME ADDRESS EMAIL ID OF THE CORRESPONDING AUTHOR:

Dr. Diptanshu Mukherjee,
Department of ENT,
Medical College,
88, College Street,
Kolkata-700073.
Email: dipe_medico@rediffmail.com

Date of Submission: 11/12/2014.
Date of Peer Review: 12/12/2014.
Date of Acceptance: 17/12/2014.
Date of Publishing: 22/12/2014.