

**FUNCTIONAL AND RADIOLOGICAL OUTCOME OF DISTAL FEMORAL FRACTURES TREATED WITH LOCKING COMPRESSION PLATE**Muktevi Sreedhar<sup>1</sup>, M. E. Luther<sup>2</sup>, B. Anudeep<sup>3</sup>, Prashanth<sup>4</sup>, Swaroopa<sup>5</sup>, Venu Madhav<sup>6</sup>**HOW TO CITE THIS ARTICLE:**

Muktevi Sreedhar, M. E. Luther, B. Anudeep, Prashanth, Swaroopa, Venu Madhav. "Functional and Radiological outcome of Distal Femoral Fractures Treated with Locking Compression Plate". Journal of Evolution of Medical and Dental Sciences 2015; Vol. 4, Issue 38, May 11; Page: 6664-6671, DOI: 10.14260/jemds/2015/964

**ABSTRACT: AIM:** To evaluate the clinical and radiological outcome in the management of distal femur fractures treated by distal femoral locking compression plate. **BACKGROUND:** Distal femur fractures are one of the common fractures occurring in road traffic accidents. Different treatment modalities with varying outcomes are seen in literature in the management of these fractures. **MATERIALS & METHODS:** The study was conducted in the department of orthopaedics at the Kamineni Institute of Medical sciences Narketpally. Patients treated for distal femur fractures with ORIF using distal femoral locking compression plates were evaluated to assess their clinical and functional results using Neer's scoring system and compared with the available literature. **RESULTS:** The mean time for union was 20 wks. With mean time to full weight bearing being 10.5 wks. **CONCLUSION:** Surgery in the form of ORIF with distal femoral locking compression plate for Distal femur fracture is a comparatively good treatment option for better out come and early mobilization with minimum complications.

**KEYWORDS:** Distal femur fractures, Neer's scoring system.

**INTRODUCTION:** Distal femoral fractures reportedly account for less than 1% of all fractures and comprise between 4%–6% of all femoral fractures. Supra condylar femoral fractures occur commonly among two populations, young patients involved in high-energy accidents (Including motor vehicle and motorcycle accidents and sports trauma) and older patients, often osteoporotic, sustaining low-energy fall fractures.<sup>1</sup> Intra-articular fractures of distal femur present a huge surgical challenge. These fractures are difficult to treat and surgical treatment is usually recommended for favourable outcome as they are frequently comminuted and intra-articular.<sup>2</sup>

As orthopaedic surgery has evolved, trends in treatment of supra-condylar and inter-condylar femoral fractures now more commonly involve varied operative management techniques. The goals of surgical treatment are anatomical reconstruction of the articular surfaces, reduction of the metaphyseal component of the fracture to the diaphysis, restoration of normal axial alignment, length and rotation, stable internal fixation, early mobilisation and functional rehabilitation of the limb.<sup>3</sup>

Internal fixation devices that have been used to treat these fractures include the 95° angled blade plate, dynamic condylar screw plate, condylar buttress plate and retrograde supra-condylar inter-locking nail. However, as the complexity of fractures has changed from simple extra-articular supra-condylar types to inter-condylar and metaphyseal comminuted types, these implants may not be ideal. Double plating, and more recently, locked plating techniques have been advocated. However, with double plating, there is often extensive soft tissue stripping on both sides of the femur, resulting in reduced blood supply and potential non-union and failure of the implants. The Less Invasive Stabilization System (LISS) allows for fixed angle fixation of the distal femur and minimally invasive fixation of the femoral shaft.

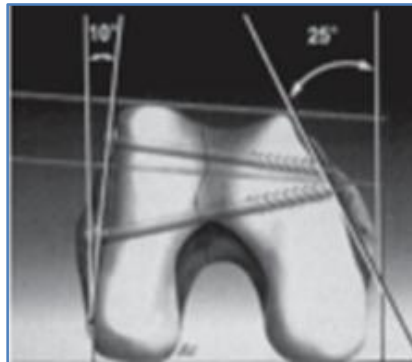
## ORIGINAL ARTICLE

However, there has been concern that the implant may be too stiff, and when associated with premature weight bearing by the patient, results in ultimate failure of the implant. Distal femoral locking compression plate (DF-LCP) has a smaller application device and allows both locking and compression screw fixation of the femur shaft.

This study was conducted to examine the short term results of clinical, Radiological, functional and healing rate of distal femoral fractures treated with distal femoral locking compression plate. The introduction of locking plates with fixed-angle screws has improved the fixation strength of plate constructs and they are frequently indicated for bridge plating of comminuted fractures.<sup>4</sup>

**SURGICAL ANATOMY:** Supracondylar region of femur represents the metaphyseal transition between the femoral diaphysis and distal femoral articular surface. For the convenience of description, the supracondylar region has been defined as the distal 9cm of the femur.<sup>5</sup> The other important characteristic of this area include the anteriorly located trochlea for patellar articulation and the posterior intercondylar notch. When viewed in cross-section the distal femur appears trapezoidal, with the medial side showing 25 degree decrease in width from posterior to anterior and 10 degree on lateral side. [Fig. 1]

Following fracture, shortening occurs with the distal articular segment assuming a varus and extension position. The shortening is caused by the pull of quadriceps and hamstring. Varus and extension deformity results from the unopposed pull of adductors and gastronemius respectively.



**Fig. 1: Distal femoral surgical anatomy**

**MATERIALS AND METHODS:** The present study was conducted in the Department of Orthopaedics, Kamineni Institute of Medical Sciences, Narketpally on patients operated during the period from March 2011 to Dec. 2014.

**Study Design:** Prospective study

**Sample Size:** 30 patients with for distal femur fractures with supracodylar and intra-articular extension who underwent operative procedure from March 2011 to December 2014 were selected for the study.

**SELECTION CRITERIA:**

**Inclusion Criteria:** All patients with age above 18 years having supracondylar and intercondylar fractures of femur with an indication for surgical management and without any proposed contraindications for surgical management.

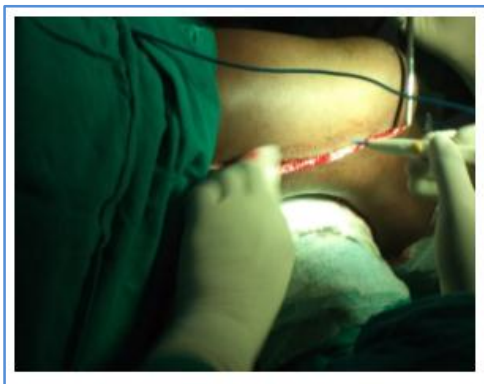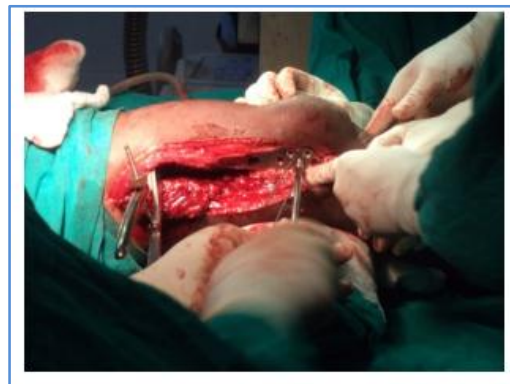**Exclusion Criteria:**

- Pathological fracture.
- Patients treated conservatively.
- Compound fractures.
- Patients who were bed ridden or non-ambulatory.
- Patients with severe life threatening medical problems.

**SURGICAL TECHNIQUE:** All Patients were operated under combined spinal and epidural anaesthesia. Patients were placed in supine position on operating table slightly elevating the affected side with a sandbag under ipsilateral hip. Skin at the operating site was prepared by povidone iodine (10% w/v) solution and spirit and the operating field from the buttock to the knee was draped. Fracture site was approached through a lateral incision (Fig. 2). After skin incision deep fascia, iliotibial band and vastus lateralis was split in layers till the fracture site was exposed and reduction of fracture is maintained with bone clamps. (Fig. 3)

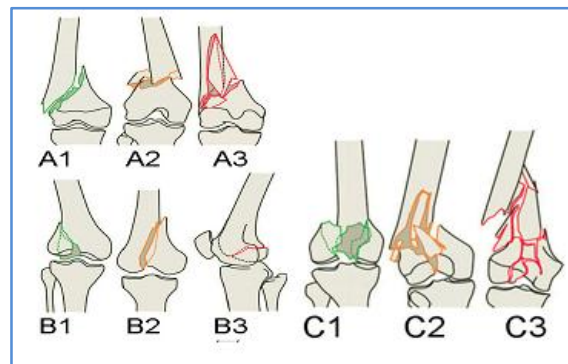
The appropriate chosen sized plate depending upon fracture pattern was placed into position and stabilized with bone clamp or reduction forceps. Then rigid fixation was achieved by insertion of variable number of locking screws which were inserted after drilling the bone through the plate and bone surface by motorized drill under c-arm guidance. The skin wounds were closed over a negative suction drain after thorough washing with copious amount of sterile saline solution and sterile dressings applied over the limb. During this time passive and active movements of toes were encouraged. Patients received prophylactic anti biotics was administered as per hospital protocol postop analgesia was administered as per hospital protocol. Anti-inflammatory analgesics and other supportive measures were also given as per individual requirements. The suction drain was removed after 48 hrs and check x-ray (AP/Lat) of the limb was taken. (Fig. 6)

Patients were allowed to sit out of bed once the drain was removed. Knee range of movements and active quadriceps and hamstring exercises were started, as soon as patient could tolerate pain from immediate post-operative day and non-weight bearing started with help of walker. Skin suture were removed on the tenth post-operative day. Patient discharged with appropriate post-operative instructions.

**Fig. 2: Surgical incision****Fig. 3: Plate fixation**

## ORIGINAL ARTICLE

**CLASSIFICATION:** The Muller AO classification (Fig. 4) is the most widely used system to categorise distal femoral fractures. Various other classification systems by Neer, Seinsheimer, and Egund and Kolmert have been proposed as well, but these did not prevail. Moreover the AO classification unanimously has gained acceptance for distal femoral fractures. According to the common principles of the AO classification, type A fractures are extra-articular and type B fractures are partial articular, which means that parts of the articular surface remains in contact with the diaphysis. Type C fractures are complete articular fractures with detachment of both condyles from the diaphysis. The fracture types are further subdivided describing the degree of fragmentation and other, more detailed characteristics. Further subdivision of type B fractures includes B1 (sagittal, lateral condyle), B2 (Sagittal, medial condyle) and B3 (Frontal, Hoffa type). Fracture type C is divided in C1 (Articular simple, metaphyseal simple), C2 (articular simple, metaphyseal multifragmentary) and C3 (Multifragmentary).<sup>6</sup>



**Fig. 4: Muller AO classification**

**RESULTS:** Thirty patients of distal femur fracture were subjected to open reduction and internal fixation using locking compression plate between March 2011 to Dec 2014, in the department of orthopaedics, Kamineni institute of medical sciences, Narketpally. Scoring is assessed according to Neers scoring.<sup>7</sup> Out of 30 patients 19(67%) were males and 11(33%) were females (Table 1). The youngest patient was 18yrs old and the oldest 79 yrs (Table 2). About 73% patients had sustained road traffic accidents, remaining 27% had sustained a fall from height (Table 3). The average duration of weight bearing 10.5 weeks (Table 5). Average time for fracture healing was 20 weeks (Table 4). Average range of motion of knee was 102.8 degrees (Table 6) (Fig. 8, 9, 10). Among 30 patients there were 21(70%) excellent result, 6(20%) good results, 3(10%) had fair results. (Table 7)

**Follow up protocol:** Post-operative follow-ups were done at the end of 6, 10, 14 wks of surgery.

Age (year)	Total	
	No.	Percentage (%)
0-20	4	12%
22-40	14	47%
41-60	10	35%
61-80	2	6%

**Table 1: Age Distribution**

## ORIGINAL ARTICLE

Sex	No. of patients	Percentage (%)
Male	19	67%
Female	11	33%

**Table 2: Sex Distribution**

Mechanism of Injury	No. of case	Percentage (%)
Road traffic accident	21	73%
Fall from height	9	27%
<b>Total</b>	<b>30</b>	<b>100%</b>

**Table 3: Mechanism of injury**

Union (weeks)	No. of cases	Percentage
<16	0	
End of 20	12	40%
End of 24	18	60%

**Table 4: Time of union**

Achieved time(weeks)	No. of cases	Percentage
8-10	8	24%
>10-12	22	76%

**Table 5: Time at which full weight bearing achieved**

Knee flexion(degree)	No. of case	Percentage (%)
>90	3	10%
91-109	12	40%
>110	15	50%

**Table 6: Knee flexion (end of 24 weeks)**

Rating	No. of case	Percentage (%)
Excellent >85 points	21	70%
Good 70-84 points	6	20%
Fair 50-69 points	3	10%
Poor <50 points	0	0

**Table 7: Function rating as per Neer's rating score**

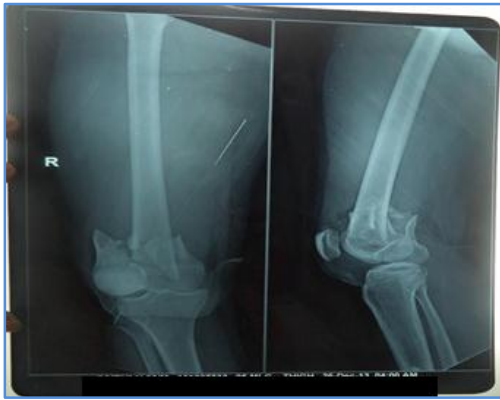

Fig. 5: Pre op x-ray

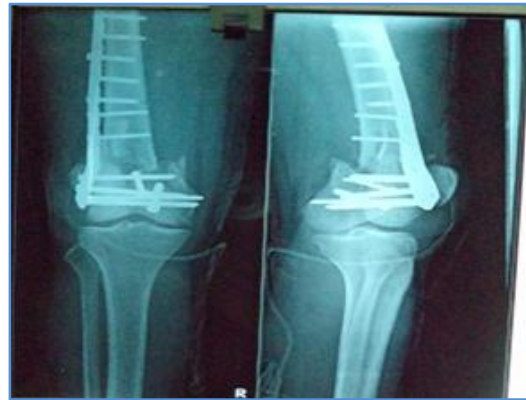

Fig. 6: Immediate post op x-ray

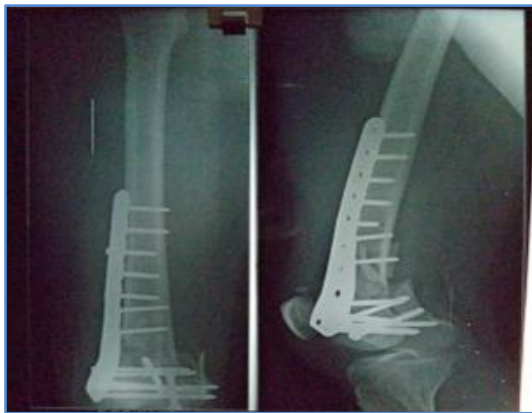

Fig. 7: Post op x-ray 6 months

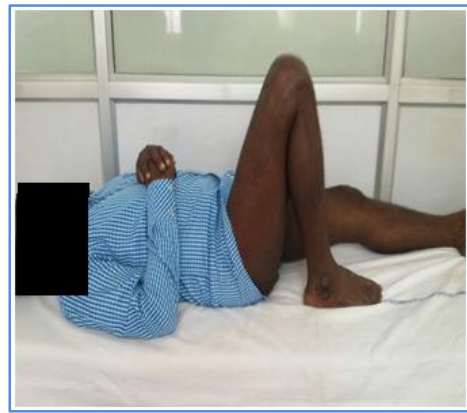

Fig. 8: Knee flexion in supine position 120° at the end of 24 wks

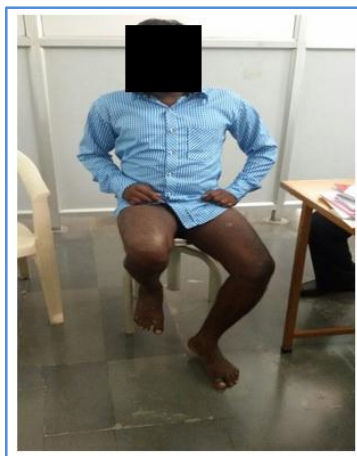

Fig. 9: Knee flexion in sitting position 130°

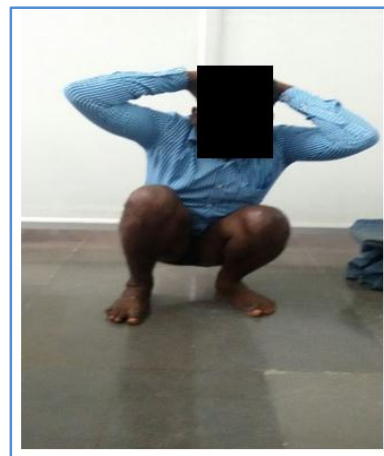


Fig. 10: Squatting 120°

## ORIGINAL ARTICLE

---

**COMPLICATIONS:** Complications included delayed union in three patients, superficial infection in one patient, knee pain in two patients and knee stiffness in five patients.

**DISCUSSION:** Current fracture patterns were towards complex comminuted types possibly due to the prevalence of high speed vehicle accidents. Improved healthcare results in a longer lifespan and subsequently presents us with more osteoporotic fractures which were previously treated using conservative methods. The LCP is a single beam construct where the strength of its fixation is equal to the sum of all screw-bone interfaces rather than a single screw's axial stiffness and pullout resistance in unlocked plates. Its unique biomechanical function is based on splinting rather than compression resulting in flexible stabilisation, avoidance of stress shielding and induction of callus formation.

When applied via a minimally invasive technique, it allows prompt healing, lower rates of infection and reduced bone resorption as blood supply is preserved.<sup>8</sup>

The LCP acts on the internal fixator principle as screws once locked to the plate do not pull the fracture towards the implant, and hence there is no displacement of the fracture once reduced.<sup>9</sup>

The disadvantages of first-generation locked plates include the uniaxial screw trajectories.

These screws trajectories cannot account for differences in femoral anatomy, fracture patterns or variations in plate positioning. In recent studies, biomechanical characteristics of a polyaxial system were analysed in comparison with uniaxial first generation locking plates. Despite the large forces applied, there were no failures of the polyaxial screw-plate interface and screw angle did not reduce the overall strength of these constructs, hence lending support to the biomechanical effectiveness of polyaxial plate designs under axial loading.<sup>10</sup>

**CONCLUSION:** The results of this observational study indicate that a polyaxial locking plate offers clinical and radiographic outcomes superior to those treated with fixed-trajectory locking plates but with greater fixation versatility. The system provides a high degree of angular and axial stability in a series of complex distal femoral fractures.

### REFERENCES:

1. Martin F Hoffmann, Clifford B Jones, Debra L Sietsema, Paul Tornetta III and Scott J Koenig. Clinical Outcomes of Locked Plating of Distal Femoral Fractures In A Retrospective Cohort. *Journal of Orthopaedic Surgery and Research*.2013; 8: 43.
2. G. N. Kiran Kumar, Gaurav Sharma Kamran Farooque, Vijay Sharma, Ratnav Rattan, Sanjay Yadav, and Devandra Lakhotia . Locking Compression Plate in Distal Femoral Intra Articular Fractures: Our Experience. *International Scholarly Research Notice*. 2014; 1-5.
3. M. Agunda, L. N. Gakku, and G. K. Museve. Early Functional Outcome of Distal Femoral Fractures at Kenyatta National Hospital and Kikuyu Hospital. *East African Orthopaedic Journal*. 2013; 7: 57-60.
4. Trevor J. Lujan, Chris E. Henderson, Steven M. Madey, Dan C. Fitzpatrick, J. Lawrence Marsh, and Michael Bottlang. Locked Plating of Distal Femur Fractures Leads to Inconsistent and Asymmetric Callus Formation. *J Orthop Trauma*.2010; 24: 156-162.
5. Yuvarajan P, Rahul Kaul, Lalit Maini. Review of Concepts in Distal Femoral Fractures Management. *Pb Journal of Orthopaedics*.2009; 9(1): 44-47.

## ORIGINAL ARTICLE

6. D. C. Link, R. Babst. Current Concepts in Fractures of the Distal Femur. *Acta Orthopaedic*.2012; 79:11-20.
7. Shiblee S. Siddiqui, Johnny Bharath Joshi, Ravish Patel And Vishal Dindod. Functional Out Come Of Distal Femur Fracture With Intra Articular Extension. *International Journal of Biomedical Research*.2014; 5(11): 673-676.
8. Ej Yeap, AS Deepak. Distal Femoral Locking Compression Plate Fixation in Distal Femoral Fractures: Early Results. *Malaysian Orthopaedic Journal*.2007; 12-17.
9. Dhanasekaraprabu, Rajesh Chandra. Results in Distal Femoral Fractures after Fixation with A Locking Compression Plate In A Level 1trauma Center In India. *Journal of Young Medical Researchers*.2013; 1(1).
10. R. Pascarella, C. Bettuzz, G. Bosco, D. Leonetti, S. Dessi, P. Fort, L. Amendola. Results in Treatment of Distal Femur Fractures Using Polyaxial Locking Plate. *Start Trauma Limb Recon*. 2014; 9:13-18.

### AUTHORS:

1. Muktevi Sreedhar
2. M. E. Luther
3. B. Anudeep
4. Prashanth
5. Swaroopa
6. Venu Madhav

### PARTICULARS OF CONTRIBUTORS:

1. Assistant Professor, Department of Orthopaedics, Kamineni Institute of Medical Sciences, Narketpally, Nalgonda.
2. Professor & HOD, Department of Orthopaedics, Kamineni Institute of Medical Sciences, Narketpally, Nalgonda.
3. Post Graduate, Department of Orthopaedics, Kamineni Institute of Medical Sciences, Narketpally, Nalgonda.

### FINANCIAL OR OTHER

**COMPETING INTERESTS:** None

4. Post Graduate, Department of Orthopaedics, Kamineni Institute of Medical Sciences, Narketpally, Nalgonda.
5. Post Graduate, Department of Orthopaedics, Kamineni Institute of Medical Sciences, Narketpally, Nalgonda.
6. Post Graduate, Department of Orthopaedics, Kamineni Institute of Medical Sciences, Narketpally, Nalgonda.

### NAME ADDRESS EMAIL ID OF THE CORRESPONDING AUTHOR:

Dr. Muktevi Sreedhar,  
Assistant Professor,  
Department of Orthopaedics,  
Kamineni Institute of Medical Sciences,  
Narketpally, Nalgonda, Telangana.  
E-mail: drmuktevi@gmail.com

Date of Submission: 25/04/2015.  
Date of Peer Review: 26/04/2015.  
Date of Acceptance: 01/05/2015.  
Date of Publishing: 09/05/2015.