

## CLINICOPATHOLOGICAL ASPECTS OF HODGKIN LYMPHOMA IN A SOUTH INDIAN CITY

Nidhish Kumar<sup>1</sup>, Radha Ram Pai<sup>2</sup>, Prachi Bhageria<sup>3</sup>, Kausalya Kumari Sahu<sup>4</sup>

<sup>1</sup>Post Graduate Student, Department of Pathology, Kasturba Medical College, Mangalore.

<sup>2</sup>Professor, Department of Pathology, Kasturba Medical College, Mangalore.

<sup>3</sup>Under Graduate Student, Department of Pathology, Kasturba Medical College, Mangalore.

<sup>4</sup>Professor, Department of Pathology, Kasturba Medical College, Mangalore.

### ABSTRACT

Hodgkin Lymphoma (HL) is a malignant disease of B lymphocyte, characterized by the presence of diagnostic Reed-Sternberg cells in an appropriate cellular microenvironment WHO (2008) classification consists of Nodular Lymphocyte Predominant (NLP) and classical Hodgkin Lymphoma (cHL). It has a bimodal age distribution, more common in males. In developed countries, Nodular Sclerosis (NS) - cHL is more common in females as compared to other types. Newer insight into biology of tumour classifies NS-cHL as a distinct entity, while Mixed Cellularity (MC) - cHL and Lymphocyte Depleted (LD) - cHL are part of the same biologic spectrum. Lymphocyte Rich (LR) - cHL mimics NLP in morphology and Immunohistochemistry (IHC) is crucial for diagnosis.

### PURPOSE

We aim to correlate the differences of clinicopathological features of HL with subtypes of HL.

### METHODS

It is a retro-prospective study which included 30 cases, diagnosed and confirmed with IHC, as HL in the Department of Pathology, Kasturba Medical College, Mangalore.

### RESULTS

We found that NS-cHL was the most common (15 cases) followed by MC-cHL and LD-cHL, which were equal in number (5 cases) and then LR-cHL (3 cases). There were no cases of NLP in our study. Mean age for NS-cHL, MC-cHL, LD-cHL and LR-cHL were 25 yrs., 30.5 yrs., 61.5 yrs. and 33 yrs. respectively. M:F ratio for NS-cHL and MC-cHL was 1.5:1 for LR-cHL it was 1:2 and LD was seen only in males. NS-cHL commonly involved lymph nodes above diaphragm and MC-cHL involved a single lymph node region. LR-cHL presented in early stages with no mediastinal involvement. LD-cHL presented mostly in stage III (75%) with generalized lymphadenopathy.

### CONCLUSIONS

We concluded that NS-cHL showed male predominance similar to other subtypes in our study unlike in developed countries where more females are affected. LD-cHL was distinctively seen in males, older age and as high-stage disease.

### KEYWORDS

Hodgkin Lymphoma (HL), Immunohistochemistry (IHC), Classical Hodgkin Lymphoma (CHL), Nodular Sclerosis (NS), Mixed Cellularity (MC), Lymphocyte Rich (LR), Lymphocyte Depleted (LD).

**HOW TO CITE THIS ARTICLE:** Kumar N, Pai RR, Bhageria P, et al. Clinicopathological aspects of Hodgkin lymphoma in a South Indian city. *J. Evolution Med. Dent. Sci.* 2016;5(58):3976-3979, DOI: 10.14260/jemds/2016/910

### INTRODUCTION

Hodgkin Lymphoma (HL) is a malignant disease of B lymphocytes characterized by the presence of diagnostic Reed Sternberg (RS) cells and its variants within an appropriate inflammatory milieu. Based on the morphology, phenotype, genotype and clinical presentation the latest WHO classification (2008) is Nodular Lymphocytic Predominant (NLP) HL and classical HL (cHL).<sup>(1)</sup> The classification is accepted worldwide and classical HL was considered as a biological continuum.<sup>(2)</sup> With advances in understanding of the spectrum and biology of HL, recent evidence suggests Nodular

Sclerosis (NS) - cHL may be related to primary mediastinal B-cell Lymphoma and mediastinal grey zone lymphoma and needs to be classified as a distinct entity.<sup>(3)</sup> This study attempts to compare the different subtypes of cHL with respect to demographics and clinical presentation.

### MATERIALS AND METHODS

This study is retrospective to prospective and included 30 cases of immunohistochemically confirmed HL received in the Department of Pathology, Kasturba Medical College (KMC), Mangalore, from January 2011 to June 2015. The clinical details which includes age, gender, lymph node site involved B-symptoms, splenohepatomegaly and mediastinal involvement were retrieved from the medical records of KMC Hospital, Attavar, Ambedkar Circle and Govt. Wenlock Hospital. The diagnosis was based on excision lymph node biopsy in 28 cases and core biopsy in 2 cases. Histopathologically diagnosed cases of HL that were confirmed by Immunohistochemistry (IHC) with CD 30, CD 15, LCA, CD 20 and CD 3 were included in the study. Cases of HL where IHC was not done were excluded.

*Financial or Other, Competing Interest: None.*

*Submission 12-06-2016, Peer Review 06-07-2016,*

*Acceptance 12-07-2016, Published 19-07-2016.*

*Corresponding Author:*

*Dr. Nidhish Kumar,*

*Flat No. 302, Aimaan Residency,*

*B. V. Road, Opposite Kidzee School,*

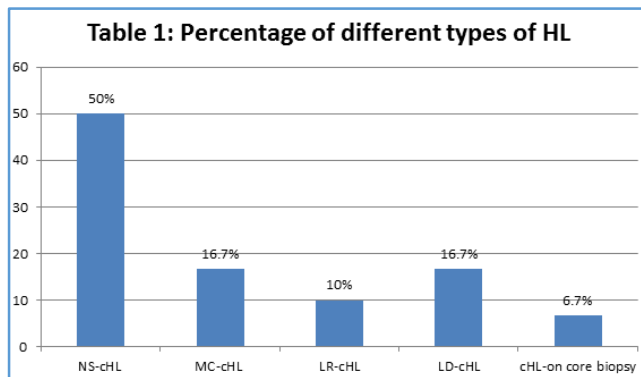
*Attavar, Mangalore-575001,*

*Karnataka.*

*E-mail: nidhishsingh7@gmail.com*

*DOI: 10.14260/jemds/2016/910*

**RESULTS**



Thirty cases of HL confirmed by IHC were included in this study, among which NS-cHL was the most common (15 cases, 50%) followed by Mixed Cellularity (MC) - cHL and Lymphocyte Depleted (LD) - cHL, which were equal in number (5 cases each, 16.7%) and then Lymphocyte rich (LR) - cHL (3 cases, 10%). There were no cases of NLPHL in our study. Two cases could not be classified as they were diagnosed on core needle biopsy.

Mean age for NS was 25 yrs. MC-cHL, LD-cHL and LR-cHL subtypes showed mean age of 30.5 years, 61.5 years and 33 years respectively. M:F ratio for NS-cHL and MC-cHL was 1.5:1, for LR-cHL it was 1:2 and LD-cHL was seen only in males.

NS-cHL commonly involved lymph nodes above diaphragm. MC-cHL involved a single lymph node region. LR-cHL presented with more disseminated disease. LD-cHL presented mostly in stage III (75%) with generalized lymphadenopathy.

Eight cases showed mediastinal involvement, out of which 6 (75%) were of NS-cHL. One (12.5%) case was of LD-cHL and 1 (12.5%) of cHL, which was diagnosed on core biopsy.

Splenohepatomegaly was seen in 6 cases of HL, out of which 3 (50%) cases were of NS-cHL. Two (33.3%) were LD-cHL and 1 (16.7%) was cHL diagnosed on core biopsy.

Disease stage by Ann Arbor criteria for NS-cHL patients was stage II in 8 patients (53%), stage I and stage III in 3 cases each (20% each) and 1 in stage IV (6.7%). In MC-cHL, 4 patients (80%) presented in early stage (stage I, IIa). Four cases (80%) of LD-cHL presented in stage III. LR-cHL presented equally in stage I, II, III (33.3%).

M:F	NS-cHL (n=15)		MC-cHL (n=5)		LD-cHL (n=5)		LR-cHL (n=3)	
	1.5:1		1.5:1		All males(5)		1:2	
Mean Age	25 yrs.		30.5 yrs.		61.5 yrs.		33 yrs.	
Lymphadenopathy	NS		MC		LD		LR	
	No. of Patients	%	No. of Patients	%	No. of Patients	%	No. of Patients	%
Multiple area & multiple nodes on both sides of diaphragm	5	33.3	1	20	4	80	2	66.7
Multiple area and multiple nodes on one side of diaphragm	8	53.3	0	0	1	20	1	33.3
Single area with multiple nodes	2	13.3	4	80	0	0	0	0
B symptoms	5	33.3	0	0	4	80	1	33.3
Mediastinal mass	6	40	0	0	1	20	0	0
Elevated ESR	12	80	3	60	5	100	2	66.7
<b>Organ Involvement</b>								
B.M.	0	0	0	0	0	0	0	0
Splenohepatomegaly	3	20	0	0	2	40	0	0

**Table 2: Clinical Aspects of 30 Cases of HL**

IHC	NS		MC		LD		LR	
	No. of Patients	%	No. of Patients	%	No. of Patients	%	No. of Patients	%
CD15 (+ve)	10	66.7%	0	0	2	40	3	100
CD30 (+ve)	15	100	5	100	5	100	3	100
CD45 (-ve)	15	100	5	100	5	100	3	100
CD20 (+ve)	5	33.3%	2	40	0	0	0	0

**Table 3: Immunohistochemistry**

All 30 cases were CD 30 positive showing membrane, cytoplasmic and golgi positivity. All 30 cases were CD 45 negative. Five cases of NS-cHL showed focal positivity of CD 20 in RS cells and 2 cases of MC-cHL were CD 20 positive. CD 15 was positive in 17 cases (56%) and was found to be statistically significant (p<0.015) in sub-typing of cHL. CD 15% enabled a correct diagnosis of all cases of LR-cHL.

Eleven (73.3%) out of 15 cases of NS-cHL were in the age group of 21-40 years. Five cases of MC-cHL showed a bimodal peak with 2 cases in age group 20 and below and 3 cases in 41-60 years' age group. Cases of LR-cHL were seen equally

distributed from age 0-60 years, while LD-cHL was seen in older age group. Out of 5 cases of LD-cHL, 4 were from 41-60 years and 1 was above 60 years of age. Statistical analysis was done using Chi square/Fisher exact test. The p value was found to be highly significant (P<0.000).

Out of 15 cases of NS-cHL, B-symptoms were present in 5 (33.3%) cases. It was absent in all cases of MC-cHL. There were 5 cases of LD-cHL, out of which 4 had B-symptoms (80%). P value was calculated for B symptoms vs diagnosis and was found to be significant (P<0.033).

Out of 5 cases of LD-cHL, 4 (80%) cases showed lymphadenopathy involving multiple areas and multiple lymph nodes on both sides of the diaphragm. Out of 5 cases of MC-cHL, 4 (80%) showed lymphadenopathy of single area with multiple nodes. P value was calculated for lymphadenopathy vs diagnosis and was found to be significant ( $P < 0.036$ ).

## DISCUSSION

The diagnosis of cHL is based on the presence of the neoplastic RS cells and its variants in a reactive inflammatory background.<sup>(1)</sup>

NS-cHL is the most common subtype, a disease of a younger age group and seen more frequently in developed countries. However, the incidence of all these subtypes vary greatly in other geographical areas.<sup>(1,4)</sup> It is characterized by Lacunar cells, sclerosis and nodular pattern.<sup>(1)</sup> NS-cHL is sub-classified into 2 grades based on the presence of numerous large bizarre and anaplastic type of Reed Sternberg cells, which are graded as grade I.<sup>(1)</sup>

As compared to other forms of cHL, NS-cHL is more common in females than males.<sup>(5)</sup> It is less frequently associated with EBV virus.<sup>(6)</sup> It has been observed that NS-cHL cases in HIV positive patients decrease with decreasing CD4 count suggesting that an intact immune system is needed for its development.<sup>(3)</sup>

In our study, it was seen that NS-cHL was more common in males and male-to-female ratio was 1.5:1. It is a disease

predominant in females in the Western series. It was seen mostly in younger age group comparable to the western literature.

In comparison to NS-cHL the MC-cHL and LD-cHL are seen in patients with lower socio-economic status and the disease is more prevalent in males with frequent EBV infection of the neoplastic cells.<sup>(2)</sup> Typically, the pattern of spread in these showed sparing of mediastinum and thymus gland.<sup>(2)</sup>

MC-cHL exhibits a bimodal age occurrence and is the subtype seen in paediatric age group. The incidence pattern in MC-cHL in the very young and elderly reflects the EBV infection.<sup>(2)</sup>

In our study, the MC-cHL cases showed a bimodal peak and the mediastinum was not involved with most of the cases in the early stage. Cases of LD-cHL showed infrequent mediastinal involvement and mostly were elderly males.

The newer insights in HL indicate that MC-cHL and LD-cHL appear to share clinical, epidemiological and biological features and differ mostly in depletion of background lymphocytes.<sup>(2)</sup> These subtypes are considered two grades of a single disease entity and both occur in the setting HIV infection.<sup>(3)</sup> These morphological subtypes confer a significantly worse prognosis.<sup>(2)</sup> In our study, MC-cHL presented as early stage disease and LD-cHL were aggressive at presentation. One patient with LD-cHL was HIV positive. The EBV status in our cases was not studied.

HL Subtypes	Our Study	Yildirim et al <sup>(7)</sup>	Shimabukuro V A et al <sup>(8)</sup>	Rana et al <sup>(9)</sup>
NLPHL	0 cases	7 cases (2.1%)	145 cases (5%)	0 cases
NS-cHL	15 cases (50%)	173 cases (52.7%)	1668 cases (63%)	17 cases (16.34%)
MC-cHL	5 cases (16.7%)	107 cases (32.5%)	731 cases (27%)	60 cases (57.69%)
LR-cHL	3 cases (10%)	28 cases (8.5%)	100 cases (4%)	17 cases (16.34%)
LD-cHL	5 cases (16.7%)	14 cases (4.2%)	23 cases (1%)	10 cases (9.62%)
cHL-core biopsy	2 cases (6.7%)	0 cases	0 cases	0 cases

**Table 4: Comparison of HL Subtypes between 4 Studies**

Majority of NS-cHL (11/15 cases) in our study occurred in 21-40 years class interval with the median age being 25 years. There was a male preponderance with a male-to-female (M:F) ratio of 1.5:1. In MC-cHL the median age was slightly higher (30.5 years) with a similar gender ratio of 1.5:1. The LR-cHL showed a more higher median age (33 years), but with M:F ratio of 1:2. The LD-cHL was a disease of elderly with a median age of 61.5 years and occurred only in males in our study.

In a study by Almasri N M.<sup>(10)</sup> the median age for NS-cHL was younger (18.5 years) as compared to our study, but showed a similar M:F ratio (1.38:1). Majority of the cases of NS-cHL were located in the age group of 20-40 years in the study by Yildirim et al<sup>(7)</sup> similar to our study.

In our study, the percentage of LR-cHL and LD-cHL cases were higher than those in the study done by Shimabukuro-Vornhagen A et al.<sup>(8)</sup>

LR-cHL is a recently identified subtype.<sup>(2)</sup> In our study, it was seen that 10% of cases were of LR-cHL. In older studies, it was often misdiagnosed as NLPHL.<sup>(2)</sup> In this subtype, the neoplastic cells are found in a B cell rich microenvironment of the mantle and marginal zone.<sup>(2)</sup> The neoplastic cells resemble Lymphocyte-predominant (LP) cells and immunohistochemistry is critical for accurate diagnosis.<sup>(1,2)</sup> As compared to NS-cHL, the cases have infrequent mediastinal involvement and an older age at presentation. The prognosis

is excellent. Patients with LR-cHL on an average are older and usually present with stage I to stage II disease. It is a rare entity and accounts for only 4% of HL.<sup>(4)</sup> In our study, none of the LR-cHL cases had any mediastinal involvement and cases were found in all age group.

The MC-cHL and NS-cHL were morphologically very characteristic and CD 15 negativity did not influence the diagnosis.

In a clinicopathological study of 119 cases, CD 20 positivity showed a trend towards improved failure free survival and disease free survival.<sup>(11)</sup> In our study, CD20 was focally and weakly positive in 5 cases of NS-cHL and 2 cases of MC-cHL supporting the B cell origin.

## CONCLUSION

Nodular sclerosis is a distinctive type of HL and was the most common subtype in our study. It occurred in young adults, predominantly in males with frequent mediastinal involvement. A female preponderance is described in western literature. In Northern India, MC-cHL is the most frequent subtype indicating a geographic difference in our country, which may be related to the socioeconomic condition. Mixed cellularity cHL occurred in a wider age range and included paediatric age group and was rare in young adults. Mediastinal involvement was absent. LD-cHL occurred in the older age

group with infrequent mediastinal involvement. The disease was seen only in males. The disease was more extensive and one patient had HIV AIDS. LR-cHL was seen only in 3 cases and included both children and older adults. IHC was extremely useful to confirm the diagnosis. In this study, NS-cHL appears to be a separate entity; however, it is not clear that MC-cHL and LD-cHL are biologic continuum.

#### REFERENCES

1. Agostinelli C, Pileri S. Pathobiology of Hodgkin Lymphoma. *Mediterranean Journal of Haematology and Infectious Diseases* 2014;6(1):e2014040.
2. Mani H, Jaffe ES. Hodgkin lymphoma: an update on its biology with new insights into classification. *Clin Lymphoma Myeloma* 2009;9(3):206-16.
3. Biggar RJ, Jaffe ES, Goedert JJ, et al. Hodgkin lymphoma and immunodeficiency in persons with HIV/AIDS. *Blood* 2006;108(12):3786-91.
4. Lennert K, Mohri N. Histological classification and occurrence of Hodgkin's disease. *Internist (Berl)* 1974; 15(2):57-65.
5. Pileri SA, Ascani S, Leoncini L, et al. Hodgkin's lymphoma: the pathologist's viewpoint. *J Clin Pathol* 2002;55(3) : 162-76.
6. Jarrett AF, Armstrong AA, Alexander E. Epidemiology of EBV and Hodgkin's lymphoma. *Ann Oncol* 1996;7 (Suppl 4):5-10.
7. Yıldırım M, Yıldız M, Kurtoğlu E, et al. Epidemiology and histological subtypes of Hodgkin lymphoma in the south-west of Turkey. *Gulhane Med J* 2012;54(3):216-9.
8. Shimabukuro-Vornhagen A, Haverkamp H, Engert A, et al. Lymphocyte-rich classical Hodgkin's lymphoma: clinical presentation and treatment outcome in 100 patients treated within German Hodgkin's study group trials. *J Clin Oncol* 2005;23(24):5739-45.
9. Rana R, Chopra R, Masih K, et al. Hodgkin's disease: a clinicopathologic study. *Indian J Pathol Microbiol* 1995;38(3):267-71.
10. Almasri NM. Hodgkin's lymphoma in North Jordan. Does it have a different pattern? *Saudi Med J* 2004;25(12): 1917-21.
11. Tzankov A, Krugmann J, Fend F, et al. Prognostic significance of CD20 expression in classical Hodgkin lymphoma: a clinicopathological study of 119 cases. *Clin Cancer Res* 2003;9(4):1381-6.