

EVALUATION OF RESULTS OF TITANIUM ELASTIC NAILING SYSTEM IN PAEDIATRIC LOWER EXTREMITY FRACTURES OF LONG BONESPradeep Choudhari¹, Sachin Chhabra², Vivek Kiyawat³**HOW TO CITE THIS ARTICLE:**

Pradeep Choudhari, Sachin Chhabra, Vivek Kiyawat. "Evaluation of Results of Titanium Elastic Nailing System in Paediatric Lower Extremity Fractures of Long Bones". Journal of Evolution of Medical and Dental Sciences 2014; Vol.3, Issue 72, December 22; Page: 15303-15309, DOI:10.14260/jemds/2014/4059

ABSTRACT: BACKGROUND: Flexible intramedullary nails have gained widespread popularity for stabilization of pediatric fractures of long bones of lower extremity. **AIMS:** Purpose of our study was to evaluate safety and efficacy of titanium elastic nailing system (TENS) for paediatric lower extremity long bone fractures. **METHODS:** All children operated for lower extremity long bone fractures at our tertiary care centre (Sri Aurobindo Institute of Medical Sciences, Indore) between Jan 2012 to Dec 2013 who underwent fixation with TENS were reviewed. Out of 57 cases identified, 4 cases were lost to follow-up. Of the 53 cases, 58.49 per cent were males (boys 31 and girls 22). The average age of patients was 10.8 years (range 6- 14 years). The mean weight was 28.8 kg (range 16 kg - 42 kg). All fractures were reduced by closed manipulation. Outcomes were classified as excellent, satisfactory or poor according to Flynn flexible nail fixation classification. **RESULTS:** As per Flynn classification, we had 36 excellent, 14 good and 1 poor result. All patients attained complete healing at mean of 11.2 weeks (Range 7 - 16 weeks). Mean duration of hospital stay was of 5 days (Range 3 - 16 days). **CONCLUSION:** On the basis of results obtained TENS is an effective method for management of unstable paediatric fractures of long bones of lower extremity allowing rapid mobilization with minimal complications.

KEYWORDS: Paediatric fractures, flexible nails, titanium elastic nails, lower extremity fractures

INTRODUCTION: Majority of paediatric fractures can be managed by closed reduction and immobilization accompanied by a close follow-up. However management of fractures of long bones of lower extremity in growing children has been a subject of debate in paediatric orthopaedic community. In the past management paediatric lower extremity fractures involved use of treatment options like traction alone, early spica cast and traction followed by spica cast. However, these treatment options involved prolonged bed rest and loss of days from school for adolescents and school-aged children. Also, it added to the babysitting problem in homes with both the parents working. In recent times, operative management of certain fractures has shown significantly better results than closed treatment. Operative management is being used to maintain optimal alignment and early mobilization. Technical advances such as introduction of flexible intramedullary nailing have further increased enthusiasm for operative management of paediatric fractures of lower extremity.¹

Paediatric unstable fractures of long bones of lower limbs demand operative treatment to maintain alignment and preserve function.² Several treatment options are available for operative treatment of these fractures, however, flexible intramedullary nails have become increasingly popular in the skeletally immature population mainly because of its clinical effectiveness and low risk of complications. Flexible intramedullary nailing using Titanium Elastic Nailing System (TENS) have

ORIGINAL ARTICLE

been used with great success in Europe for a number of decades, but it was in later half of 1990s when elastic nailing gained acceptance in North America and since then it is being extensively used.

Development of TENS has provided a simple, biocompatible, load bearing internal splint allowing early mobilization. As epiphyseal growth plate is not breached, it avoids growth disturbance and has minimal risk of complications and has thus emerged as the most popular surgical modality for management of unstable paediatric lower extremity fractures of long bones.³

METHODS: This study was designed as a retrospective clinical study to assess the results of operative treatment of paediatric lower extremity fractures using TENS. Children operated for lower extremity long bone fractures at our tertiary care centre (Department of Orthopaedics, Sri Aurobindo Institute of Medical Sciences and PG Institute, Indore) between Jan 2012 to Dec 2013 with TENS were included retrospectively. Case records were studied and roentgenograms were analyzed. Of the total 57 cases identified, 4 cases were lost to follow-up. Out of the 53 cases, 58.49 per cent were males (Boys 31 and Girls 22). The average age of patients was 10.8 years (range 6- 14 years). The mean weight of patients was 28.8 kg (range 16kg - 42 kg). The diagnosis was based on typical X-ray imaging.

Injuries were due to motor vehicle accident, fall from height or sports related injuries. All the fractures were reduced by closed manipulation. Indication for surgery was inability to attain stable reduction with closed treatment. None of the patients developed compartment syndrome during their course of treatment.

All patients were operated on radiolucent table under IITV (image intensifier television) guidance for visualizing reduction and verification of nail passage. Nails were inserted from proximal to distal for tibia and from distal to proximal for femur. Bone was exposed with a longitudinal incision. Soft tissue was spread using artery forceps. The periosteum was incised longitudinally with cortex exposed. With the help of sharp awl, entry was made through the cortex to obtain access to the medullary cavity. Care was taken to ensure that growth plate was not breached in any of the cases while making the entry point. Nails were bent prior to insertion and were inserted manually using T-insertion handle. Once fracture site was reached, fracture was manipulated under IITV guidance to obtain reduction and nails were passed further unto metaphysis and adequate three point fixation was ensured with tip of nails facing opposite directions.

Knee and ankle range of motion exercises were started from second post-operative day and weight bearing was started after radiological confirmation of fracture healing.

RESULTS: Majority of fractures were operated on second day post admission. All nails were inserted closer to the knee joint i.e. from distal to proximal for femoral fractures whereas tibial nails were inserted from proximal to distal.

All nails were inserted in a closed manner under IITV guidance. Mean duration of hospital stay was of 5 days (range 3 - 16 days). The average operative time for nail insertion was 30 minutes (Range of 20 to 75 minutes). All patients attained complete healing at mean of 11.2 weeks (range 7-16 weeks). TENS were removed in all the patients on average of 27.2 weeks (Range 22 - 35 weeks).

Most of the complications encountered were of transient nature and resolved without affecting the functional outcome and did not require any surgical intervention. Soft tissue irritation caused by the ends of the nail at the entry points was encountered in 3 cases (5.3%). Limb

ORIGINAL ARTICLE

lengthening was observed in 4 cases (7.5%) with an average of 0.7 cm (range 0.5-1.1cm). Pain was present in 1 case (1.9%). No instance of refracture following nail removal was encountered. None of the patients in our series required any secondary surgical intervention or readmission following discharge, except for nail removal.

As per TENS outcome scoring system described by Flynn et al, we had 36 excellent, 14 good and 1 poor result.

DISCUSSION: Surgical management of long bones of lower extremity in paediatric age group has been controversial. Multiple treatment options have been tried over past two to three decades. Complications were found to be associated with every treatment option: Immobilization with spica cast alone or along with traction was found to be associated with complications like limb-length discrepancy, angulation, psychological and economic complications.⁴⁻⁶ External fixator resulted in pin tract infection, loss of reduction, refracture after removal of external fixator, malunion and loss of days from school⁷. Plating as a treatment modality is not practiced commonly for paediatric fractures in children as it involves bigger surgical incision leading to higher likelihood of infection, stripping of periosteum and loss of fracture haematoma. Wound infection and impingement was found to be associated with minimally invasive plate osteosynthesis (MIPO) used in management of paediatric tibial fractures.⁸⁻⁹ In case of femoral fractures, MIPO has been associated with malalignment and delayed union.⁸⁻⁹

An ideal implant for treatment of paediatric lower extremity long bone fractures should be load sharing, allowing early mobilisation, without disrupting the blood supply of epiphyseal growth plates, maintains limb length and alignment till the fracture healing marked by bridging callus occurs.¹⁰

This study was aimed to evaluate the safety and efficacy of titanium elastic nailing system for paediatric lower limb fractures after an extensive review of published data.

TENS has been designed for the treatment of diaphyseal fractures in children and is being used presently for the treatment of paediatric femoral fractures,¹¹⁻¹⁵ and, increasingly, for surgical management of paediatric tibial fractures.^{16,17} It is based upon the principle of three point fixation that works by balancing forces between two opposing flexible implants. This balance is attained by using a nail diameter of 40% of narrowest canal diameter leading to a double-C construct. This is in contrast to Enders nails that achieve stability from nail stacking and canal fill. Titanium nails provide stable and elastic fixation, leading to controlled motion at the fracture site leading to healing by callus formation.³

Our average operative time, hospital stay, bone healing time, and nail removal time were quite similar to other data in literature.^{3,12-17}

Rotational malalignment was not noted in this study due to utmost care being taken during intraoperative limb positioning. Ligier et al,¹¹ Flynn et al³ and Gamal et al¹⁰ have reported a similar finding, supporting the concept that TENS can give rotational stability provided adequate care is taken during nail insertion and following operation.

None of the patients in our study developed compartment syndrome during their course of treatment which was different from findings of Sanker et al who reported four patients developing compartment syndrome during course of treatment and three patients with impending compartment syndrome for whom fasciotomies were performed at the time of index surgery.²

ORIGINAL ARTICLE

None of the patients in our series required any secondary surgical intervention or readmission following discharge, except for nail removal, similar to finding to Sankeret al.²

Limb lengthening was observed in 4 cases (5.3%) with an average of 0.7 cm (Range 0.5-1.1cm) for which authors believe that a longer follow-up duration is required to determine its persistence or correction.

CONCLUSION: To conclude TENS is a simple, biocompatible, reliable and effective method for management of unstable paediatric fractures of long bones of lower extremity with short operative time, minimal blood loss, shorter hospital stay, allowing rapid mobilization and minimal complications, although all patients require a small secondary procedure i.e. implant removal at about 6 month interval from primary procedure.

REFERENCES:

1. Flynn JM, Skaggs D, Sponseller PD, Ganley TJ, Kay RM, Leitch KK. The Operative Management of Pediatric Fractures of the Lower Extremity. *J Bone & Joint Surg.* Dec 2002, 84 (12) 2288-2300;
- Nielsen AB, Simonsen O. Displaced forearm fractures in children treated with AO plates. *Injury.* 1984; 15: 393-396.
2. WN Sankar, KJ Jones, BD Horn, L Wells. Titanium elastic nails for pediatric shaft fractures. *J Child Orthop.* Nov 2007; 1(5): 281–286.
3. Flynn JM, Hresko T, Reynolds RA et al. Titanium elastic nails for paediatric femur fractures: A multi-center study of early results with analysis of complications. *J Pediatr Orthop* 2001; 21: 4-8.
4. Martinez AG, Carroll NC, Sarwark JF, Dias LS, Kelikian AS, Sisson GA. Femoral shaft fractures in children treated with early spicacast. *J PediatrOrthop* 1991; 11: 712-716.
5. Ferguson J, Nicol RO. Early spica treatment of pediatric femoral shaft fractures. *J Pediatr Orthop* 2000; 20(2): 189-192.
6. Sanders JO, Browner RH, Mooney JF, Raney EM, Horn BD, Anderson DJ et al. Treatment of femoral fractures in children by pediatricorthopedists: Results of a 1998 survey. *J Pediatr Orthop.* 2001; 21: 436-444.
7. Gregory P, Pevny T, Teague D. Early complications with external fixation of pediatric femoral shaft fractures. *J Orthop Trauma* 1996; 10(3):191-198.
8. Lau TW, Leung F, Chan CF, Chow SP. Wound complication of minimally invasive plate osteosynthesis in distal tibia fractures. *Int Orthop.* 2008 Oct; 32 (5): 697-703.
9. Apivatthakakul T, Chiewcharntanakit S. Minimally invasive plate osteosynthesis (MIPO) in the treatment of the femoral shaft fracture where intramedullary nailing is not indicated. *Int Orthop.* 2009 Aug; 33(4):1119-1126.
10. Gamal E, Mohamed MF, Mohamed AK, Ahmed E. Titanium elastic nail fixation for paediatric femoral and tibial fractures. *Acta Orthop. Belg.,* 2009, 75, 512-520.
11. Ligier JN, Metaizeau JP, Prevot J, Lascombes P. Elastic stable intramedullary nailing of femoral shaft fractures in children. *J Bone Joint Surg Br.* 1988; 70: 74-7.
12. Lascombes P, Prevot J, Ligier JN, Metaizeau JP, Poncelet, T. (1990). Elastic stable intramedullary nailing in forearm shaft fractures in children: 85 cases. *Journal of Pediatric Orthopaedics,* 1990.10(2), 167-171.

ORIGINAL ARTICLE

13. Calder PR, Achan P, Barry M. Diaphyseal forearm fractures in children treated with intramedullary fixation: Outcome of K-wire versus elastic stable intramedullary nail. *Injury*. 2003; 34: 278-282.
14. Ligier JN, Metaizeau JP, Prevot J, Lascombes P. Elastic stable intramedullary pinning of long bone shaft fractures in children. *J Bone Joint Surg Br*. 1988 Jan; 70 (1): 74-7. *Z Kinderchir*. 1985; 40: 209-12.
15. Qidwai SA. Intramedullary Kirschner wiring for tibia fractures in children. *J Pediatr Orthop*. 2001 May-Jun; 21(3): 294-7.
16. Buechsenschuetz KE, Mehlman CT, Shaw KJ, Crawford AH, Immerman EB. Femoral shaft fractures in children: Traction and casting versus elastic stable intramedullary nailing. *J Trauma* 2002; 53- 5: 914-921.
17. Gregory P, Sullivan JA, Herndon WA. Adolescent femoral shaft fractures: rigid versus flexible nails. *Orthopedics* 1995; 18: 645-649.

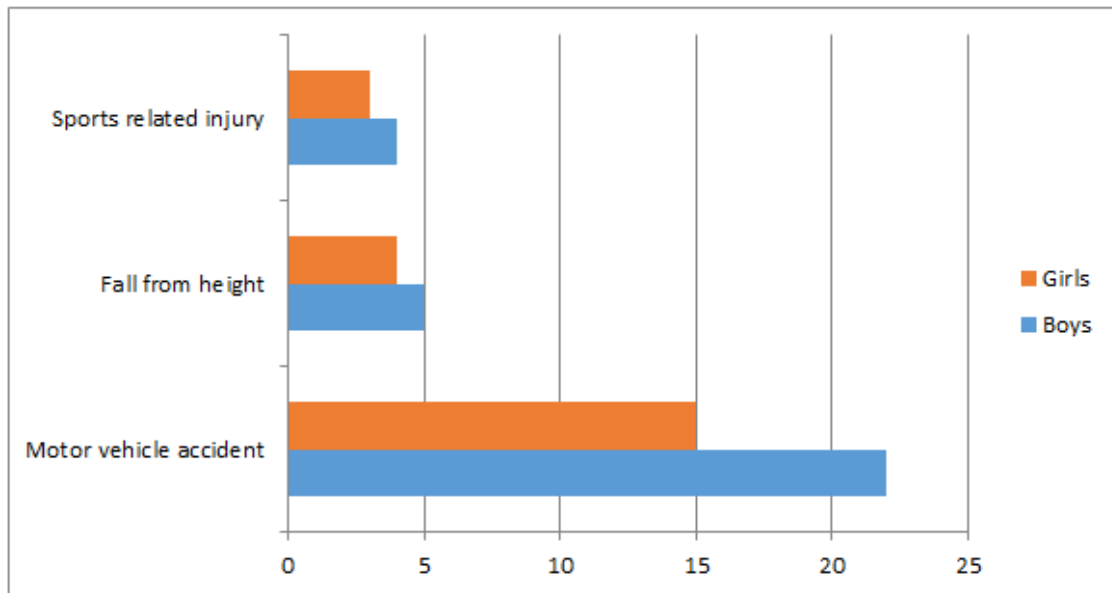


Chart 1: Etiology of fractures with gender distribution

	Poor results	Satisfactory results	Excellent results
Limb-length discrepancy	>2cm	<2cm	<1cm
Malalignment	>10 °	10 °	5°
Pain	Present	None	None
Complication	Major and lasting morbidity	Minor and resolved	None

Table 1: TENS outcome scoring classification as proposed by Flynn et al⁴

ORIGINAL ARTICLE

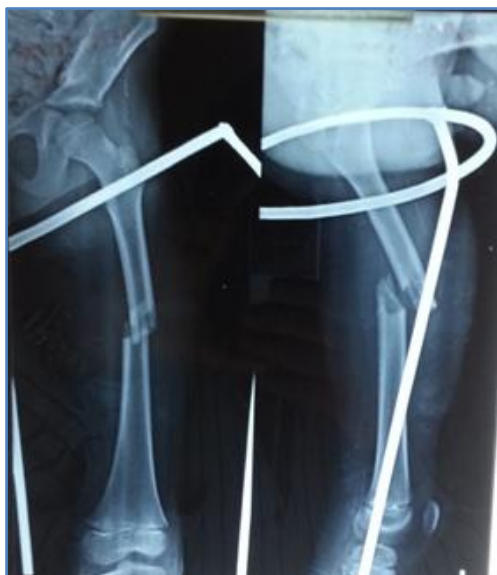

Figure 1: X-ray images of fracture shaft femur 9 year old boy: pre op

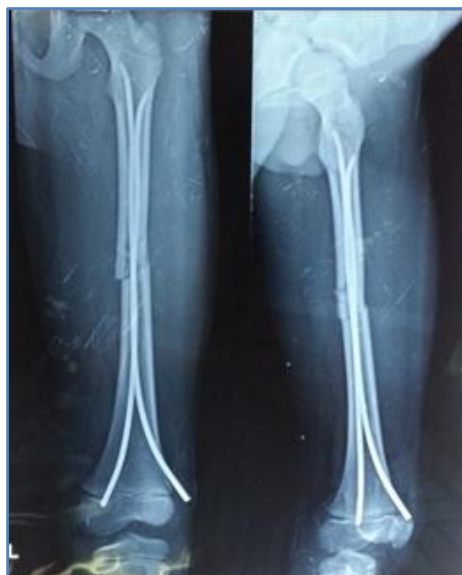

Figure 2: X-ray images of fracture shaft femur of 9 year old boy: immediate post op

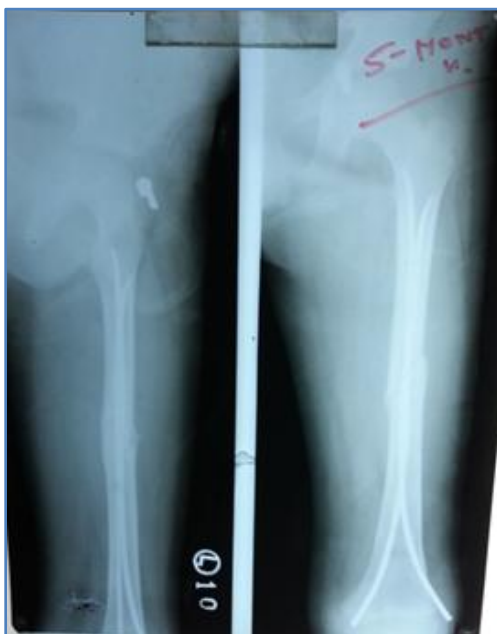

Figure 3: X-ray images of fracture mid shaft femur of 9 year old boy: at union (12 weeks)

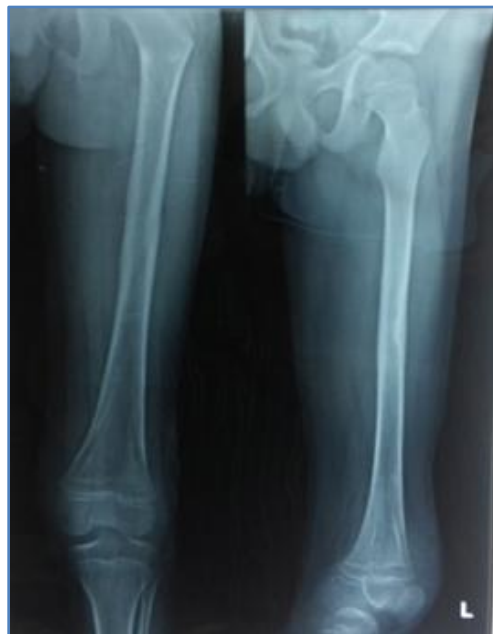

Figure 4: X-ray images of fracture mid shaft femur of 9 year old boy: following implant removal

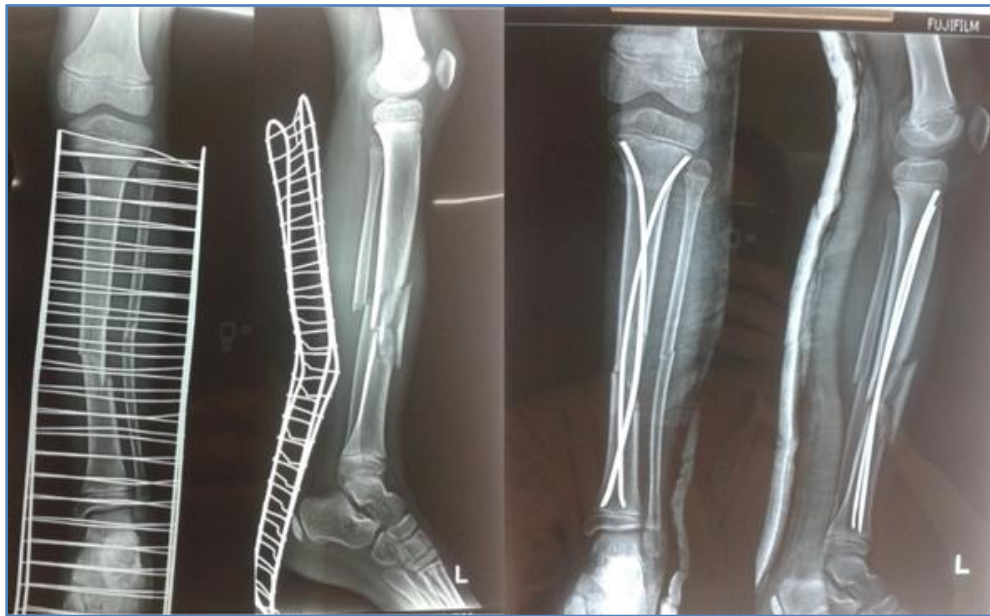

Figure 5: Pre-op and post-op x-ray images of fracture mid shaft tibia treated with TENS

AUTHORS:

1. Pradeep Choudhari
2. Sachin Chhabra
3. Vivek Kiyawat

PARTICULARS OF CONTRIBUTORS:

1. Associate Professor, Department of Orthopaedics, Sri Aurobindo Institute of Medical Sciences and PG Institute, Indore.
2. Assistant Professor, Department of Orthopaedics, Sri Aurobindo Institute of Medical Sciences and PG Institute, Indore.
3. Junior Resident, Department of Orthopaedics, Sri Aurobindo Institute of Medical Sciences and PG Institute, Indore.

NAME ADDRESS EMAIL ID OF THE CORRESPONDING AUTHOR:

Dr. Pradeep Choudhari,
#7/3/3, Ahilaya Mata Colony,
Near Charak Hospital,
Rani Sati Gate,
Indore-452003, India.
Email: pchoudhari@rediffmail.com

Date of Submission: 09/12/2014.
Date of Peer Review: 10/12/2014.
Date of Acceptance: 16/12/2014.
Date of Publishing: 20/12/2014.