

## EFFECT OF PROPHYLACTIC BROMFENAC 0.09% ON CYSTOID MACULAR EDEMA ASSESSED USING OPTICAL COHERENCE TOMOGRAPHY QUANTIFICATION OF TOTAL MACULAR VOLUME AFTER CATARACT SURGERY

M. Ramesh Chandra<sup>1</sup>, P. Sanjeeva Kumar<sup>2</sup>, P. Kishore Kumar<sup>3</sup>, D. V. Giddaiah<sup>4</sup>, Govardhan Reddy<sup>5</sup>

### HOW TO CITE THIS ARTICLE:

M. Ramesh Chandra, P. Sanjeeva Kumar, P. Kishore Kumar, D. V. Giddaiah, Govardhan Reddy. "Effect of Prophylactic Bromfenac 0.09% on Cystoid Macular Edema assessed using optical Coherence Tomography Quantification of total Macular Volume after Cataract Surgery". Journal of Evolution of Medical and Dental Sciences 2015; Vol. 4, Issue 02, January 05; Page: 253-262, DOI: 10.14260/jemds/2015/40

**ABSTRACT: PURPOSE:** To evaluate the efficacy of prophylactic administration of the topical nonsteroidal anti-inflammatory drug (NSAID) Bromfenac 0.09% on acute (within 4 weeks of surgery) cystoids macular edema (CME) and total macular volume (TMV) in patients having phacoemulsification cataract surgery. **SETTING:** Department of Ophthalmology, shantiram general hospital, nandyal. **METHODS:** This open-label nonmasked randomized (random number assignment) study comprised 100 eyes. Exclusion criteria included hypersensitivity to the NSAID drug class, aspirin/NSAID-induced asthma, and pregnancy in the third trimester. Bromfenac 0.09% was administered starting 1 day before surgery and for 28 days after surgery for a total of 30 days. The outcome measure was macular swelling, which was quantified by the optical coherence tomography. **RESULTS:** At 1 month, there was a statistically significant difference in TMV between the control group (0.4420 mm<sup>3</sup>) and the Bromfenac 0.09% group (0.2392 mm<sup>3</sup>), with the Bromfenac 0.09% group having 45.8% less macular swelling (P Z.009). Multiple linear regression with backward selection indicated a 44.3% (P Z.013) and 46.1% (P Z.030) reduction in macular swelling in the Bromfenac 0.09% group at 1 week and 1 month, respectively. **CONCLUSION:** Used prophylactically after cataract surgery, Bromfenac 0.09% was efficacious in decreasing postoperative macular edema. **KEYWORDS:** Bromfenac , cystoid macular edema , optical coherence tomography.

**INTRODUCTION:** Cystoid macular edema (CME) is the most frequent cause of postoperative decreased vision in patients having uneventful cataract surgery, with a prevalence of 0.2% to 1.0%.<sup>1-5</sup> The pathogenesis of CME involves surgical trauma to the iris, ciliary body, or lens epithelial cells; this causes a release of phospholipids that, through several cascades, generates mediators of inflammation.<sup>6</sup> The mediators diffuse through the vitreous to disrupt the blood-retinal barrier (BRB), resulting in serum pooling in macular tissue.<sup>6</sup> Diseases affecting the BRB, such as diabetes, hypertension, aging, and uveitis, increase the risk for CME. The prevalence of CME after cataract surgery is increased by surgical complications (vitreous loss), pre-existing ocular conditions (uveitis, diabetes), and drugs (eg, latanoprost).<sup>1,6</sup>

Rossetti, et al.<sup>4</sup> found a positive therapeutic effect of nonsteroidal anti-inflammatory drugs (NSAIDs) and corticosteroids in the prevention and treatment of CME. Several other studies<sup>9-15</sup> support the use of anti-inflammatory compounds in cataract surgery.

Optical coherence tomography (OCT) is a diagnostic tool that allows objective quantification of the spectrum of CME by directly measuring changes in the volume of the retina.<sup>16-21</sup> Unlike fluorescein angiography,

## ORIGINAL ARTICLE

---

OCT is a noninvasive procedure that is useful for evaluations that require multiple measurements of parameters, such as those associated with CME after cataract extraction.<sup>19</sup> Earlier studies report detection of patients with CME after cataract surgery by OCT, but not by clinical examination or fluorescein angiography.<sup>22</sup>

At present, there are 5 available topical ophthalmic NSAID preparations: ketorolac tromethamine 0.5%;

- diclofenac sodium 0.1%,
- flurbiprofen,
- nepafenac 0.1%,0.3%, and
- bromfenac 0.09%,

The current study evaluated the efficacy of prophylactic administration of Bromfenac 0.09% in addition to routine antibiotic and prednisolone drops on acute CME within the first 4 weeks after phacoemulsification cataract surgery. Bromfenac 0.09% was used because of its proven efficacy and excellent safety profile and because it is commonly used at our institution.

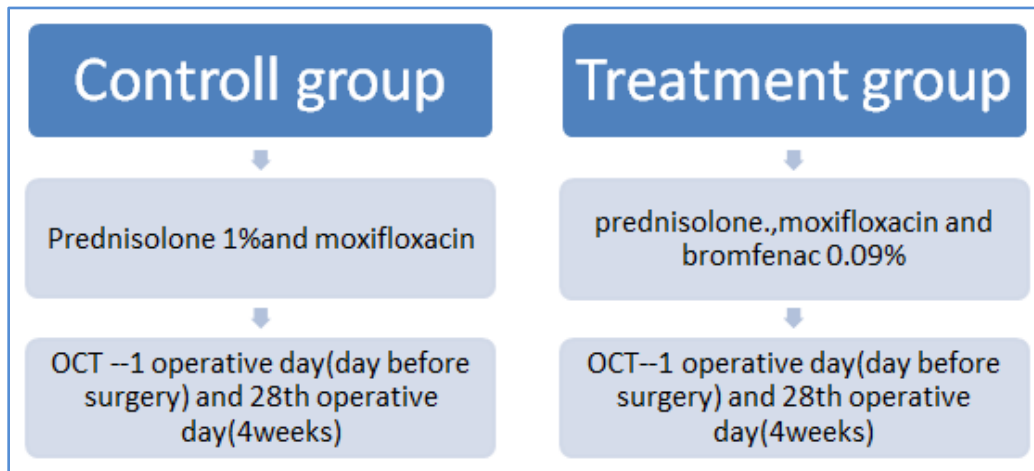
Cystoid macular edema was assessed by OCT using total macular volume (TMV) as the indicator of macular swelling.

**PATIENTS AND METHODS:** All clinic patients having phacoemulsification with intraocular lens (IOL) implantation who agreed to participate and met the inclusion criteria were consecutively enrolled in this paired-comparison open-label nonmasked randomized clinical trial. All surgeries were performed by 1 of 4 cataract surgeons (Ramesh. C, Kishore k, Sanjeev. K, P. Sasi) at shantiram general hospital nandyal.

### **ETHICS REVIEW:**

- This study was approved by ethical committee of shantiram medical college.
- After receiving an explanation of all procedures and before their enrolment in the trial, all patients provided written informed consent.

**STUDY PROTOCOL:** Postoperatively, all patients received a 6weeks tapered course of prednisolone acetate 1% 4 times a day and moxifloxacin 0.5% 4 times a day. Eyes in the NSAID treatment group received 1 drop of Bromfenac 0.09% 1 time a day beginning 1 day before surgery and for 28 days after surgery, for a total of 30 days. Eyes in the comparison (control) group received only prednisolone and moxifloxacin drops. Ocular examinations, including OCT measurements, were performed and recorded preoperatively and 7 days (range 5 to 10 days) and 28 days (range 4 to 6 weeks) postoperatively.



**Fig. 1: Shows a summary of the study protocol**

The exclusion criteria were hypersensitivity to the NSAID drug class, aspirin/NSAID-induced asthma, and pregnancy in the third trimester. Patient information collected included age, sex, and relevant clinical data such as history of uveitis, diabetes mellitus (with or without diabetic retinopathy), macular disease, glaucoma, pseudoexfoliation syndrome (PEX), previous intraocular surgery, and hypertension. An attempt was made to include as many patients as possible with documentation of the above comorbid conditions for subgroup analysis.

**OPTICAL COHERENCE TOMOGRAPHY PROTOCOL:** Optical coherence tomography measurements of macular thickness were performed using a Stratus OCT version 5.0.1. The OCT protocol adapted was a fast macular thickness map scan with a retinal thickness/volume tabular output report and a retinal thickness output report. The quantity of TMV (included in the OCT retinal thickness/ volume tabular output report) was used as a measure or surrogate of macular swelling. The best-quality macular thickness maps of all scans done at each visit were chosen and OCT tabular thickness parameters, including central foveal minimum, fovea, 4 quadrants of inner retina, 4 quadrants of outer retina, and TMV, were collected from each patient for statistical analysis.

**STUDY ENDPOINT:** The primary endpoint of the study was the difference in TMV between 1 month and baseline in the Bromfenac 0.09% and control groups. A significant difference would directly quantify the efficacy of Bromfenac 0.09% in preventing acute macular swelling after cataract surgery.

**STATISTICAL ANALYSIS:** Data were entered into a Microsoft Excel spreadsheet and analyzed using SPSS (version 12.0, SPSS, Inc.). Baseline data of patients in the treatment group and control group are described as means and proportions and compared using an appropriate Student t test or chi-square test. Demographic data, including age and sex, and clinical data, including diabetic status, history of glaucoma, hypertension, macular disease, PEX, and previous intraocular surgery, were recorded and compared between the 2 groups.

## ORIGINAL ARTICLE

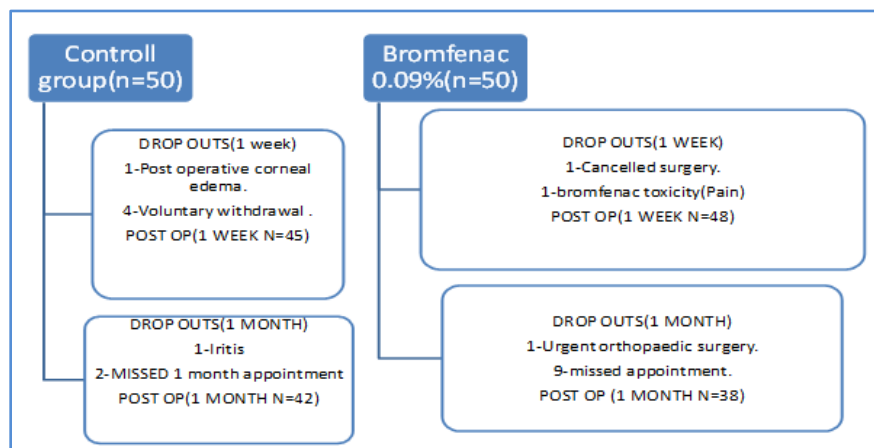
The main outcome variable, differences in TMV, was compared over 2 distinct time periods: TMV-W (difference in TMV at 1 week and baseline) and TMV-M (difference in TMV at 1 month and baseline). Mean TMV values and other OCT macular thickness parameters (central foveal minimum, fovea, 4 quadrants of inner retina, and 4 quadrants of outer retina) for the treatment group and control group were recorded and compared with a Student t test. In addition, a linear regression model with backward selection (using a cutoff of PO.10 for variable exclusion) was used to determine whether treatment was significantly associated with TMV after controlling for other potentially confounding variables in the study. Two-way interaction terms between the study variables were entered into the model (1 interaction at a time) to test the significance of interactions.

**RESULTS:** Of the 100 eyes 50 patients were randomized to each group.

Table 1 shows the baseline patient demographics and clinical characteristics of the 100 patients. The mean age of all patients was 71.9 G 10.2 years (range 45 to 92 years); 62 (62%) were women. Overall, baseline demographics and clinical characteristics were similar in both groups.

Patient demographics and clinical characteristics			
Parameter	CONTROL(n=50)	Bromfenac 0.09%(n=50)	P VALUE
Age(Y)	72.4+/-10.3	71.3+/-10.3	0.977
Mean+/-Standard deviation			0.073
Range	45-92	45-92	
Sex,n%			
Male			
Female			
Comorbidity,n			
Uveits	13	23	1.000
Type 1 DM	37	27	1.000
Type 2 DM with DR	0	1	1.000
Type 2 DM with out DR	1	1	0.617
Glaucoma	8	5	0.654
Hypertension	3	1	0.812
Macular disease	4	2	0.400
	19	17	1.000
	7	14	

All dropouts are accounted in Figure 2. Twelve patients. (2 control, 9 bromfenac) missed the 1-month postoperative appointment.



## ORIGINAL ARTICLE

There was a statistically significant difference in TMV-M values between the control and Bromfenac treatment groups ( $P < .05$ ) (Table 2), with the Bromfenac group having 45.8% less macular swelling on OCT. In the 1 month after surgery, the control group accumulated a mean value of 0.4420 mm<sup>3</sup> of macular fluid and the Bromfenac group, of 0.2392 mm<sup>3</sup> ( $P < .009$ ). The difference in TMV-W values showed a trend toward less macular swelling in the treatment group ( $P = .111$ ), although the difference did not reach statistical significance in univariate analysis.

PARAMETER	MEAN VALUE(mm <sup>3</sup> )	P value
TMV-W (1 week-baseline)		0.111
Control group(n=45)	0.3565	
Bromfenac group(n=48)	0.1744	
TMV-M (1 month-baseline)		0.009
Control group(n=42)	0.4420	
Bromfenac group(n=38)	0.2392	

At 1 week, Bromfenac therapy was associated with a 44.3% decrease ( $P < .013$ ) in TMV ( $b = -0.196$ ;  $P < .013$ ) after controlling for age ( $P < .033$ ). At 1 month, Bromfenac therapy was associated with a 46.1% decrease ( $P < .030$ ) in TMV ( $b = -0.204$ ;  $P < .030$ ) after controlling for age ( $P < .702$ ) and presence of type 2 diabetes mellitus ( $P < .05$ ). (Table 3).

**Table 3. The P values for differences in TMV between the control group and Bromfenac group after applying linear regression analysis with backward selection.**

Parameter	b	Standard Error	Standard b	Significance Value	Linear Regression Model P Value
TMV-W (1 week minus baseline) (mm <sup>3</sup> )	0.196	0.078	0.247	.013	.008
TMV-M (1 month minus baseline) (mm <sup>3</sup> )	0.204	0.092	0.235	.030	.008

TMV: total macular volume  
 \*Significant variables in backward regression include constants (b, standard error, standardized b, and significance), age (same as above), and randomization (no treatment versus treatment; same as above).

No interaction terms were statistically significant. Table 4 shows an analysis of all OCT macular thickness parameters in the Bromfenac and control groups.

## ORIGINAL ARTICLE

**There was a statistically significant difference between the control and Bromfenac groups in the following parameters:**

- Temporal outermacula-W (1week minus baseline), nasal.
- Outer macula-W(1 week minus baseline), superior inner.
- Macula-M (1 month minus baseline), and inferior outer.
- Macula-M (1 month minus baseline).

Parameter	Mean Value (mm)		P Value_*
	Control Group	Bromfenac Group	
<b>TMV-W</b>			
(1 week minus baseline)			
Foveal minimum-W	175.2	175.7	.957
Fovea-W	15.7	8.4	.136
Temporal inner macula-W	15.7	9.5	.170
Superior inner macula-W	10.5	7.1	.418
Nasal inner macula-W	12.9	9.0	.381
Inferior inner macula-W	16.1	11.8	.368
Temporal outer macula-W	11.8	3.6	.042
Superior outer macula-W	8.8	2.8	.087
Nasal outer macula-W	13.5	7.3	.048
Inferior outer macula-W	14.4	7.3	.101
<b>TMV-M</b>			
(1 month minus baseline)			
Foveal minimum-M	20.2	1.3	.116
Fovea-M	22.5	6.6	.119
Temporal inner macula-M	22.0	10.6	.058
Superior inner macula-M	22.1	10.1	.010
Nasal inner macula-M	20.9	12.18	.200
Inferior inner macula-M	19.1	15.7	.533
Temporal outer macula-M	13.2	7.1	.128
Superior outer macula-M	14.3	9.0	.139
Nasal outer macula-M	15.3	9.2	.084
Inferior outer macula-M	13.0	5.1	.047



## ORIGINAL ARTICLE

---

**DISCUSSION:** Total macular volume, a direct measure of macular swelling and a surrogate of CME pathogenesis, was significantly lower in the Bromfenac group than in the control group. The OCT TMV parameter behaves robustly as an objective indicator of macular swelling and clearly elucidates the amount of inflammation after cataract surgery. Differences in TMV values between the Bromfenac and control groups confirm that Bromfenac 0.09%, used prophylactically before cataract surgery and postoperatively, can decrease the amount of fluid collection in the macula by 43% 1 week post-surgery. This macular fluid reduction in the Bromfenac group was maintained (46%) up until 1 month after surgery. Extrapolating, this effect is protective in preventing CME in the acute phase after cataract surgery and can be seen as a method for retarding possible CME pathogenesis from developing.

Regarding TMV values in the Bromfenac group and control group, the difference between groups in TMV-M was statistically significant, with Bromfenac treated patients accumulating less macular fluid after surgery. When controlling for patient age, both TMV-W and TMV-M values were statistically significantly different between groups, indicating that administration of Bromfenac prevents macular fluid accumulation. Our linear regression model was also statistically significant, validating our randomization process. Thus, this trial found that preoperative and postoperative treatment with Bromfenac 0.09% prevented macular edema, as objectively assessed by OCT, as early as 1 week after surgery and that this effect was still viable at the 1-month mark. Although previous trials have examined CME pathogenesis and therapeutic efficacy with angiographic diagnosis of CME, this approach is fraught with difficulties relating to the fact that fluorescein angiography is a subjective diagnostic test. Optical coherence tomography, and more specifically TMV, bypass this subjective bias and allow ophthalmologists to numerically and objectively quantify macular edema. Such a paradigm has the added benefits of quantitatively monitoring inflammation and macular edema after cataract surgery.

Moreover, although other CME studies examined long-term disease progression and treatment, we focused on the acute inflammation stages after cataract surgery. It is apparent that macular swelling begins soon after surgery and can be reduced by administering Bromfenac 0.09% drops beginning 1 day before surgery for a total duration of 1 month. It is believed that administration of NSAID drops via the topical route is preferred and ideal to minimize these early inflammatory states as it allows concentration of the drug locally in the anterior and posterior segments without systemic reactions. Although this study lacks a longterm follow-up of the incidence of CME, our primary endpoint was to assess the efficacy of Bromfenac in the acute stages after cataract surgery as this is when CME pathogenesis is thought to begin. Similarly, the acute TMV endpoint was chosen to illustrate any protective prophylactic effect possessed by Bromfenac in preventing macular swelling as an indicator or surrogate for CME pathogenesis. The other OCT macular thickness parameters (central foveal minimum, fovea, 4 quadrants of inner retina, 4 quadrants of outer retina) were also assessed. Clinical CME was not used as a primary outcome because given its incidence (0.2% to 1.0%), an extremely large sample size would be required to detect a significant difference between groups. Whereas with an OCT parameter as a continuous variable, a statistically and clinically significant difference could be detected with a smaller sample size. In further assessing macular swelling after cataract surgery, several OCT macular thickness parameters were tested to depict the macular region most likely to accumulate extra fluid. It has been shown that retinal mapping using OCT software is a reproducible measure of retinal thickness.<sup>24,25</sup>

## ORIGINAL ARTICLE

---

Nicholas et al.<sup>24</sup> showed that the only OCT parameter to demonstrate a significant correlation with best corrected visual acuity is foveal minimum. However, in light of a report by Browning,<sup>26</sup> which showed that foveal zone thickness measurements are operator-dependent while TMV OCT measurements are independent of observers (no fixed or proportional bias), a modification was applied to this protocol and TMV was considered the primary measure of macular swelling. In the current study, at 1 week, there was a statistically significant difference between groups, with the control group accumulating more fluid in the temporal outer and nasal outer regions of the macula. The significance of this is that one can localize macular edema objectively and quantitatively using these OCT protocols; however, making conclusions regarding localization of edema using this information is difficult considering the statistical problems relating to multiple comparisons. In general, the retina is 0.10 mm thick at the ora serrata and 0.56mm thick at the posterior pole; the thinnest part of the retina (0.25 mm) is at the fovea.<sup>27</sup>

An important point of discussion that has largely been neglected by previous CME efficacy trials is the stringent exclusion criteria applied to the trial design. In the past, patients with comorbid conditions that increase the probability of developing CME in aphakic eyes (eg, diabetes mellitus) have been excluded. In the current trial, we are studying effectiveness of Bromfenac by randomizing and evaluating patients with various relevant comorbidities to the condition of CME. We believe that including and controlling for relevant comorbidities greatly enhances the scope of the randomized trial as its practice implications are more relevant to actual patient populations. Our scenario is much more realistic to the ubiquitous nature of cataract surgery in modern medicine and to the extrapolation of potential benefits that a prophylactic agent like Bromfenac would have in the surgeon's armamentarium given the diverse patient populations having cataract surgery; thus, this article discusses an effectiveness study rather than an efficacy study. In addition, this is relevant in the light of conditions that predispose to CME (eg, diabetes) because these patients are most in need of an agent that protects against this sight-threatening condition.

Our results are consistent with the practice implications of administering Bromfenac 0.09% starting 1 day before surgery and continuing for 1 month to prevent the development of macular edema associated with CME pathogenesis.

### REFERENCES:

1. Rossetti L, Autelitano A. Cystoid macular edema following cataract surgery. *Curr Opin Ophthalmol* 2000; 11: 65-72.
2. Norregaard JC, Bernth-Petersen P, Bellan L, et al. Intraoperative clinical practice and risk of early complications after cataract extraction in the United States, Canada, Denmark, and Spain. *Ophthalmology* 1999; 106: 42-48.
3. Wegener M, Alsbirk PH, Højgaard-Olsen K. Outcome of 1000 consecutive clinic- and hospital-based cataract surgeries in a Danish county. *J Cataract Refract Surg* 1998; 24: 1152-1160.
4. Rossetti L, Chaudhuri J, Dickersin K, et al. Medical prophylaxis and treatment of cystoid macular edema after cataract surgery; the results of a meta-analysis. *Ophthalmology* 1998; 105: 397-405.
5. Batterbury M, Bowling B. *Ophthalmology; an Illustrated Colour Text* 2<sup>nd</sup> ed. New York, NY, Elsevier, 2005; 60-61.



---

**ORIGINAL ARTICLE**

---

6. Miyake K, Ibaraki N. Prostaglandins and cystoid macular edema. *Surv Ophthalmol* 2002; 47 (suppl 1): S203–S218.
7. Simone JN, Whitacre MM. Effects of anti-inflammatory drugs following cataract extraction. *Curr Opin Ophthalmol* 2001; 12: 63–67.
8. Flach AJ. Cyclo-oxygenase inhibitors in ophthalmology. *Surv Ophthalmol* 1992; 36: 259–284.
9. Miyake K. Nonsteroidal anti-inflammatory agents in cataract intraocular lens surgery [editorial review]. *Curr Opin Ophthalmol* 1995; 6 (1): 62–65.
10. Flach AJ. Topical nonsteroidal anti-inflammatory drugs in ophthalmology. *Int Ophthalmol Clin* 2002; 42 (1): 1–11.
11. Mc Colgin AZ, Heier JS. Control of intraocular inflammation associated with cataract surgery. *Curr Opin Ophthalmol* 2000; 11: 3–6.
12. Goldmann H. Cortisone glaucoma. *Arch Ophthalmol* 1962; 68: 621–626.
13. Mitsui Y, Hanabusa J. Corneal infections after cortisone therapy. *Br J Ophthalmol* 1955; 39: 244–250.
14. Flach AJ. The incidence, pathogenesis and treatment of cystoid macular edema following cataract surgery. *Trans Am Ophthalmol Soc* 1998; 96: 557–634.
15. Milch FA, Yannuzzi LA. Medical and surgical treatment of aphakic cystoid macular edema. *Int Ophthalmol Clin* 1987; 27 (3): 205–217.
16. Huang D, Swanson EA, Lin C-P, et al. Optical coherence tomography *Science* 1991; 254: 1178–1181.
17. Antcliff RJ, Stanford MR, Chauhan DS, et al. Comparison between optical coherence tomography and fundus fluorescein angiography for the detection of cystoid macular edema in patients with uveitis. *Ophthalmology* 2000; 107: 593–599.
18. Puliafito CA, Hee MR, Lin CP, et al. Imaging of macular diseases with optical coherence tomography. *Ophthalmology* 1995; 102: 217–229.
19. La Pianna FG, Penner R. Anaphylactoid reaction to intravenously administered fluorescein. *Arch Ophthalmol* 1968; 79: 161–162.
20. Ozdemir H, Karacorlu S, Karacorlu M. Postoperative subretinal fluid associated with cystoid macular edema following cataract surgery. *Retina* 2005; 25: 223–225.
21. Hrynchak P, Simpson T. Optical coherence tomography: an introduction to the technique and its use. *Optom Vis Sci* 2000; 77: 347–356.
22. Nicholas S, Riley A, Patel H, et al. Correlations between optical coherence tomography measurement of macular thickness and visual acuity after cataract extraction. *Clin Exp Ophthalmol* 2006; 34: 124–129.
23. Massin P, Vicaut E, Haouchine B, et al. Reproducibility of retinal mapping using optical coherence tomography. *Arch Ophthalmol* 2001; 119: 1135–1142.
24. Browning DJ. Interobserver variability in optical coherence tomography for macular edema. *Am J Ophthalmol* 2004; 137: 1116–1117.
25. Riordan-Eva P. Anatomy and embryology of the eye. In: Riordan-Eva P, Whitcher JP, eds, Vaughan & Asbury's *General Ophthalmology* 16th ed. New York, NY, Lange Medical Books/McGraw-Hill, 2004; 1–28.

**AUTHORS:**

1. M. Ramesh Chandra
2. P. Sanjeeva Kumar
3. P. Kishore Kumar
4. D. V. Giddaiah
5. Govardhan Reddy

**PARTICULARS OF CONTRIBUTORS:**

1. Assistant Professor, Department of Ophthalmology, SRMC.
2. Professor, Department of Ophthalmology, SRMC.
3. Assistant Professor, Department of Ophthalmology, SRMC.
4. Professor, Department of Ophthalmology, SRMC.

5. Assistant Professor, Department of Ophthalmology, SRMC.

**NAME ADDRESS EMAIL ID OF THE CORRESPONDING AUTHOR:**

Dr. M. Ramesh Chandra,  
Assistant Professor,  
Department of Ophthalmology,  
Santhiram Medical College & General  
Hospital, Nandyal-518501.  
E-mail: srmcophthal@gmail.com

Date of Submission: 25/12/2014.  
Date of Peer Review: 26/12/2014.  
Date of Acceptance: 29/12/2014.  
Date of Publishing: 03/01/2015.