

## STUDY OF DIFFERENT MODALITIES OF SURGICAL TREATMENT OF DIAPHTSEAL FRACTURES OF FOREARM IN ADULTS

K. Harsha Kumar<sup>1</sup>

### HOW TO CITE THIS ARTICLE:

K. Harsha Kumar. "Study of different Modalities of Surgical Treatment of Diaphtseal Fractures of Forearm in Adults". Journal of Evolution of Medical and Dental Sciences 2015; Vol. 4, Issue 71, September 03; Page: 12340-12349, DOI: 10.14260/jemds/2015/1782

**ABSTRACT: BACKGROUNDS AND OBJECTIVES:** Sixty cases of fracture both bone forearm in adults were operated and fixed using various instruments in Narayana Medical College and Hospital, Nellore. The study period was June 2009 to June 2013. The case were followed up from four months to ten months. **METHODS:** Most of the cases were young adult male with age ranging between 17 to 73 years. The functional outcome of different modalities of surgical treatment of diaphyseal fracture of both bone forearm in adults are interpreted. We have fixed 17 patients with Dcp, 13 patients with Lcdcp, 14 patients with Semitubular plating and 16 patients with Intramedullary nailing. Most cases were operated within three days of injury. Anaesthesia and Tourniquet was used for all cases. Thompsons approach was used for proximal radial fractures and Henrys approach was used for distal radial fractures. Ulna was exposed along its posterior border. Intramedullary nailing was done along radial styloid process and distal tip of olecranon in radius and ulna respectively. Closed reduction under C-arm in intramedullary procedure and open reduction and internal fixation when plating was done. Above elbow p.o.p slab were applied for all operated case. Sutures were removed at 10<sup>th</sup> Post-operative day. Mobilization were started after suture removal in plating cases. In Intramedullary nailing cases mobilization started after clinical and radiological union. **RESULTS:** By Anderson Scoring System out of 14 cases of Dcp 75 % were excellent, 25% were satisfactory. Out of 11 cases of Lcdcp 72.7% were excellent, 18.2% were satisfactory, 9.1% were unsatisfactory. Out of 13 cases of Semitubular plating 69.2% were excellent, 23.1% were satisfactory, 7.7% were unsatisfactory. Out of 14 cases of Intramedullary nailing with Talwakar square nails 42.9% were excellent, 21.4% were satisfactory, 21.4% were unsatisfactory, 14.3% had failure results. **INTERPRETATION AND CONCLUSION:** Open reduction and internal fixation can be considered as the treatment of choice if there were no contraindications for this because it is important to maintain length, opposition, axial alignment and rotation alignment if a good range of movement of forearm is to be restored. This is achieved in the present study.

**KEYWORDS:** Dcp; Lcdcp; Semitubular; Intramedullary; Thompsons; Henry's; Radialstyloid; Olecranon; POP; Talwakar square nail.

### INTRODUCTION: AIMS AND OBJECTIVES OF STUDY:

- To study the functional activity of upper extremity after treatment.
- To study the radiological and functional outcome in different modalities of surgical treatment of diaphyseal fractures of forearm in adults.
- Complications associated with different modalities of treatment.

**METHODOLOGY: METHODS:** Most of the patients presented to hospital within 24 hours of injury of forearm. Only 7 patients presented within a week after sustaining the injury.

## ORIGINAL ARTICLE

90% of the patients presented with injured forearm supported with hand. While 10% patients came with their injured limb immobilized with POP.

On admission of the patient, careful history was elicited from the patient or attendants to reveal the mechanism of injury. The patients were examined clinically for signs of fracture displacements, deformity, neuro vascular status associated injuries and for vital signs.

**Treatment Protocol:** After thorough clinical evaluation x-ray of the affected forearm was taken in both anteroposterior and lateral view including wrist and elbow joints. The limb was immobilized in above elbow slab with positioning the forearm according to the site of fracture with sling.

The patient was taken up for surgery after routine investigations Hb%.

Urine Routine RBS.

Blood grouping and typing HIV/Hbs Ag.

ECG.

### RESULTS:

Age groups (in years)		Sex		Total
		Male	Female	
15-25	Frequency	12	6	18
	Percent	37.5	27.3	33.3
26-35	Frequency	10	2	12
	Percent	31.3	9.1	22.2
36-45	Frequency	6	5	11
	Percent	18.8	22.7	20.4
46-55	Frequency	3	4	7
	Percent	9.3	18.2	13.0
56-65	Frequency	1	3	4
	Percent	3.1	13.6	7.4
66-75	Frequency	0	2	2
	Percent	0	9.1	3.7
Total	Frequency	32	22	54
	Percent	100.0	100.0	100.0

**Table 1: Distribution of sample by age and sex**

CC=0.378; P<0.108 (Non-significant):

Chi-square for age groups alone=19.111; P<0.002 (HS)

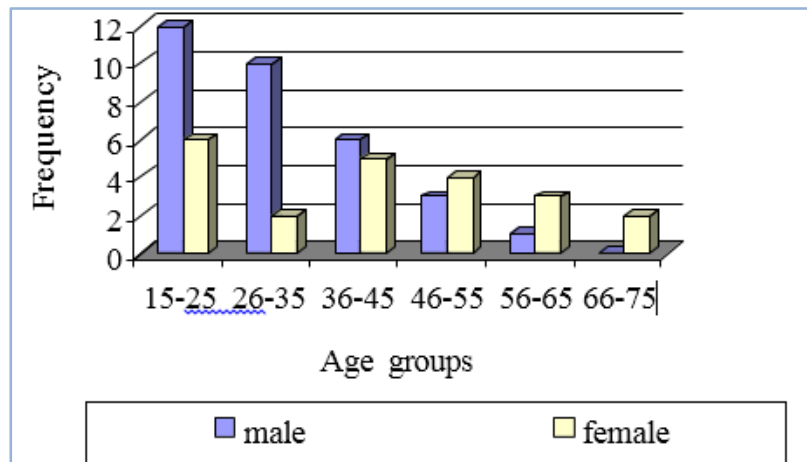
From the above table it is evident that the distribution of male and female cases in various age groups is statistically same. Contingency coefficient of 0.378 was found to be statistically non-significant (P<0.108).

However, when age groups alone considered, a significant chi-square ( $\chi^2=19.111$ ; P<0.002), value was observed, revealing that frequencies of age groups differed significantly.

## ORIGINAL ARTICLE

From the table it is clear that as the age increased, number of cases decreased linearly and significantly. Maximum cases were recorded in the age group of 15-25 (33.3%) and least was in the age group of 66-75 (3.7%). All the values for male and female cases for different age groups are diagrammatically represented in Fig. 20.

**Figure 2:** Frequency of male and female patients in various age groups.



**Fig. 2: Frequency of male and female Patients in Various age Groups**

Implant used		Supination and Pronation		
		<10 <sup>o</sup>	<20 <sup>o</sup>	>20 <sup>o</sup>
DCP	Frequency	12	4	0
	Percent	75.0	25.0	0
LC DCP	Frequency	8	2	1
	Percent	72.7	18.2	9.1
Semi tubular plating	Frequency	9	3	1
	Percent	69.2	23.1	7.7
Intra medullary nail	Frequency	6	3	5
	Percent	42.9	21.4	35.7
<b>Total</b>	Frequency	35	12	7
	Percent	64.8	22.2	13.0

**Table 3: Distribution of sample by implant used and supination and pronation**

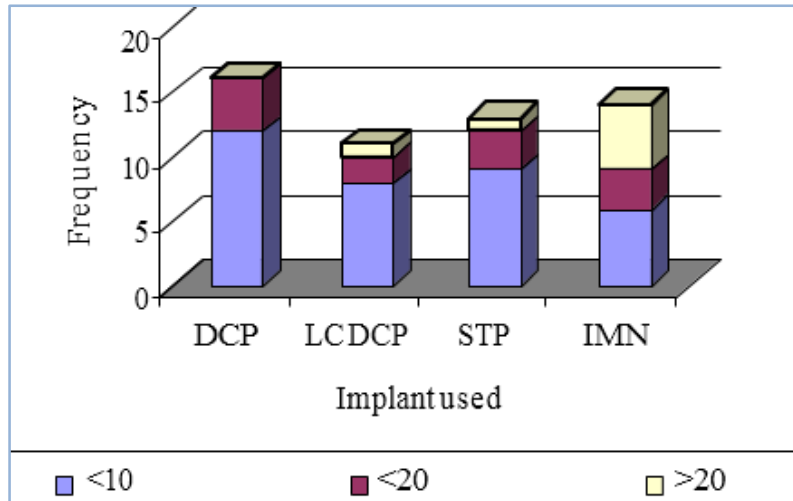
CC=0.390; P<0.140 (Non-significant)

A non-significant association was observed between implant used and Supination and pronation movements (CC=0.390; P<0.140). From the table, it is clear that most of the implants had the supination and pronation <10o. Only few cases in all the implants had the supination and pronation <20. In >20o supination and pronation, one case each was reported from LC-DCP and

## ORIGINAL ARTICLE

semi tubular playing, whereas 5 cases had supination and pronation >20o in IMN. All these frequencies are combined and diagrammatically represented in Fig. 29.

**Fig. 4:** Distribution of sample by implant used and supination and pronation



**Fig. 4: Distribution of sample by implant used and supination and pronation**

**DISCUSSION:** Functional forearm is very essential for an individual for social and economical thriving. Fractures of the forearm bones may result in severe loss of function unless adequately treated. The relationship of the radiohumeral, radioulnar, ulnohumeral radiocarpal, distal radioulnar joint and the interosseous space must be perfect, otherwise some functional impairment will result.<sup>5</sup>

In addition to regaining length, opposition and axial alignment, achieving rotational alignment is necessary, if a good range of pronation and supination is to be restored.<sup>4</sup> Malunion and nonunion occur more frequently because of difficulty in reducing and maintaining reduction of two parallel bones in the presence of the pronating and supinating muscles that have angulatory as well as rotational influences.<sup>50,52</sup> Because of these factors surgical management for displaced diaphyseal fractures in the adult is generally accepted.

In our series 60 patients were treated by different surgical modalities.

Open reduction and internal fixation with dynamic compression plating, limited contact dynamic compression plating, semitubular plating or closed intramedullary nailing using square nail randomly.

In our series 16 patients were treated with dynamic compression plate and screws, 11 patients with limited contact dynamic compression plate and screws, 13 patients with semitubular plate and screws and 14 patients with square nails.

Age incidence

In the present study the age distribution was between 15-75 years. The youngest patient was 17 years and the oldest was 73 years. The commonest age group was 15-25 years (37.3%). The mean age in our study was 30.8 years in male and 41.9 in females.

## ORIGINAL ARTICLE

Series	Minimum Age	Maximum Age	Average Age
Chapman	13	69	33
Herbert Dodge	13	59	24
Moed B.R.	14	65	22
Dhaon	15	70	27
Franckie Le	11	90	36
Our study	17	73	25

Table 5: Comparative age incidence (years).<sup>1,17,61,64</sup>

**Sex Distribution:** Our series had a male preponderance with 59.2 male patients and 40.8 female patients.

Series	Male (%)	Females (%)
H. Dodge	89	11
M. Chapman	78	22
William AT	67	33
Frankie Leung	82.6	17.4
Our study	59.2	40.8

Table 6: Comparative sex distribution series.<sup>1,17,61,62</sup>

**Mode of Injury:** In our series 55.6% cases had road traffic accident (RTA), 37% cases had fall and 7.4% had assault (direct blow). So the commonest mode of injury in our study is by road traffic accidents.

Series	RTA (%)	Fall (%)	Miscellaneous (%)
Moed	70	14	16
Grace	45	22	33
Smith	45	36	19
Our study	55.6	37	7.4

Table 7: Comparative mode of injury series.<sup>1,9,60</sup>

**Side Affected:** In our study the most commonly affect side was right with right side incidence being 64.8% and left side incidence being 35.2%.

Series	Right (%)	Left (%)
H.N. Burwell	50	50
M.W. Hapman	55	45
Our study	64.8	35.2

Table 8: Comparative side affected series

**CONCLUSION:** Increased incidence of forearm fractures were probably due to increasing road traffic accidents and fall.

- Forearm fractures occurred more commonly in second and third decade.

## ORIGINAL ARTICLE

---

- Predominance of males were seen in these fractures.
- Open reduction and internal fixation can be considered as the treatment of choice if there were no contraindications for this because it is important to maintain length, opposition, axial alignment and rotation alignment if a good range of movement of forearm is to be restored. This is achieved in the present study.
- DCP system, LC DCP system or semitubular system gave optimum fixation and allowed immediate mobilization.
- Excellent results were achieved with it in terms of mobility and union without deformity.
- Prophylactic antibiotics before surgery helped in reduction of rate of infection.
- Patients were comfortable and more secure socially without external immobilization after rigid fixation.
- To conclude DCP or LC DCP offers excellent results in displaced diaphyseal fractures of forearm bones in adults and to be considered as first line of management.

Under certain circumstances where patient is not fit for open reduction and internal fixation or where there is need for:

### **Least Invasive Procedure:**

- Technically easy procedure
- Short operating time
- Reduced risk of infection
- Decreased hospital stay
- Economic procedure

Intramedullary nailing with square nails can be considered as first line of management.

**SUMMARY:** Present study consists of 60 cases of diaphyseal fractures of forearm, treated surgically with follow up ranging from 4 months to 10 months. In 6 cases, follow up was not possible, so 54 cases were considered for the study. The age group ranged between 15 to 75 years commonest being 15-25 years. Predominance of males were seen in 32 cases out of 54 cases studied (59.3%). Right side was more common (64.8%) than left side (35.2%).

Road traffic accident was the commonest mode of trauma (55.6%), followed by fall on out stretched hand (37.0%) followed by assault (7.4%). Direct trauma was the main mechanism of injury in these cases.

Middle 3<sup>rd</sup> was the commonest fracture site of both bones (42.6%) followed by junction of middle and lower 3<sup>rd</sup> (31.5%), followed by lower 3<sup>rd</sup> (14.8%), and middle and upper 3<sup>rd</sup> (11.1%). Transverse fracture was the commonest (50%) followed by oblique fracture (25.9%) followed by comminuted fracture (24.1%).

By open reduction and internal fixation, 16 cases were treated with DCP, 11 cases were treated with LCDCP and 13 cases were treated with semitubular plating. By closed reduction and medullary fixation with square nail, 14 patients were treated.

For open reduction, separate incisions were used for radius and ulna

Thompson's approach was used for upper half of radial fractures, Henry's approach for lower half of radial fractures, ulna was exposed by direct approach.

## ORIGINAL ARTICLE

---

For closed reduction and medullary nailing radial styloid was used in 11 patients, lister's tubercle approach was used in 3 patients. Olecranon approach was used to fix all ulna fractures.

The results were based on Anderson et al. scoring system.

In the present study, with dynamic compression plating there were 12 patients (75 %) with excellent results and 4 patients (25%) with satisfactory results.

In limited contact dynamic compression plating, 8 patients (72.7%) with excellent results, 2 patient (18.2%) satisfactory result and 1 patient (9.1%) results were unsatisfactory.

In semitubular plating 9 patients (69.2%) results were excellent, 3 patients (23.1%) with satisfactory results and 1 patient (7.7%) results were unsatisfactory.

Radiological union of fracture occurred in all the cases. The union time of radius and ulna was almost the same.

The unsatisfactory results for limited contact dynamic compression plating and semitubular plating are related to the degree of injury sustained, type of fracture, periosteum stripping, evacuation of fracture haematoma.

By Anderson's Scoring System, with closed reduction and medullary nailing 6 patients (42.9%) showed excellent results, 3 patients (21.4%) satisfactory, In 3 patient (21.4%) unsatisfactory and failure in 2 patients (14.3%).

The reason for non-union was distraction of fracture site after nailing.

In closed reduction and medullary fixation with square nails 1 patient had superficial infection at ulnar portal, 1 patient with deep infection at ulnar portal with implant migration. One patient with delayed union with implant migration and two non-union cases.

### **BIBLIOGRAPHY:**

1. Anderson LD, David Sisk, Robert E. Compression plate fixation in acute diaphyseal fractures of the radius and ulna. *J. Bone and Joint Surg.* 1975; 57-A (3): 287-296.
2. Rush LV. and Rush HL. Evolution of medullary fixation of fractures by the longitudinal pin. *Arm. J. Surg.* 1949; 78: 324-333.
3. Lambrinudi C. Intramedullary Kirchner wires in treatment of fractures. *Proc. Roy. Med. London* 1939; 33: 153-157.
4. Evans EM. Rotational deformity in the treatment of fractures of both bones of the forearm. *J. Bone and Joint Surg.* 1945; 27: 373-379.
5. Patrick, James. A study of supination and pronation with especial reference to the treatment of forearm fractures. *J. Bone and Joint Surg.* 1946; 28: 737-748.
6. Danis R. *Theorie et pratique de osteosynthese*, Paris, Masson 1949; 95-105.
7. Bachynski B. and Smith H. Unpublished data, 1953.
8. Watson Jones P. *Fractures and joint injuries*. Edinburgh, Livingstone, 1947; 4<sup>th</sup> ed.
9. Smith, Hugh and Sage FP. Medullary fixation of forearm fractures. *J. Bone and Joint Surg.* 1957; 31-A: 91-98.
10. Muller ME, Allogower M and Willenegger H. *Technique of internal fixation of fractures*. 1958; New York, Springer.
11. Garland DE and Dowling Veronica. Forearm fractures in head injured adults, *Clinical Ortho.* 1983; 176: 190-196.



## ORIGINAL ARTICLE

---

12. Hidaka, Shigeki and Gustilo RB. Refracture of bones of the forearm after plate removal. *J. Bone and Joint Surg.* 1984; 66-A: 1241-1243.
13. Ghazi Rayan M. and Mark Hayes. Entrapment of flexor digitorum profundus in the ulna with fracture of both bones of forearm. *J. Bone. Joint Surg.* 1986; 68A: 1102-1103.
14. Schatzker J, Horne JG and Sumner Smith G. The effect of movement on the holding power of screws in bone. *Clin. Orthop.* 1975; 111: 257.
15. Moda K, Chaddha NS, Anirodh Aggarwal and Alok Garg, *IJO.* 1988; 22: 22-28.
16. Kirit M. Shah, Pankaj A, Divetia and Rajesh MK. Management of Diaphyseal fractures of forearm bones – Anerolution. *Clinal Orthopaedics India.* 1988; 3: 51-56.
17. Chapman Michael W, Eric Gordonse and Anthony Zissions AG. Compression plate fixation of acute fractures of the diaphyses of the radius and ulna. *J. Bone. Joint Surgery.* 1989; 71A: 159-169.
18. Emil H. Scnemitsch. The effect of malunion on functional outcome after plate fixation of fractures of both bones of forearm in adults. *J. Bone. Joint Surg.* 1992; 74-A (7): 1068-1078.
19. Eggers GWN, Shindler JO and Pomerat CM. The influence of the contact compression factor on osteogeneiss in surgical fractures. *J. Bone and Joint Surg.* 1949; 31A: 693-716.
20. Anderson LC. Compression plate fixation and the effect of different type of internal fixation on fracture healing. *J. Bone and Joint Surg.* 1965; 47-A: 191-208.
21. Jinkins WJ. JR, Lockhart LD, and Eggers, GWN. Fractures of the forearm in adults. *Southern Med. J.* 1960; 53: 669-679.
22. Burwell HN and Charnley AD. Treatment of Forearm Fractures in Adults with Particular Reference to Plate Fixation. *J. Bone and Joint Surg.* 1964; 46-B (3): 404-425.
23. Perren SM, Huggler A, Russenberger M, Allgower M, Mathys B. The Reaction of Cortical Bone to Compression. *Acta. Orthop. Scandinarica, Supplementum.* 1969; 125: 19-29.
24. Anderson LD, Sisk TD, Tooms RE and Park WI. III Compression-Plate Fixation in Acute Diaphyseal Fractures of the Radius and Vena. *J. Bone and Joint Surg.* April 1975; 57-A: 287-297.
25. Rai P.K., and Sharma R.N., Treatment of forearm fractures by compression plating. *Indian Journal of Orthopaedics.* 1981; 15(1): 55-58.
26. Perren SM. et al. The concept of biological plating using the limited contact dynamic compression plate (LC-DCP). *Injury* 1991; 22(1): 1-41.
27. Mcknee MD, Seiler JG. And Jupiter JB. The application of limited contact dynamic compression plate in the upper extremity. Analysis of 114 consecutive cases. *Injury*, 1995; 26(10): 661-666.
28. Robert Soeur. Intramedullary pinning of diaphyseal fractures of forearm *J.B.J.S.* Apr. 1946; 28(2): 309-31.
29. Walter G. Stuck and Milton S. Thompson. Treatment of fractures of forearm with intramedullary pins. *American Journal of Surgery.* Jan. 1949; 77(12): 12-17.
30. Knight RA. And Purvis GD. Fracture of both bones of forearm in adults. *J.B.J.S.* 1949; 31-A: 755.
31. Robert C. Robertson. Intramedullary fixation of fractures of forearm. *American Journal of Surgery.* 1953; 496.
32. Sage FP. Medullary fixation of forearm fractures. *J.B.J.S.* 1959; 41-A: 1489.
33. Marek FM. Axial fixation of forearm fractures. *J.B.J.S.* 1961; 43-A (8): 1900-1114.



34. Talwalkar AK. Treatment of simple fracture of radius and ulna with internal fixation without external support. *Ind. J. Ortho.* Jun 1967; 1(1): 26-30.
35. Pandey S. Square nailing and immediate use of limb in forearm fractures. *Int. Surg.* 1973; 58(1): 20-3.
36. Mukherjee DJ. Intramedullary nailing in fractures of long bones. *J.I.M.A.* 1979; 73(12): 212-5.
37. Street DM. Intramedullary forearm nailing. *C.O.R.R.* 1986; 212: 219-30.
38. Moda SK, Chadda NS, Anirodh Kocchar et al. Management of forearm fractures by open reduction and internal fixation with Talwalkar's square nails. *Ind. J. Ortho.* 1988; 22(1): 22-28.
39. Patwa JJ, Vaidya DD. A study of 200 consecutive cases of closed intramedullary nailing of radius and ulna. *Ind. J. Ortho.* 1990; 24 (2): 169-72.
40. Winkler S, Brug E. et al. *Unfallchirurg.* 1991; 94(7): 335-41.
41. Depedro JC, Garcia-Navarrete, Delucas FG. et al. Internal fixation of ulnar fracture by locking nail. *C.O.R.R.* 1992; 283: 81.
42. Sajeeva Kumar, Krishna Nair, Behera BK. and Pathi KM. Role of internal fixation in segmental fractures of forearm bones. *Ind. J. Ortho.* Sep. 1994; 28(3): 45-47.
43. Moerman J, Lenaert A. et al. Internal fixation of forearm fractures in adults. *Acta. Orthop. Belg.* 1996; 62(1): 34-40.
44. Buhroo AM. Primary internal fixation of fracture both bones of forearm by intramedullary nailing. *Ind. J or Ortho.* Oct. 1998; 32(4).
45. Sargent JP, and Teipner WA. Treatment of forearm shaft fractures by double- plating. A preliminary report. *J. Bone and Joint Surg.* 196; 47-A: 1475-1490.
46. Teipner WA, and Mast JW. Internal fixation of forearm diaphyseal fractures: Double plating versus single compression (Tension band) plating – A comparative study. *Orthop. Clin. North America*, 1980; 11: 381-91.
47. Ronald W. Lindsey, Theodore Miclau, Christian Foglar. *Forearm Fractures.* *J Trauma.* 3.34: 1957-1967.
48. Snell RS. *Clinical anatomy.* Lippincott Williams and Wilkins, 2004; 7<sup>th</sup> Ed.
49. Paley D, Murtry R. Median Nerve Compression by Volarly Displaced Fragments of the Distal Radius. *Clinical Orthopaedics.* 1987; 215: 139-147.
50. Terrycanale S. *Campbell's operative orthopaedics.* Mosby, 2003; 10<sup>th</sup> Ed.
51. Jon C. Thomson *Netter's Concise Atlas of Orthopaedic Anatomy.* Icon learning systems publishers. 2000; 1<sup>st</sup> Ed.
52. Sarmiento MD, Jack A. Cooper, William FS. Forearm fractures, early functional bracing - A preliminary report. *J Bone and Joint Surg.* 1975; 57-A (3): 297-303.
53. Texhammar R, Colton C. *AO/ASIF. Instruments and Implants.* Springer-Verlag Berlin Heidelberg 1994; 2<sup>nd</sup> Ed.
54. Hoppenfield S, Piet de Boer. *Surgical exposure in orthopaedics.* Jaypee brother's medical publishers, 2004; 3<sup>rd</sup> Ed.
55. Peter J. Stern, William J. Drury. *Complications of Plate Fixation of Forearm Fractures.* *Clinical Orthopaedics.* 1983; 175: 25-29.
56. Chapman W. Michael, Michael Mahoney. *Clinical Orthopaedics.* 1979; 138: 120-130.
57. Kirsten GB Elliott, Alan J Johnstone. Diagnosing Acute Compartment Syndrome. *J. Bone and Joint Surg.* 2003; 85(B) (5): 625-630.

## ORIGINAL ARTICLE

58. Srinath Kamineni, FRCS (Ortho), Bernard F Morrey MD, Proximal radial resection for post-traumatic Radioulnar synostosis. A new technique to improve forearm rotation. J. Bone and Joint Surg. 84-A(5)
59. Shigeki Hidaka MD and Ramon B Gustilo MD, Refracture of bones of the forearm after plate removal. 1984; 66-A (8): 1241-1243.
60. Smith JEM. Internal fixation in the treatment of Fractures of the shafts of the Radius and Ulna in adults. J Bone and Joint Surg. 1959; 41-B (1):122-131.
61. Chapman W Michael, Eric Gordon J, Anthony G Zissimos. Compression-plate fixation in acute diaphyseal fractures of the Radius and Ulna. J Bone and Joint Surg. 1975; 57-A (3): 287-296.
62. Dodge HS and Cady GW. Treatment of fractures of the Radius and Ulna with Compression plates. A Retrospective study of one hundred and nineteen Fractures in seventy eight patients. J Bone and Joint Surg. Sept. 1972; 45-A: 1167-1176.
63. Perren SM, Physical and biological aspects of fracture healing with special reference to internal fixation. Clinical Orthopaedics. 1979; 138: 175-194.
64. Dhaon BK, Dhari AK and Makhani JS. Osteosynthesis in Forearm Fracture. Indian Journal of Orthopaedics. 22(1): 27-31.

**AUTHORS:**

1. K. Harsha Kumar

**PARTICULARS OF CONTRIBUTORS:**

1. Associate Professor, Department of Orthopaedics, Narayana Medical College, Nellore, Andhra Pradesh.

**FINANCIAL OR OTHER**
**COMPETING INTERESTS:** None

**NAME ADDRESS EMAIL ID OF THE CORRESPONDING AUTHOR:**

Dr. K. Harsha Kumar,  
Associate Professor,  
Department of Orthopaedics,  
Narayana Medical College,  
Nellore, Andhra Pradesh.  
E-mail: drharshaortho@gmail.com

Date of Submission: 11/08/2015.  
Date of Peer Review: 12/08/2015.  
Date of Acceptance: 28/08/2015.  
Date of Publishing: 01/09/2015.