

STUDY OF EFFECTIVENESS OF LENS EXTRACTION AND PCIOL IMPLANTATION IN PRIMARY ANGLE CLOSURE GLAUCOMASudhakar Rao P¹, K. Revathy², T. Sreevathsala³**HOW TO CITE THIS ARTICLE:**

Sudhakar Rao P, K. Revathy, T. Sreevathsala. "Study of Effectiveness of Lens Extraction and PCIOL Implantation in Primary Angle Closure Glaucoma". Journal of Evolution of Medical and Dental Sciences 2015; Vol. 4, Issue 27, April 02; Page: 4605-4611, DOI: 10.14260/jemds/2015/667

ABSTRACT: The role of lens extraction as a treatment for angle closure has been considered with the aim of preventing the development of glaucomatous optic neuropathy at a later stage. This study was undertaken to examine the effectiveness of Lens extraction with PCIOL implantation in the treatment of primary angle closure glaucoma in govt. Regional Eye Hospital, Kurnool. In this study lens extraction with PCIOL implantation has proved to be effective in widening the drainage angle and reducing intra ocular pressures and good visual outcome. Thus lens extraction as a primary surgical approach in patients with primary angle closure disease may therefore be curative and a safe procedure with few or no complications.

KEYWORDS: Glaucoma, lens extraction, PACG, PAC.

INTRODUCTION: Primary Angle Closure Glaucoma (PACG) is a condition in which elevation of IOP occurs as a result of obstruction of aqueous outflow by partial or complete closure of the angle by peripheral iris. Angle Closure Glaucoma occurs when enough of trabecular meshwork is occluded. Recent epidemiological studies have borne out that angle closure glaucoma is almost as common as or more common than open angle glaucoma in South and East Asia and in Indian population. Asians will represent 47% of those with glaucoma, and 87% of those with angle closure glaucoma.¹

Glaucoma blindness is more common with PACG than PAOG. The crystalline lens has a pivotal role in primary angle closure (PAC), both in the pathogenesis of pupil block and by exacerbating the effect of non-pupil block mechanisms such as peripheral iris crowding. Eyes with angle closure tend to have shallow anterior chambers and thick, anteriorly positioned lens when compared with normal eyes. Removing the lens creates more space in the anterior chamber and widens the angle, which may be enough to achieve intraocular pressure (IOP) control.

The role of lens extraction as a treatment for angle closure has been debated for many years. With the knowledge that the lens is the single most important contributing factor to the angle closure process, and having acquired the technology and skills to perform relatively safe small incision cataract surgery, should we now be thinking about performing lens extraction in angle closure patients with the aim of preventing the development of glaucomatous optic neuropathy at a later stage.

This study was undertaken to examine the effectiveness of Lens extraction with PCIOL implantation in the treatment of primary angle closure glaucoma in the patients attending to the department of Ophthalmology, Govt. Regional Eye Hospital, Kurnool.

METHODS: A prospective clinical study was undertaken to evaluate the effectiveness of lens extraction by small incision cataract surgery and posterior chamber IOL implantation under local anesthesia for the management of PACG. The entire preoperative evaluations, operative procedures

ORIGINAL ARTICLE

and the postoperative follow ups were carried out at Regional Eye Hospital, Kurnool, Andhra Pradesh. The study was carried out from January 2011 to June 2012, total number of subjects being 25. Out of 25 patients, 15 underwent surgery and were followed up for 3 months.

The Ethics Committee of the institute approved the study. Informed consent was taken from all the patients. The inclusion criteria were primary Angle Closure Glaucoma, Primary Angle Closure (PAC) with IOP > 30 mm Hg, angle Closure (Irido trabecular contact) in 180° or more. The definitions of occludable angle and manifest PACG were again based on definitions suggested by the ISGEO. Subjects with complete synechial angle closure and glaucomatous optic atrophy and secondary angle closure glaucoma excluded from the study group. Visual acuity tested by snellen's chart, slit-lamp biomicroscopy examination was done. Intraocular Pressure was measured with Goldmann Applanation tonometer and the median of three tonometer readings was recorded as the final IOP.

Gonioscopy was performed with Goldmann 3 mirror gonioscopy lens. Dynamic [Indentation] gonioscopy using Zeiss four mirror gonioscopy lens was used to assess the presence or absence of peripheral anterior synechiae [PAS] in each quadrant and to distinguish from appositional angle closure. Optic nerve head examination using 90D lens with slit lamp biomicroscopy. Visual field examination was done using Humphrey automated field analyzer. Preoperative A-scan was performed for the measurement of anterior chamber depth, lens thickness, and axial length, and for IOL power calculation. Keratometry readings were noted with Baush & Lomb keratometer in the greatest & least curved meridians of the cornea.

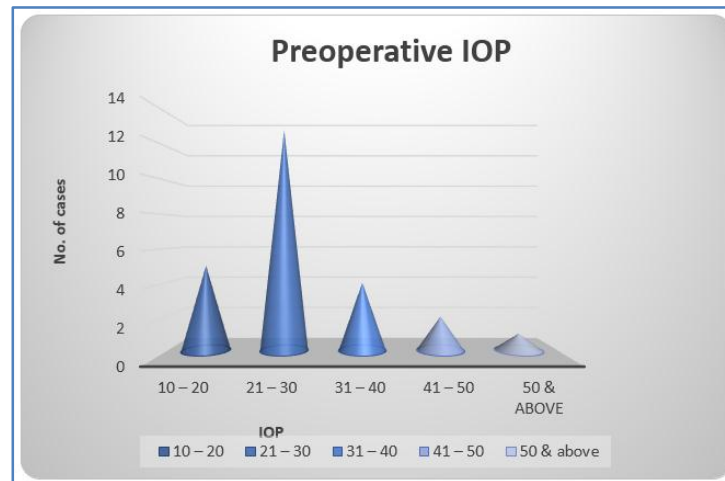
Upon presentation, APAC cases were initially managed by drugs in order to reduce IOP. This consisted of oral acetazolamide, topical pilocarpine, timolol, and betamethasone or prednisolone acetate. If the IOP did not reduce with this standard treatment, other medications such as intravenous mannitol, oral glycerol, topical latanoprost, or brimonidine were added. Once the acute episode had resolved, with reduction of IOP, with improved corneal clarity, subjects underwent subjective refraction and measurement of Visual acuity, gonioscopic examination of angle width and configuration, optic nerve head examination was done. Following medical treatment, the patients underwent small incision cataract surgery with posterior chamber IOL implantation with a single piece PMMA Intra Ocular Lens under local anesthesia. A special attention was paid not to give scope for the factor of variation in efficacy and skill of the operating hands, hence the surgery was entirely performed for all cases by one surgeon.

All patients were monitored postoperatively for visual acuity using Snellen's acuity chart, and with pin hole at every follow up, retinoscopy and refraction done at 6 weeks. Intraocular pressure was checked with Goldmann applanation tonometry on the first and seventh postoperative days & every follow up. Anterior chamber angle width was measured using gonioscopy lens. Postoperatively, all patients had clinically clear cornea. All patients were followed up postoperatively after 1 week, 2 weeks, 4 weeks, 6 weeks, and at 3 months

DISCUSSION: Classic reports suggest that PACG occurs with greatest frequency in the sixth and seventh decades of life but is seen a decade earlier in South East Asian population. In this study most of the patients were 51 to 60 years (48%) age group. The next common age group were 61 to 70 years (32%). There were only 5 patients in less than 50 years age group. Among the patients included in the study 21 (84%) were females and 4 (16%) were males indicating a 4:1 ratio of female to male preponderance. In this study PACG is more common in females and they present at early age

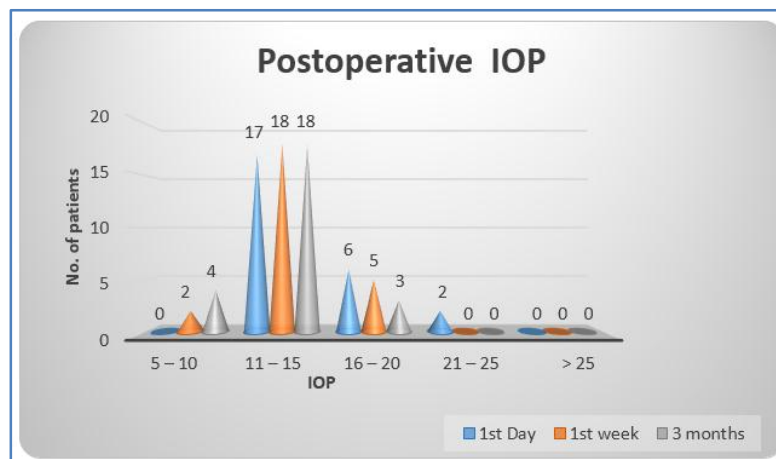
ORIGINAL ARTICLE

compared to males. Out of 25 patients, 14 patients (56%) had primary angle closure with glaucomatous optic neuropathy (creeping), 9 (36%) patients with primary angle closure (acute & sub-acute), 2 (8%) were primary angle closure suspects. Out of 25, most of the patients 13 (52%) had IOP in the range of 21 – 30mm Hg, and 5 (20%) had an IOP of 10 – 20mm Hg, 4 (16%) patients had IOP in the range of 31 – 40mm Hg, 2 (8%) patients presented with 41 – 50 mm Hg. 1 (4%) patient had an IOP of above 50 mm Hg.



In the study, of 14 patients with PACG (creeping), had good control of IOP at follow up visits, with 2 patients continued on topical medications to maintain IOP in the low teens, to halt further progression of glaucomatous optic neuropathy.

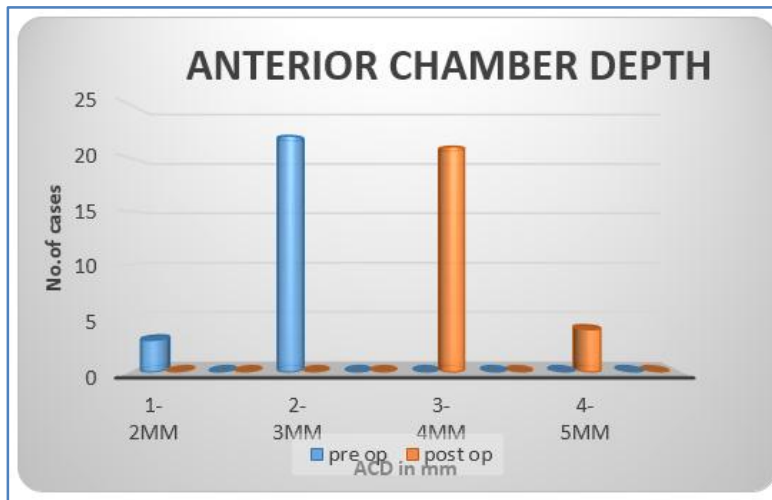
Among PAC (acute & sub-acute) patients had IOP levels in the normal range in the postoperative period and during follow up. 2 PACS eyes also had IOP with in normal limits and none of them suffered symptomatic angle closure in the follow up period.



The mean preoperative IOP was 28.52 mm Hg. Mean postoperative IOP 13.64 mm Hg at 3 months of follow up. Anterior chamber depth was measured preoperatively and post operatively.

ORIGINAL ARTICLE

Mean anterior chamber depth preoperative was 2.22 +/- 0.2 mm which improved after surgery to 3.8 +/- 0.3 mm.



There was a definite improvement of 2 and more Shaffer's grade of angle of anterior chamber in all 25 patients. The Peripheral anterior synechiae were stable in these patients during follow up and no new or fresh PAS have been noted. Best corrected visual acuity was 6/6 in 15 patients suggesting a 60% achieved very good vision. 32% were in the range of 6/9 - 6/12. One patient had 6/18 and one patient had 6/24, both had features early age related macular degeneration.

Visual Acuity	Preoperative (No. of Cases)
CF 5m & less	5
6/60 - 6/36	15
6/24 - 6/18	5
6/12 - 6/9	--
6/6	--

Table 1: Preoperative visual acuity

Visual Acuity	Postoperative (No. of Cases)	
	1 st day	BCVA
6/6	6	15
6/12 - 6/9	10	8
6/24 - 6/18	7	2
6/60 - 6/36	2	--
< 6/60	--	--

Table 2: Postoperative visual acuity

ORIGINAL ARTICLE

DISCUSSION: In this study most of the patients were 51 to 60 years (48%) age group. The next common age group were 61 to 70 years (32%). Ichhpujani et al. (Indian J Ophthalmol 2010;58 (3): 199-203) studied 814 patients with ACG and found that mean age at presentation was significantly higher for males (57.57 ± 11.62 years) as compared to females (53.64 ± 10.67 years). Our study included 14 (56%) patients with primary angle closure with glaucomatous optic neuropathy (creeping), 9 (36%) patients with primary angle closure (acute & sub-acute),² (8%) primary angle closure suspects. Ichhpujani et al. (Indian J Ophthalmol 2010; 58 (3): 199-203)³ studied 814 patients with ACG and found that PACG was found to be the most frequently diagnosed subtype (49.38%), followed by PAC (39.68%) and PACS (10.93%).

In a population based study Hyderabad, India, Thomas and coworkers⁴ showed that, over a 5 year period, the risk of progression from narrow angles (PAC suspects) to acute angle closure with elevated IOP or synechiae (PAC) was 22% but none of their patients actually developed optic nerve damage (PACG). But, of 337 cases of same population with PAC followed for 5 years, the risk of progressing to actual PACG was 28%. In our study, Mean preoperative IOP was 28.52 mm Hg. Mean post-operative IOP 13.64 mm Hg at 3 months of follow up as compared to Dada T et al (2011)⁵ Mean preoperative IOP was 25.0 +/- 5.4 mm Hg Mean post-operative 15.8 +/- 3.8 mm Hg at 3 months.

IOP	Mean pre op IOP	Mean post op IOP	Duration
Our Study	28.52 mm Hg	13.64 mm Hg	3 months
Dada T et al (2011) ⁵	25.0 +/- 5.4 mm Hg	15.8 +/- 3.8 mm Hg	3 months
Imaizumi (2006) ⁶	49 mm Hg	13 mm Hg	6 months
	17 mm Hg	14 mm Hg	6 months
Gunning FP, Greeve EL (1998) ⁷	27.9 mm Hg +/- 8.1	17.1 +/- 2.9 mm Hg	53 months
Philipp C. Jacobi (2002) ⁸	40.5 +/- 7.6 mm Hg	17.8 +/- 3.4 mm Hg	10.2 +/- 3.4 months
Hayashi (2001) ⁹	21 mm Hg	15 mm Hg	25 months
Roberts (2000) ¹⁰	39 mm Hg	17 mm Hg	36 months
Greve et al (1988) ¹¹	31 mm Hg	16 mm Hg	6 months

Table 3: PREOPERATIVE AND POSTOPERATIVE IOP CONTROL

In the study, mean lens thickness was 4.83 +/- 0.30 mm. Philip C Jacobi et al.¹² Reported preoperative mean lens thickness as 5.06 +/- 0.44mm. According to Bhatia LM, Panda A, Sood NN et al,² the lens was found to be thicker in cases of angle closure glaucoma (5.28 mm) as compared to the controls (4.30 mm). Mean anterior chamber depth preoperative was 2.22 +/- 0.2 mm which improved after surgery to 3.8 +/- 0.3 mm.

ACD	Mean pre op ACD	Mean post op ACD
Our Study	2.22 mm	3.8 mm
Nonaka et al (2006) ¹²	2.03+0.30 mm	3.39+0.21 mm
Philipp C. Jacobi (2002) ⁸	2.30+0.64 mm	3.70+0.38 mm
Ken Hayashi et al (2000) ¹³	1.89+0.33 mm	3.94+0.26 mm
Yang et al (1997) ¹⁴	2.04 mm	3.44 mm`

Table 4: Anterior chamber depth

ORIGINAL ARTICLE

In our study, Mean preoperative IOP was 28.52 mm Hg. Mean post-operative IOP 13.64 mm Hg at 3 months of follow up. All patients had good control of IOP in the normal range. None of them had IOP spikes during follow up period. Best corrected visual acuity, 60% patients achieved (6/6) very good vision. 32% were in the range of 6/9 – 6/12. One patient had 6/18 and one patient had 6/24, both had features early age related macular degeneration.

In my study, Lens extraction with PCIOL implantation has proved to be effective in widening the drainage angle and reducing intra ocular pressures and good visual outcome.

This suggested that thickened and anteriorly placed lens plays a major factor in the pathogenesis of pupil block. Hence Lens extraction as a primary surgical approach in patients with primary angle closure disease may therefore be curative and a safe procedure with few or no complications.

REFERENCES:

1. Quigley H, Broman AT. The number of people with glaucoma worldwide in 2010 and 2020. *Br J Ophthalmol.* 2006; 90: 262 – 7.
2. Ultrasonic measurements of ocular components in angle closure glaucoma; Bhatia LM, Panda A, Sood NN, *IJO* 1983, 31; 7: 823-826.
3. Ichhpujani P, Pandav SS, Ramasubramanian A, Kaushik S. Profile of angle closure in a tertiary care center in north India. *Indian J Ophthalmol* 2010; 58: 199-203.
4. Thomas R, et al: Five-year risk of progression of primary angle closure to primary angle closure glaucoma: a population-based study, *Acta Ophthalmol Scand* 81: 480, 2003. Angle closure glaucoma. *Ophthalmology.* 1999; 106: 669 –74.
5. Dada T, Mohan S, Panda A, et al. Ultrasound biomicroscopic assessment of angle parameters in patients with PACG undergoing phacoemulsification. *Eur J Ophthalmol* 2011 sep-oct; 21 (5): 559-65.
6. Imaizumi M, Takaki Y, Yamashita H. Phacoemulsification and intraocular lens implantation for acute angle closure not treated or previously treated by laser iridotomy. *J Cataract Refract Surg.* 2006; 32: 85 – 90.
7. Gunning FP, Greve EL. Lens extraction for uncontrolled angle-closure glaucoma: long-term follow-up. *J Cataract Refract Surg.* 1998; 24: 1347 – 56.
8. Jacobi PC, Dietlein TS, Luke C, et al. Primary phacoemulsification and intraocular lens implantation for acute angle closure glaucoma. *Ophthalmology.* 2002; 109: 1597 - 603.
9. Hayashi K, Hayashi H, Nakao F, Hayashi F. Effect of cataract surgery on intraocular pressure control in glaucoma patients. *J Cataract Refract Surg* 2001; 27: 1779–86.
10. Roberts TV, Francis IC, Lertusumitkul S, et al. Primary phacoemulsification for uncontrolled angle-closure glaucoma. *J Cataract Refract Surg.* 2000; 26: 1012– 6.
11. Greve EL. Primary angle closure glaucoma: extracapsular cataract extraction or filtering procedure. *Int Ophthalmol.* 1988; 12: 157 – 62.
12. Nonaka A, Kikuchi et al. Angle widening and alteration in ciliary process configuration after cataract surgery in primary angle closure. *Ophthalmology* 2006; 113: 437 – 41.
13. Hayashi K, Hayashi H, Nakao F, Hayashi F. Changes in anterior chamber angle width and depth after intraocular lens implantation in eyes with glaucoma. *Ophthalmology.* 2000; 107: 698 – 703.

ORIGINAL ARTICLE

14. Yang CH, Hung PT. Intraocular lens position and anterior chamber angle changes after cataract extraction in eyes with primary angle-closure glaucoma. J Cataract Refract Surg. 1997; 23: 1109 – 13.

AUTHORS:

1. Sudhakar Rao P.
2. K. Revathy
3. T. Sreevathsala

PARTICULARS OF CONTRIBUTORS:

1. Professor, Department of Ophthalmology, Kurnool Medical College.
2. Associate Professor, Department of Ophthalmology, Kurnool Medical College.
3. Post Graduate, Department of Ophthalmology, Kurnool Medical College.

FINANCIAL OR OTHER

COMPETING INTERESTS: None

NAME ADDRESS EMAIL ID OF THE CORRESPONDING AUTHOR:

Dr. K. Revathy,
80/63-3-A,
Krishna Nagar,
Kurnool-518002,
Andhra Pradesh.
E-mail: revathydhanaraju@gmail.com

Date of Submission: 04/02/2015.

Date of Peer Review: 05/02/2015.

Date of Acceptance: 14/03/2015.

Date of Publishing: 31/03/2015.