

CASE REPORT

TRICHOBEZOAR

Sanjeev Suman¹, Pramood Kumar², Babita³, G.N. Singh⁴

HOW TO CITE THIS ARTICLE:

Sanjeev Suman¹, Pramood Kumar, Babita, GN Singh. "Trichobezoar". Journal of Evolution of Medical and Dental Sciences 2013; Vol2, Issue 47, November 25; Page: 9195-9200.

INTRODUCTION: A bezoar is a mass of undigested material within the gastrointestinal tract and are classified according to the material of which they are composed (1). The term "bezoar" is derived from Arabic "badzehr" or from Persian "panzehr", both meaning counter poison and antidote(2). Bezoar may be classified as Trichobezoar (mass of hair), Phytobezoar (vegetable fiber), Diospyrobezoar (persimmons), Lactobezoar (inspissated milk), Pharmacobezoar (tablets/semiliquid mass of drugs) & miscellaneous (1, 8, 10).

Trichobezoar commonly occurs in stomach, and when extends into the duodenum, the proximal small intestine or the ascending colon it is called RAPUNZEL SYNDROME (3). Rapunzel syndrome is named after a beautiful long haired girl name Rapunzel in a German fairy tale by Grimm brothers (published in 1812) in which Rapunzel let her long golden hair down the prison in the castle over which her lover prince climbed upon to rescue her(4,5).

It mostly seen in young female (<30yr) having present or past h/o trichotillomania & trichophagia. Trichotillomania may be unconsciously or unintentionally done and is part of the DSM IV psychiatric classification of impulse control disorder (6, 7). One third of patient with trichophagia develop trichobezoar (6). The site of hair pulling is most commonly from the scalp, but can occur from the eyelashes, eyebrows and pubic area (8).

OBJECTIVE: To highlighten the ultrasonographic features (in empty as well as in water filled stomach), along with Barium study, & CT scan feature of Trichobezoar.

MATERIALS & METHODS: A review was made of the clinical, radiological and surgical finding in four consecutive patients with gastrointestinal bezoar during period of April 2012 to 1st week of June 2013.

All patients underwent ultrasonography in empty as well as in waterfilled stomach and confirmed by either barium study or CT scan and finally verified surgically. All patients were young female (15-22yr) with a variably long history (10months-2year) of intermittent abdominal pain, post prandial gastric fullness, nausea, occasional vomiting, weight loss, and abdominal lump. Past history revealed two patients had trichotillomania & trichophagia. On query family member mentioned the same for rest two.

Physical examination revealed two patients were underweight and malnourished having short & fuzzy hair but rest two were average built with long and dense hair on scalp. On abdominal palpation, a firm to hard, slightly mobile, mildly tender, & non pulsatile lump of variable size was felt in epigastric region which was dull on percussion. Rest of the abdomen was tympanitic & bowel sound normal on auscultation.

REVIEW LITERATURE: Trichobezoar is the most common type of bezoar and mainly occur in young female. The first case was reported by Baudomant in 1779. In 1938 DeBakey and ochsher reported

CASE REPORT

311 cases of bezoar where they reported that the occurrence of trichobezoar in women is 90%, 80% were <30 year of age. (6, 10).

Trichobezoar commonly occur in stomach, when it extends to the duodenum, the proximal intestine or to the ascending colon it is called Rapunzel syndrome(3,4,5).It is caused by the presence of indigestible substance in the lumen, gastric dysmotility including previous surgery like vagotomy and partial gastrectomy, some substance that encourage stickiness & concretion formation increase the incidence. About 10% of patient has shown psychiatric abnormalities or mental retardation (6, 7).

Trichobezoar continue to grow in size with continued ingestion and these increase the risk of severe complication. The common of these complications include gastric mucosal erosion, ulceration and perforation in 8% cases as well as obstruction, intestinal intussusceptions, obstructive jaundice, protein losing enteropathy, pancreatitis & death (10, 13, 16). It is also associated with diarrhoea, vitamin B-12 deficiency secondary to bacterial overgrowth by colonization of bezoar. Recurrence is usually resulting of gastric hypomotility due to vagotomy or diabetic neuropathy (9, 15, and 16).

The imaging finding is helpful in diagnosing trichobezoar. Conventional radiography shows a mass of soft tissue opacity in a dilated stomach. A calcified rim may delineate the edge of bezoar (9, 12).

Upper G.I series shows mottled filling defect and positive density of mass with a lacelike pattern due to residual contrast medium on delayed phase (9, 10).

In ultrasonography, it appears curvilinear bright echogenic band with marked posterior acoustic shadow over the left upper quadrant. The high echogenicity of hair and the presence of multiple acoustic interfaces created by trapped air and food, limits the ability of ultrasonography in detecting trichobezoar (12, 14).

CT scan is the most useful diagnostic tool in patients with bezoar. It demonstrates a large mesh like intraluminal mass of lower attenuation. The mass can contain trapped air or contrast material and may demonstrate concentric ring (14-16).

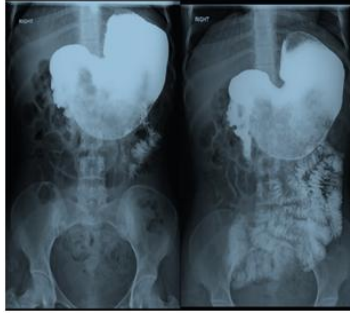
Recently MR imaging recommended for the evaluation of small bowel disease. The magnetic resonance appearance of gastric trichobezoar may vary according to its relative contents of air, fat, water, or residual retained food. It may demonstrate a gastric mass with mottled or confluent low signal intensity on the T1-weighted, T2-weighted, and fat-suppressed T2-weighted images owing to the presence of air; increased signal intensity on the T1- and T2-weighted images because of water or food trapped within the bezoar; and foci of higher signal intensity on the T1-weighted and inversion-recovery images because of fat (11). Foci of inflammation due to gastritis or ulceration and perforation can also be detected (10, 16). Fast imaging technique developed coupled with advantages of breath- holding improved MRI visualisation of bezoars. Therefore MRI is found to be better support for determining both the site & the cause of small bowel obstruction (10-12).

RESULTS:

BARIUM STUDY: Revealed a large filling defect within the stomach with a mottled appearance.

BARIUM MEAL: Large filling defect within the stomach with mottled pooling of barium along the outer margins of the lesion.

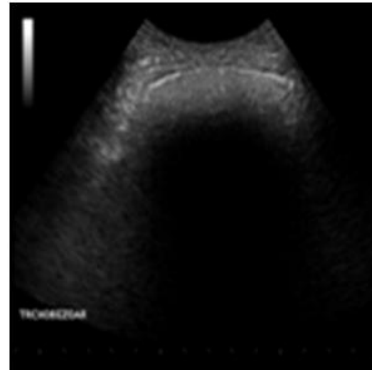
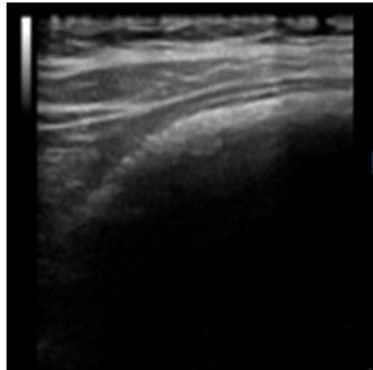
CASE REPORT



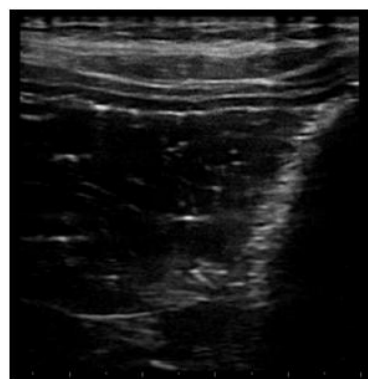
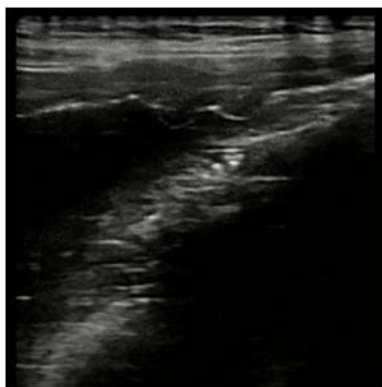
ULTRASONOGRAPHY: Abdominal ultrasonography: - Mass showed curvilinear bright echogenic band with marked posterior acoustic shadow. Other abdominal visceral organ appears normal.

On empty stomach, mass & stomach wall was not delineated well due to marked acoustic shadow.

In water filled stomach (gastro hydrosonography) margin of mass showed multiple floating echogenic fibrous strands in the lumen of stomach with well appreciation of wall of stomach.

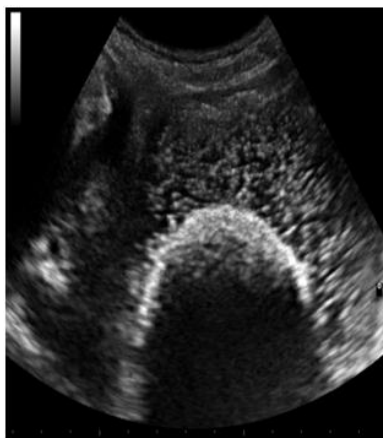
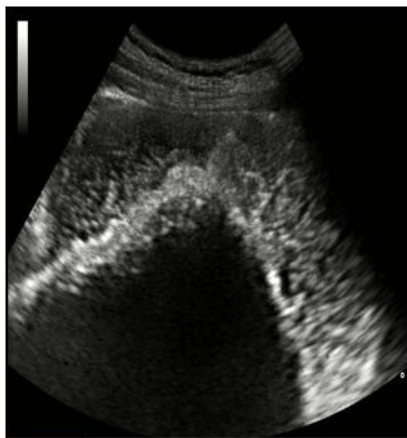


In empty stomach: Bezoar shows echogenic band with marked acoustic shadow (in two different patient)



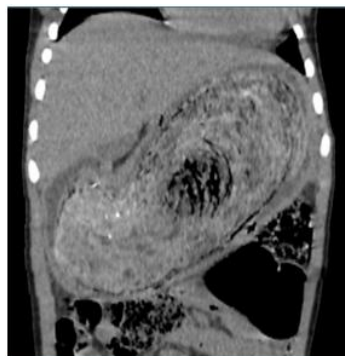
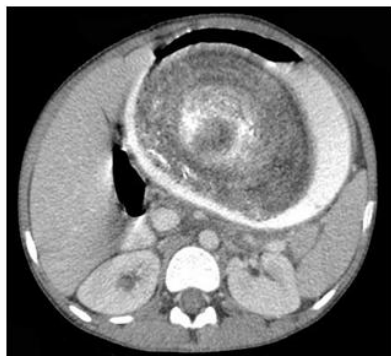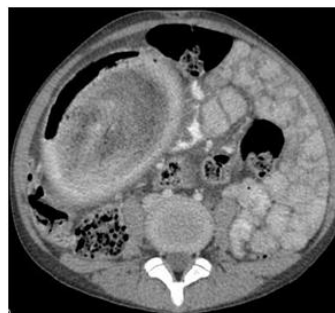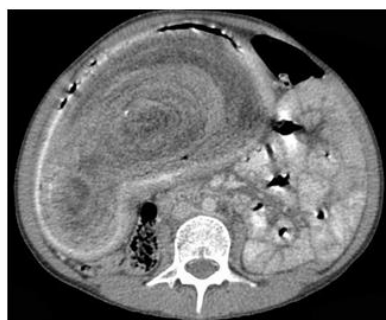
In water filled stomach:Trichobezoar shows multiple floating echogenic fibrous strands in the stomach lumen arising from the echo poor mass. (Its large size restricts the appreciation of its whole outline).

CASE REPORT



In water filled stomach: Moderate (above) & Small (lower) size bezoar appears as globular mass with echogenic peripheral and echo poor central part in gastric lumen with well appreciation of its outline (in two different patients).

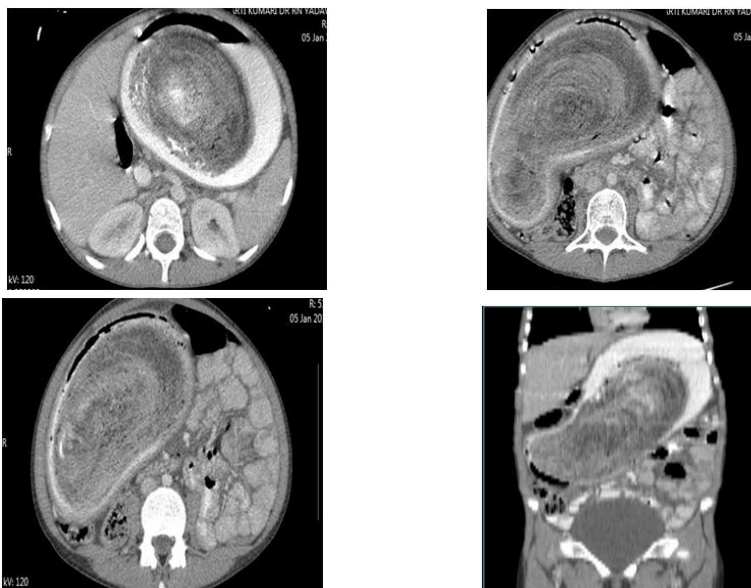
CT Scan: Revealed a well circumscribed lesion within the stomach that comprised of concentric whorls of different densities with pockets of air enmeshed within it. Oral contrast filled the more peripheral interstices of the lesion with sparse contrast within the mesh.



NCCT: well circumscribed lesion in the stomach comprised of concentric whorls of mixed densities with pocket of air enmeshed within it. (Axial & coronal reformation).

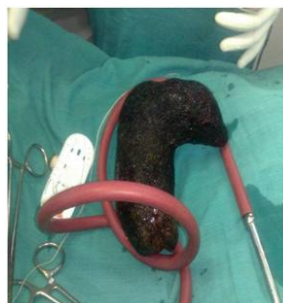
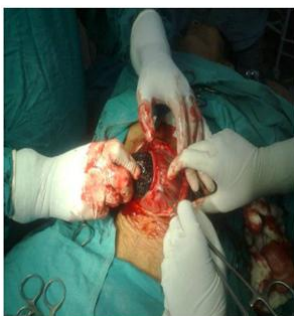
CASE REPORT



CECT with oral positive contrast:-thin band of contrast circumscribing the peripheral part of lesion (Axial & coronal reformation).

Operative photographs of Trichobezoar:



CONCLUSIONS: Trichobezoar should be considered as a differential diagnosis in a young female patient with mobile epigastric mass. Ultrasonography in empty stomach raises the difficulty in diagnosis, but in water filled stomach (gastro-hydrosonography) it is fairly well appreciated. It appears as a large peripherally echogenic mass casting marked acoustic shadow in the lumen. Outline of mild and moderate size bezoar can be well appreciated. Some of them shows multiple floating echogenic fibrous strands arising from the margin of trichobezoar. However CT best describe the size, configuration & location of bezoar, and also differentiate from other pathologies viz.-intra or extra gastric neoplasm.

REFERENCES:-

1. Filipi CJ, Perdakis G, Hinder RA, DeMeester TR, Fitzgibbons RJ, Peters J. An intraluminal approach to the management of gastric bezoars. Surg Endosc 1995; 9:831-833.
2. Williams RS. The fascinating history of bezoars. Med J Aust 1986; 145: 613-614.
3. Saleem Naik, Vivek Gupta, Swati Naik, Ashwin Rangole, Ashok K. Chaudhary, Prashant Jain, Ashok K. Sharma: Rapunzel Syndrome Reviewed and Redefined. Dig Surg 2007; 24:157-161.

CASE REPORT

- Mohite PN, Gohil AB, Wala HB, Vaza MA: Rapunzel Syndrome Complicated with Gastric Perforation Diagnosed on Operation Table. *J Gastrointest Surg* 2008.
- Mohammed E. Rabie et al, Rapunzel syndrome: The unsuspected culprit, *World J Gastroenterol* 2008 February 21; 14(7): 1141-1143
- Salaam K, Carr J, Grewal H, et al. Untreated Trichotillomania and Trichophagia. Surgical Emergency in a Teenage Girl. *Psychosomatics*. 2005.46(4):362-366.
- Ellis CR, Roberts JH, Schnoes CJ. Anxiety disorder, trichotillomania. [Internet] *Emedicine* 2009 [updated 2009 Sep 23] Available from emedicine.medscape.com/article/915057.
- Hoovera K, Piotrowski J, Pierreb K, et al. Simultaneous gastric and small intestinal trichobezoars-A hairy problem. *J Pediatr Surg*. 2006. 41(8):1495-1497.
- Eisenberg RL, Levine MS. Miscellaneous abnormalities of the stomach and duodenum. In: Gore RM, Levine MS, editors. *Gastrointestinal radiology*, 3rd edn. Philadelphia, USA: Saunders, 2008; 679-706.
- Billaud Y, Pilleul F, PJ Valette. Bezoar. Small bowel. Obstruction. CT scan. *J Radiol*. 2002; 83:641-6.
- Lee JM, Jung SE, Kyo-Young Lee KY, Small-Bowel Obstruction Caused by Phytobezoar: MRI Imaging Finding. *American Roentgen Ray Society AJR*. 2002;179:538-539.
- Dimonopoulos PA, Pech P, Thuomas KA, Kaniklides C. Trichobezoar: a multi-modality evaluation. *Eur Radiol* 1992; 2:159-163.
- Navab F, Saboi J. Trichobezoars. *N Engl J Med* 1997; 336:1721.
- Ripolle's T, Garcí'a-Aguayo J, Martí'nez M-J, Gil P. Gastrointestinal bezoars: sonographic and CT characteristics. *AJR Am J Roentgenol* 2001; 177:65-9.
- Gorter RR, Kneepkens CMF, Mattens ECJL, Aronson DC, Heij HA. Management of trichobezoar: case report and literature review. *Pediatr Surg Int*. 2010; 26: 457- 63.
- Khattala K, Boujraf S, Rami M, Elmadi A, Afifi A, Sbai H, Harandou M, Bouabdallah Y. Trichobezoar with small bowel obstruction in children: Two cases report. *Afr J Paediatr Surg*. 2008; 5:48- 51

AUTHORS:

- Sanjeev Suman
- Pramood Kumar
- (Mrs) Babita
- (Prof.) G.N. Singh

PARTICULARS OF CONTRIBUTORS:

- Senior Resident, Department of Radiodiagnosis, Patna Medical College Hospital.
- Post Graduate, Department of Radiodiagnosis, Patna Medical College Hospital.
- Tutor, Department of Microbiology, Patna Medical College.

- H.O.D., Department of Radiodiagnosis, Patna Medical College Hospital.

NAME ADDRESS EMAIL ID OF THE CORRESPONDING AUTHOR:

Dr. Sanjeev Suman,
Department of Radiodiagnosis,
Patna Medical College Hospital,
Nalanda Scan Center, 0/63, Doctor's Colony,
Kankarbagh, Patna - 800020, Bihar.
Email - drbabitasmn@gmail.com

Date of Submission: 05/11/2013.

Date of Peer Review: 06/11/2013.

Date of Acceptance: 16/11/2013.

Date of Publishing: 21/11/2013