

**ROLE OF PRP AND STEM CELL INJECTIONS IN OSTEOARTHRITIC PATIENTS OF KNEE JOINT**P. L. Srinivas<sup>1</sup>, P. Phani Kumar<sup>2</sup>**HOW TO CITE THIS ARTICLE:**

P. L. Srinivas, P. Phani Kumar. "Role of PRP and Stem Cell Injections in Osteoarthritic Patients of Knee Joint". Journal of Evolution of Medical and Dental Sciences 2015; Vol. 4, Issue 54, July 06; Page: 9468-9474, DOI:10.14260/jemds/2015/1370

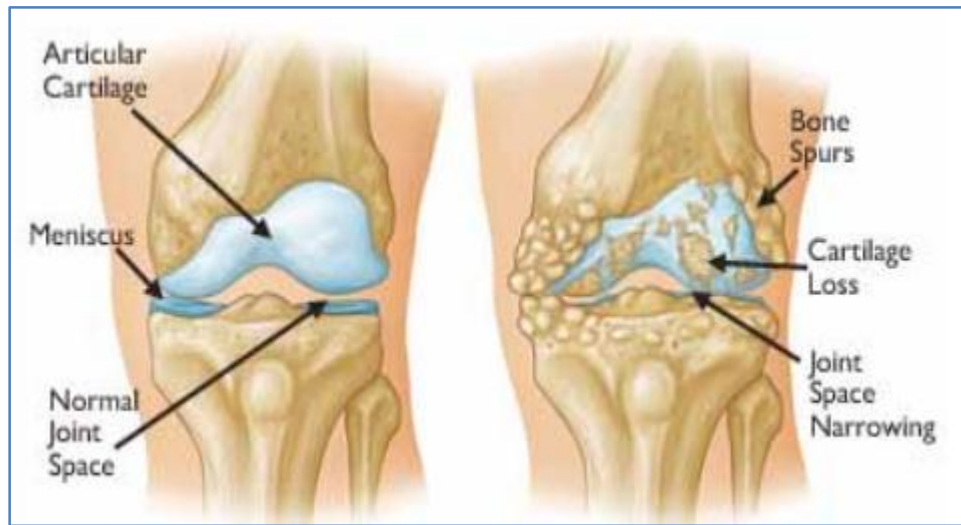**ABSTRACT: INTRODUCTION:** Osteoarthritis of the knee (also called degenerative joint disease and osteoarthrosis) (4) is the most common joint disease after 50 years of age. It is characterized by progressive loss of articular cartilage (4) with subchondral bone sclerosis, osteophyte formation, inflammation of synovial membrane, and an increase in the synovial fluid with decreased viscosity and lubrication properties. One approach to regenerative therapy is to supply affected joints with either autologous chondrocytes or chondrogenic bone marrow-derived mesenchymal stem cells (9) (BMSC) in combinations with platelet rich plasma. **MATERIALS AND METHODS:** In our study we treated 65 cases of osteoarthritis of knees in different age groups. In our study moderate to severe arthritis cases were studied. Among 65 cases, 45 were females, 20 were males. Among the test group of 65 cases of age group ranging to 56-87yrs, 45 patients were with unilateral knee joint involvement, 10 patients were with bilateral knee joint involvement. On the other side a Control group consists of 50 cases: 30 with unilateral knee joint involvement, 10 patients with bilateral knee joint involvement. **RESULTS:** Both the groups were observed from time to time and analyzed based on the pain scores at 3 days, 1 week, 4 weeks, 3 months and 6 months intervals. At 3days- No difference in the pain scores and mobility noted in both the groups. At 1 week- Improvement in pain scores with increase in mobility reported in 59 of 65 cases in test group. On the other side, improvement in pain scores reported in 41 of 50 cases in control group. At 4 weeks- Improvement in pain scores reported in 63 of 65 cases in test group. And 44 of 50 cases in control group. At 3 months- Improvement in pain scores reported in 62 cases in test group and 30 cases in control group. At 6 months- Improvement in pain scores reported in 56 cases in test group and 26 cases in control group. **CONCLUSION:** PRP and stem cells injections in to the osteoarthritic knees, produces good results and safe. If the patient is not opting for surgical procedures and this is the only better treatment modality for controlling the pain and improvement of joint function. Hence use of PRP and stem cells injections in osteoarthritic patients is great value in preventing the further damage of the cartilage. By repairing the damaged cartilage with the PRP and stem cells, pain is greatly reduced, increase in the function of joint and patients will have better quality of life.

**KEYWORDS:** PRP and Stem Cells, Osteoarthritis, Knee Joint.

**INTRODUCTION:** Osteoarthritis of the knee (Also called degenerative joint disease and osteoarthrosis)<sup>(1)</sup> is the most common joint disease after 50 years of age. It is characterized by progressive loss of articular cartilage<sup>(1)</sup> with subchondral bone sclerosis, osteophyte formation, inflammation of synovial membrane, and an increase in the synovial fluid with decreased viscosity and lubrication properties. It is one of the most common form of arthritis and the major cause of disability and reduced activity in people older than 50 years.<sup>(1)</sup>

## ORIGINAL ARTICLE

**Fig. 1:** (Left) Normal joint space between the femur and the tibia. (Right) Decreased joint space due to damaged cartilage and bone spurs.



**Fig. 1**

No specific therapy has yet been clearly shown to prevent the progression of osteoarthritis but the main purpose of treatment is to reduce pain,<sup>(1)</sup> increase function and improve the quality of life. Patient satisfaction is a fundamental goal in treating osteoarthritis of the knee joint. Surgical interventions for patients with Osteoarthritis are generally reserved for those who have failed less invasive modes of therapy.<sup>(1)</sup> Surgeons can choose from a variety of surgical procedures, depending on patients age, the joint involved, functional expectations, patient activity demands, and degree of cartilaginous loss. The development of percutaneous interventions that potentially enhance regenerative processes has improved the prospect for non-surgical treatments that may produce durable improvement in pain and function. One approach to regenerative therapy is to supply affected joints with either autologous chondrocytes or chondrogenic bone marrow-derived mesenchymal stem cells<sup>(2)</sup> (BMSC) in combinations with platelet rich plasma.

**MATERIALS AND METHODS:** In this case series, we describe our experience with a simple, cost-effective regenerative treatment using direct injection of bone marrow derived mesenchymal stem cells into osteoarthritic joints in combination with Platelet rich plasma. This study includes observation of selected 65 chronic pain of knee involving degenerative arthritis of varying degrees of severity between, study conducted since 2012 to 2014. Depending on the joint space narrowing and osteophytes they are categorized into mild moderate and severe arthritis cases. In our study we treated 65 cases of osteoarthritis of knees in different age groups. In our study moderate to severe arthritis cases were studied. Among 65 cases, 45 were females, 20 were males.

**Among the Test Group of 65 Cases of Age Group Ranging to 56-87 yrs:** 45 cases were with unilateral knee joint involvement, 10 cases (20 knee joints) were with bilateral knee joint involvement.

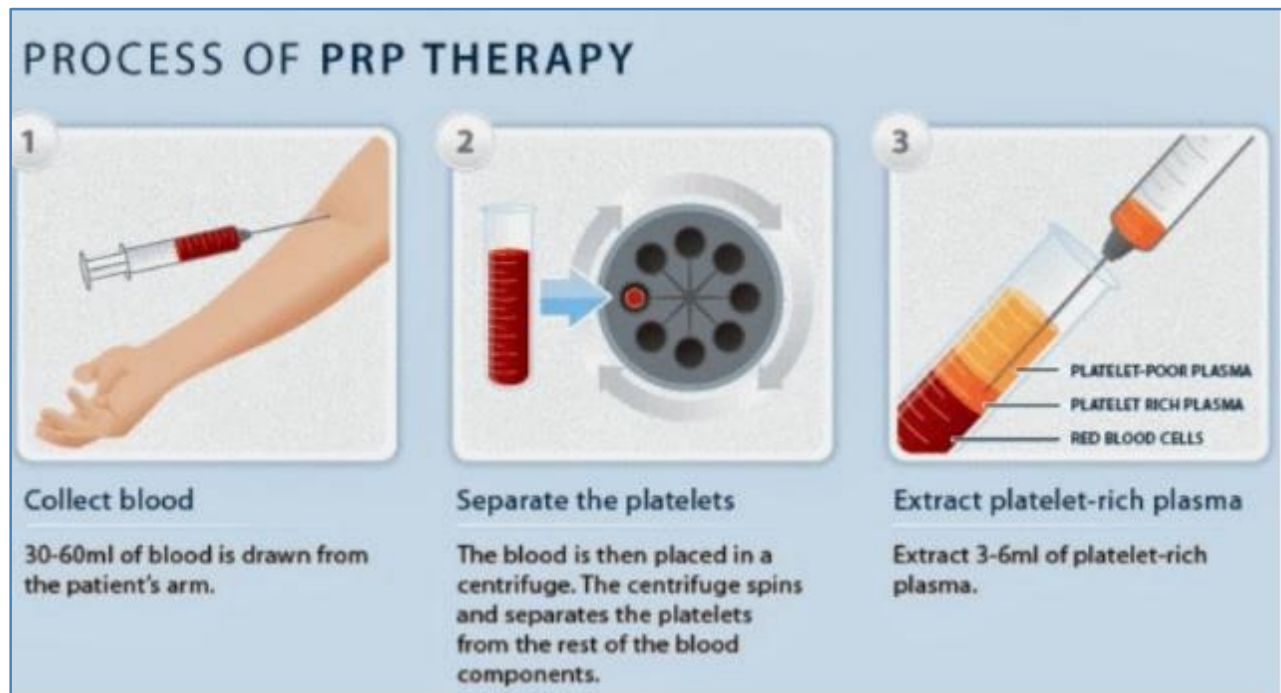## ORIGINAL ARTICLE

**On the other Side a Control Group Consists of 50 Cases:** 30 with unilateral knee joint involvement, 10 cases (20 knees joints) with bilateral knee joint involvement. Control group are treated with corticosteroid injection (Triamcinolone).

All the patients in both the control and test group were undergoing medical management and physical therapy.

**Procedure:** PRP is obtained by standard centrifuge method and Stem cells are obtained from the iliac crest aspiration. This also contains PRP<sup>(3)</sup> (both procedures done under strict aseptic conditions in the operating room). Using 22ml of whole blood typically produces 3ml of PRP and while 60 ml of whole blood will produced 7 to 10 ml of PRP. The PRP is essentially bactericidal. The only organism that PRP does not seem to have bactericidal effects on include Klebsiella Pneumoniae, Enterococcus and pseudomonas.<sup>(4)</sup>

**Test Group:** The selected joint is thoroughly washed with Betadine solution. The Preparation area is extended beyond the joint area to 12 inches proximally and 12 inches distally. Sterile drapes were applied over the area followed by injection of 7cc of PRP mixed with 3cc of stem cell preparation in to the select joint along with 5cc of 0.5% preservative free bupivacaine, under strict aseptic precautions. Sterile bandages were applied after the injection followed by mobilization immediately after the procedure. Control group: A similar procedure is performed in the control group with 10cc of 0.5% bupivacaine, with 60mg of Triamcinalone and the joints were mobilized immediately.



**Fig. 2**

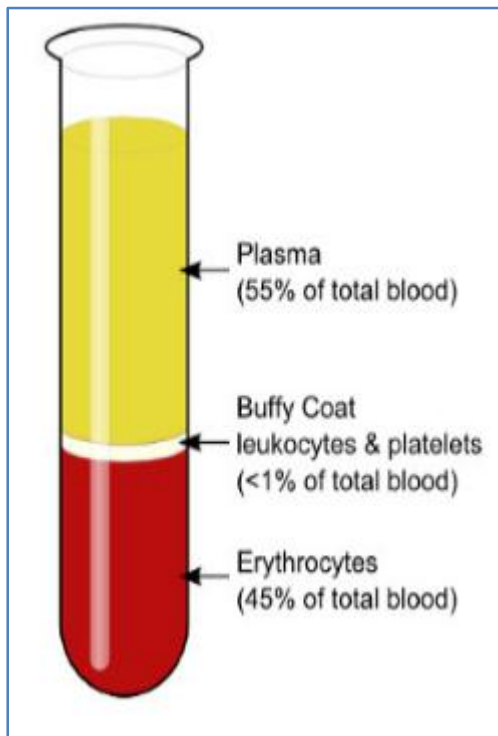


Fig. 3

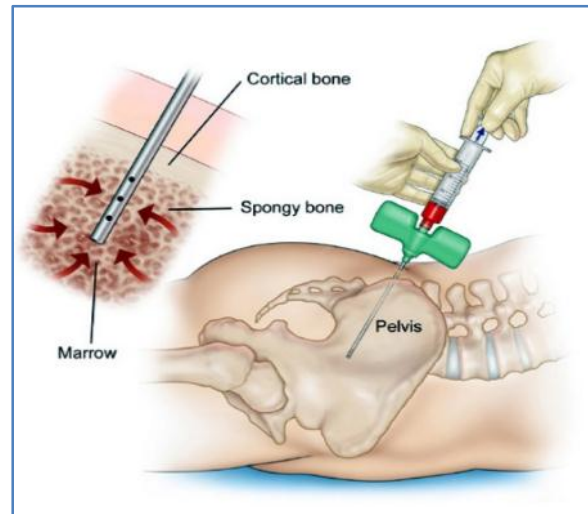


Fig. 4

**Fig. 4:** Technique of obtaining bone marrow derived mesenchymal stem cells from iliac crest.

**RESULTS:** Both the groups were observed from time to time and analyzed based on the pain scores at 3 days, 1 week, 4 weeks, 3 months and 6 months intervals.

**At 3days:** No difference in the pain scores and mobility noted in both the groups.

**At 1 week:** Improvement in pain scores with increase in mobility reported in 59 of 65 cases of knee joints in test group. On the other side, improvement in pain scores reported in 41 of 50 cases of knee joints in control group.

**At 4 weeks:** Improvement in pain scores reported in 63 of 65 cases of knee joints in test group. And 44 of 50 cases in control group.

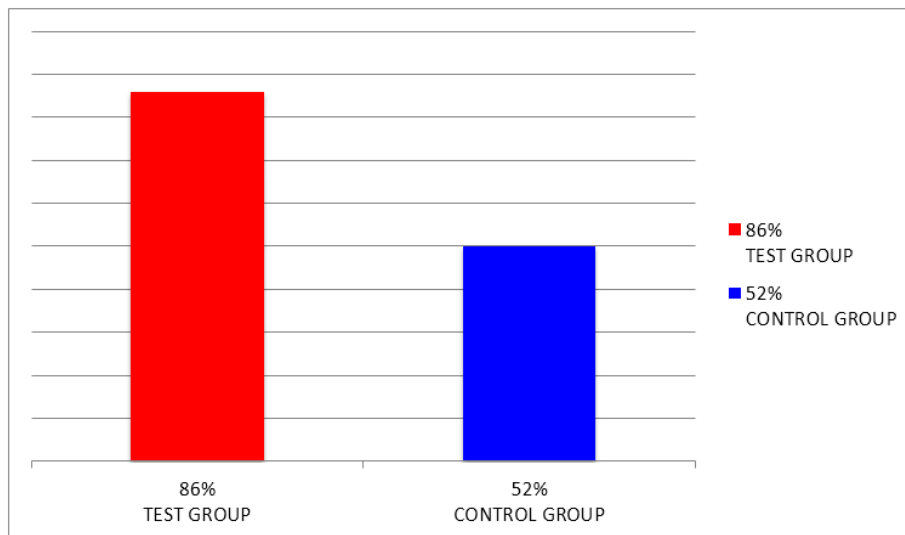
**At 3 months:** Improvement in pain scores reported in 62 cases of knee joints in test group and 30 cases of knee joints in control group.

**At 6 months:** Improvement in pain scores reported in 56 cases of knee joints in test group and 26 cases of knee joints in control group.

Overall, the aggregate improvement in Test group is statistically significant at 3 months and 6 months compared to the control group. At the end of 6 months improvement in pain which was the main goal of the study was noticed in 86% of patient treated with Stem cell derived from bone marrow combined with PRP and in 52% of patients treated with Steroid injections.

## ORIGINAL ARTICLE

**Fig. 5:** Final Results: 86% of test group had improvement in pain and function of knee joint and 52% of control group had improvement and pain and function of the knee joint at the end of the 6 months.



**Fig. 5**

**DISCUSSION:** For many orthopedic and sports injuries and other conditions mainly including arthritis, regenerative therapy using platelet-rich plasma (PRP)<sup>(5,6)</sup> injections with stem cells<sup>(3)</sup> is a highly effective alternative to surgery that promotes a natural process within the body. Stem cell regenerative injection therapy works by releasing the growth factors in the injured site or arthritic joint.<sup>(3)</sup>

Stem cells can be taken from two sources- fat or bone marrow. Stem cells from bone marrow are a better source for more severe orthopedic issues and injuries. Stem cells obtained from the blood of bone marrow called as mesenchymal stem cells (MSC) are the main source for the growth of the cartilage in the arthritic joint.<sup>(3,2)</sup> mesenchymal stem cells are multi-potent stem cells that can differentiate into a variety of cell types during tissue repair processes.<sup>(3)</sup> They majorly differentiate collagen secreting cells, bone forming osteoblasts and cartilage forming chondrocytes. These stem cells are then combined with PRP cells to create an autologous regenerative injection.<sup>(3)</sup>

Platelets from the PRP initiate the repair<sup>(7,5,6)</sup> and attract the assistance of stem cells along with aiding the process of differentiation into chondrogenic cells. Platelets are the body's primary source of bioactive tissue growth factors which facilitate the natural healing process of regeneration and remodeling of the damaged area.<sup>(8)</sup> The secretion of certain growth factors like Connective tissue growth factor (CTGF), Platelet derived growth factor (PDGF),<sup>(3)</sup> Transforming growth factor-beta (TGF- $\beta$ ),<sup>(3)</sup> Epidermal growth factor (EGF),<sup>(3)</sup> Insulin Growth factor (IGF), Basic Fibroblast growth factor (BFGF) and Vascular endothelial growth factor (VEGF) strongly assist in the natural healing process.<sup>(3)</sup> The secretion of VEGF-A inhibits cartilage regeneration which adds up to the benefit profile. Studies show that PRP therapy induces the production of new collagen by the fibroblasts, bone, and cartilage cells at the site of injection, rebuilding the joint cartilage and strengthening the injured ligaments and tendons.<sup>(8,9)</sup> This new collagen naturally incorporated directly into existing cartilage and ligaments make them thicker, stronger and more elastic.

## ORIGINAL ARTICLE

---

It approximately takes six weeks for significant repair to occur, for the pain to diminish and for the patients to return to their physical activity but realistically it takes two to three months for complete recovery to occur.

**Quick Comparison:** After this brief discussion about the mesenchymal stem cells and PRP injection, a quick comparison between the Mesenchymal stem cells +PRP therapy and steroid therapy can justify this study.

Some studies in nonhuman primates suggest that steroid effect on human joints is transient<sup>(10)</sup> and long term use or repeated injections can cause degeneration of tendon tissue or cartilage. Steroids are powerful anti-inflammatory substances<sup>(10)</sup> and hence reduce the inflammation at the joints abolishing the pain without repairing the defect, which permit the patient to overwork the involved joint further damaging the cartilage and bone giving rise to a Charcot- like or neuropathic arthropathy. While on the other hand mesenchymal stem cells and PRP Injections work in a completely different aspect by initiating the healing process which is most required.

In the Cochrane<sup>(11)</sup> review of trials shows that, intra articular corticosteroid injections are more effective in the early weeks of injection for controlling pain and improving the function of the joint.<sup>(11)</sup>

In the recent studies, konetal<sup>(6)</sup> treated 150 patients with PRP giving better results than hyaluronic acid in reducing pain and symptoms and recovering the articular function up to 6 months. In clinical studies to date, PRP is safe with no serious complications reported. Minor adverse events associated with repeated intra articular injections have been moderate pain, swelling and mild effusion that lasted for a few days.<sup>(7,6)</sup>

To sum up, studies indicates that PRP is promising for relieving pain, improving knee function and quality of life.<sup>(7)</sup>

**CONCLUSION:** PRP and stem cells injections in to the osteoarthritic knees, produces good results and safe. If the patient is not opting for surgical procedures and this is the only better treatment modality for controlling the pain and improvement of joint function. Hence use of PRP and stem cells injections in osteoarthritic patients is great value in preventing the further damage of the cartilage. By repairing the damaged cartilage with the PRP and stem cells, pain is greatly reduced, increase in the function of joint and patients will have better quality of life.

### REFERENCES:

1. Nigel Arden, Francisco Blanco, Cyrus Cooper, Ali Guermazi, Daichi Hayashi, David Hunter, M. Kassim Javaid, Francois Rannou, Frank.w. Roemer, Jean-Yves Reginster. Atlas of Osteoarthritis. Springer. 2015. Page.no.21-30, 38-51, 55-65, ISBN 9781910315163.
2. Brandt KD, Dieppe P, Radin E (January 2009). "Etiopathogenesis of osteoarthritis". *Med. Clin. North Am.* 93 (1): 1–24, xv. doi:10.1016/j.mcna.2008.08.009. PMID 19059018.
3. Joseph Purita, Boca Raton, FL USA Chapter from Anti-Aging Therapeutics Volume XIII – The use of stem cells and platelet rich plasma injections in practice- July 2005.
4. Bielecki TM, Gazdzik TS, Arendt J, Szczepanski T Krol W, Wielkoszynski T. Antibacterial Effect of autologous platelet gel enriched with growth factors and other active substances: an vitro study. *J Bone joint surg Br.* 2007; 89: 417-420.

## ORIGINAL ARTICLE

5. Li M, Zhang C, Ai Z, Yuan T, Feng Y, Jia W- Therapeutic effectiveness of intra -knee articular injection of platelet rich plasma on knee articular cartilage degeneration, *Zhongguo Xiu Fu Chang Jian Wai Ke Za Zhi* 2011 Oct; 25(10): 1192-6.
6. Kon E, Mandelbaum B, Buda R, Filardo G, Delcogliano M, Timoncini A, Fornasari PM, Giannini S, Marcacci M. Platelet-rich plasma intra-articular injection versus hyaluronic acid visco supplementation as treatments for cartilage pathology: from early degeneration to osteoarthritis *Arthroscopy*. 2011 Nov; 27(11): 1490-501. doi: 10.1016/j.arthro.2011.05.011. Epub 2011 Aug 10.
7. Filardo G, Kon E, Di Martino A, Di Matteo B, Merli ML, Cenacchi A, Fornasari PM, Marcacci M. Platelet-rich plasma vs hyaluronic acid to treat knee degenerative pathology: study design and preliminary results of a randomized controlled trial - *BMC Musculoskelet Disord*. 2012 Nov 23; 13: 229. doi: 10.1186/1471-2474-13-229.
8. Technology Brief platelet rich plasma for the treatment of knee osteoarthritis-Health PACT August 2013.
9. Filardo G, Kon E, Pereira Ruiz MT, Vaccaro F, Guitaldi R, Di Martino A, Cenacchi A, Fornasari PM, Marcacci M. Platelet-rich plasma intra-articular injections for cartilage degeneration and osteoarthritis: single- versus double-spinning approach. *Knee Surg Sports Traumatol Arthrosc*. 2012 Oct; 20(10): 2082-91. Epub 2011 Dec 28.
10. Ted A. Lennard, pain procedures in clinical practice 2<sup>nd</sup> Edition 2000, page 3-5.
11. Bellamy N, Campbell J, Robinson V, Gee T, Bourne R, Wells G: Intraarticular corticosteroid for treatment of osteoarthritis of the knee. *Cochrane Database Syst Rev*. 2006 Apr 19; (2): CD005328.

### AUTHORS:

1. P. L. Srinivas
2. P. Phani Kumar

### PARTICULARS OF CONTRIBUTORS:

1. I/C Professor and HOD, Department of Orthopaedics & Pain Management, Srivenkata Hospital & Pain Management Centre, S. P. Nagar, Kukatpally, Hyderabad, Telangana.
2. Interventional Pain Specialist, Department of Orthopaedics & Pain Management, Srivenkata Hospital & Pain Management Centre, S. P. Nagar, Kukatpally, Hyderabad, Telangana.

### FINANCIAL OR OTHER

**COMPETING INTERESTS:** None

### NAME ADDRESS EMAIL ID OF THE CORRESPONDING AUTHOR:

Dr. P. L. Srinivas,  
I/C Professor and HOD,  
Department of Orthopaedics,  
RIMS, Kadapa, Andhra Pradesh.  
E-mail: drplsvas@yahoo.co.in

Date of Submission: 15/06/2015.  
Date of Peer Review: 16/06/2015.  
Date of Acceptance: 29/06/2015.  
Date of Publishing: 06/07/2015.