

## MESCENTRIC LYMPHADENITIS IN CHILDREN PRESENTING WITH ABDOMINAL PAIN.

Vinod Jacob<sup>1</sup>, A S Krishna Kumar<sup>3</sup>

### HOW TO CITE THIS ARTICLE:

Vinod Jacob, AS Krishna Kumar. "Mesentric lymphadenitis in children presenting with abdominal pain". Journal of Evolution of Medical and Dental Sciences 2013; Vol. 2, Issue 47, November 25; Page: 9190-9194.

**ABSTRACT:** Mesenteric Lymph nodes are frequently visualized by sonography in pediatric patients. The purpose of this study was to evaluate the incidence of the appearance of enlarged mesenteric nodes, in pediatric patients who were referred for abdominal pain of various causes. **METHODS:** Of the 500 patients who were referred for abdominal pain of various causes, the presence of enlarged nodes, their location, size and other sonological findings were recorded. The patients were divided into two groups. One is those with abdominal pain, due to an acute abdominal condition and those without an acute abdominal condition. The study was carried out in a one year period of March 2010, to March 2011. **RESULTS:** Enlarged lymph nodes > 5 mm were detected in 25 % of the asymptomatic patients and 27.2% of the patients presenting with abdominal pain. On the basis of this study, mesenteric lymphadenitis should be used for the specific inflammation of the nodes in the appropriate clinical setting. Our study also showed that the 90% of the lymph nodes were seen in the right lower quadrant followed by the left lower quadrant and in the peri-aortic region. Another observation that was made was that – the incidence of enlarged lymph nodes increase with age with the peak incidence at around 5 years and decrease thereafter. **CONCLUSION:** Enlarged lymph nodes are frequently seen in pediatric patients who are referred for abdominal pain. Mesenteric lymph nodes more than 5mm on their long axis in children presenting with abdominal pain represent Mesenteric Lymphadenitis.

**INTRODUCTION:** Abdominal pain is a frequent symptom in pediatric patients presenting to the outpatient department and causality. Sonography of the abdomen was performed routinely to investigate the cause of pain. The detection of enlarged lymph nodes without any other abnormality is termed mesenteric lymphadenitis, meaning inflammatory process of abdominal lymph nodes. Radiologically the term mesenteric lymphadenitis is used to describe lymph nodes > 5 mm. This retrospective study was performed to evaluate the incidence of mesenteric lymphadenitis as a cause of abdominal pain. As per the study by Sivit CJ, Newman KD, Chandra RS mesenteric lymph nodes were detected in 14% of symptomatic children, but enlarged mesenteric lymph nodes in children with acute pain represents a non-specific finding. The purpose of this study was to explore the prevalence and specific location of the enlarged nodes, and their gender distribution, and associated findings like ascites.

**MATERIALS AND METHODS:** Our study group included 500 successive pediatric patients who were referred for abdominal sonography with abdominal pain. Two experienced radiologists performed all the examinations. Scanning was performed using GE Voluson 730 and Siemens SONOLINE G50Ultrasound machines. The transducers used were convex3.75 MHz and Linear 7.5MHz probes. Scanning of the right and left lower abdominal quadrants and para aortic region were performed with the linear probes routinely. Lymph nodes of size >5mm were documented for further study.

# ORIGINAL ARTICLE

Each lymph node was measured in two dimensions (AP and Transverse). Patient's age, reason for evaluation, presence of enlarged nodes, location size and number were recorded. The age range of the study was from 1 to 13 years. Presence of three or more lymph nodes was considered as a cluster of lymph nodes (Figure 3b). Additional findings such as free fluid and positive probe tenderness were also recorded.

The patients were divided into two groups - those who were primarily referred for abdominal pain, (Group A) and those who were referred for other clinical conditions (Group B).

Table 1: Showing distribution of enlarged nodes of >5mm between Group A and Group B

Group A	27.2%
Group B	25.0%

Table 2: Showing distribution of enlarged nodes of >10mm between Group A and Group B

Group A	72.8%
Group B	75.0%

A review of the dimensions of the lymph nodes detected shows that the transverse diameter (Figure 2a) was by and large always greater than the antero-posterior diameter (Figure 2b). The range for transverse diameter was seen between 10 mm to 13 mm (Figure 3a to 3d), whereas antero-posterior diameter was between 5 mm to 8 mm.

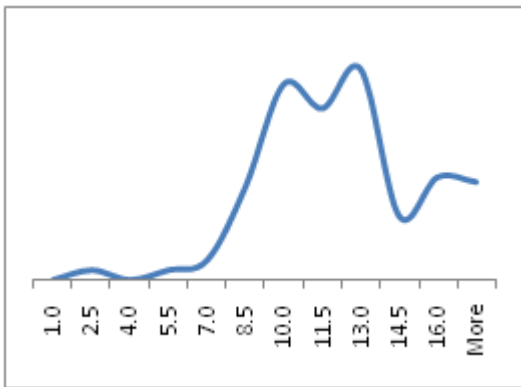


Fig. 2a

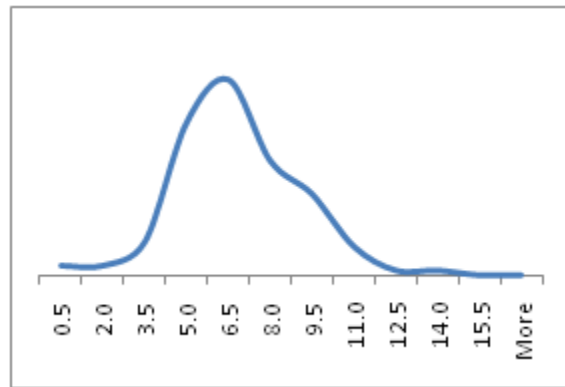


Fig. 2b

An observation was that 50% of the lymph nodes had transverse diameter about 2 times that of the antero-posterior diameter.

# ORIGINAL ARTICLE

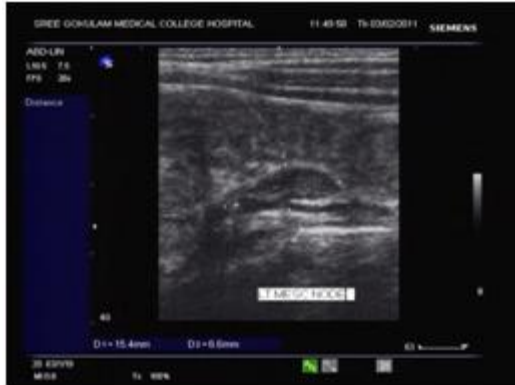


Fig. 3a: Transverse sonogram of the LLQ showing a node of size 15mm

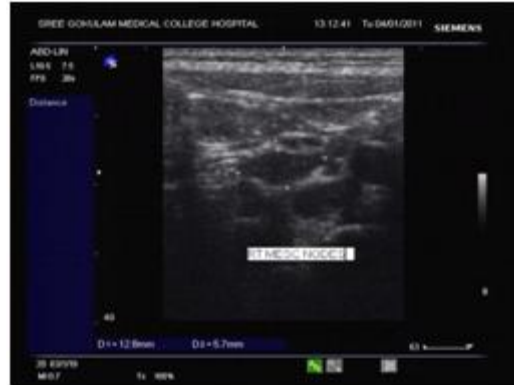

Fig. 3b: Transverse scan showing incidence of multiple lymph nodes in RLQ, the largest measuring 12mm

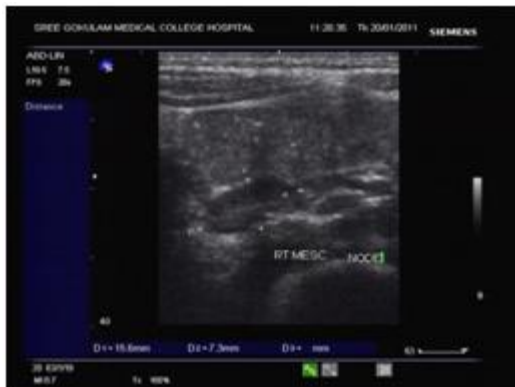


Fig. 3c: RLQ node measuring 15mm in transverse scan

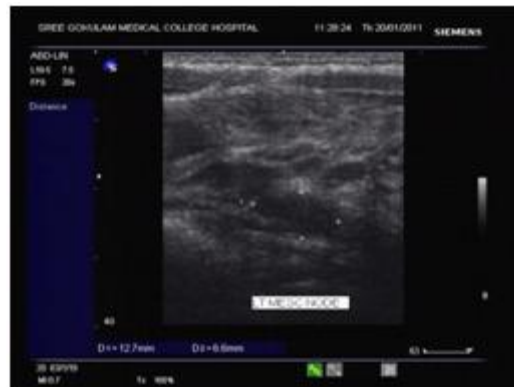

Fig. 3d: LLQ nodes, largest measuring 12.7mm in transverse scan

Probe tenderness was seen was 1.5 % of the patient sample.

Ascites or Interloop fluid was seen in 2.5% of patient sample.

The peak incidence was seen between 5.5 years to 7.5 years, and thereafter there was a decrease in incidents with increase in age especially after the age of 11 years. (Figure 4).

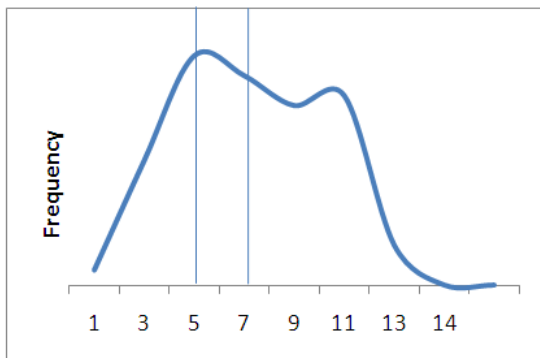


Figure 4

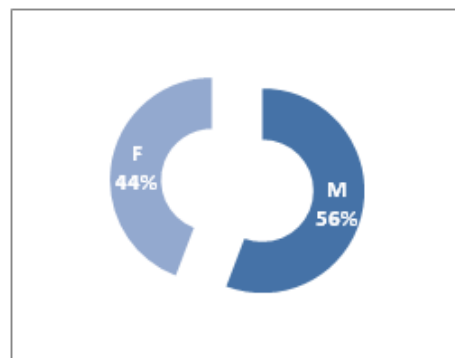


Figure 5

## ORIGINAL ARTICLE

There was parity in the distribution between sexes, with marginally more males in the distribution. (Figure 5).

**Location and Lymph nodes and Distribution:** Distribution of enlarged lymph nodes was also analyzed, with the location of the node (Left lower quadrant, Right lower quadrant and para-umbilical region).

The largest proportion of the nodes was seen in the right quadrant, followed by the para-umbilical region and the left lower quadrant. (Figure 6)

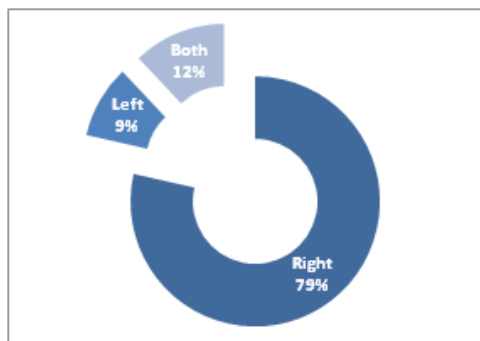


Figure 6

**DISCUSSION:** Our findings correlated with the study published by Vayner, Coret, et al in Pediatric Radiology December Edition regarding size, number, and location of mesenteric nodes. In their study, the location of the nodes was in the right lower quadrant with a greater prevalence in boys. In the study done by Rathaus V and Shapiro M, Et al, enlarged mesenteric lymph nodes were detected in 55 of 189 asymptomatic children. The longitudinal diameter of the nodes was noted to range between 5mm to 19mm.

Sonography is routinely used in pediatric patients to identify the cause of abdominal pain and to exclude other abdominal diseases. It is a fast, non-invasive, effective and economic way to diagnose the cause of abdominal pain. Mesenteric Lymphadenitis may clinically mimic acute appendicitis, intussusception, and other causes of acute abdominal pain. Mesenteric Lymphadenitis relies predominantly on the size of the lymph nodes, while some authors consider lymph nodes more than 4mm in their short axis significant. Others consider the size greater than 10mm in their long axis as significant. There is disagreement in the radiological literature about the frequency of occurrence in the mesenteric lymph nodes.

In asymptomatic children with wide variation in different studies:

Enlarged nodes of > 5mm were detected in 23% of the asymptomatic patients. Enlarged nodes of > 10 were seen in 72.8 % of the patients presented with abdominal pain. On the basis of this study – mesenteric lymphadenitis the term should be used for – specific inflammation of the lymph nodes in the appropriate clinical setting. Our study also showed that 79% of the lymph nodes were found in the right lower quadrant, followed by left lower quadrant (9%), and only 1% was seen in the peri-umbilical region.

In conclusion – enlarged lymph nodes of  $\geq 10$ mm in their long axis with the clinical background of abdominal pain may represent mesenteric lymphadenitis. Enlarged nodes are

# ORIGINAL ARTICLE

frequently seen in asymptomatic children, should not be automatically considered as abnormal. Sonography is helpful in the detection of enlarged lymph nodes and for the exclusion of other causes producing abdominal pain. The presence of enlarged mesenteric lymph node in asymptomatic children of all ages and both sexes is a common non-specific finding, and should be evaluated only in the appropriate clinical context.

## REFERENCES:

1. Sivit C.J, Newman KD, Chandra RS, Visualization of enlarged mesenteric lymph nodes at US examination. *Pediatr Radio* 1993; 23: 471 – 475 (Medline).
2. Koruda MJ, Bell LM, Ross AJ III. Atypical micro-bacterial mesenteric lymphadenitis in childhood as an abdominal mass. *J PediatrSug* 1988; 23:526-528.
3. Carty HML. Pediatric emergencies: non-traumatic abdominal emergencies. *Eur Radiology* 2002;12:2848. (Medline).
4. Healy MV Graham PM Assessment of abdominal lymph nodes in a normal pediatric population; an ultrasound study. *AustralasRadiol* 1993;37:171-172 (Medline).
5. Watanabe M Ishiii E, Hirowatari. Y, et al. Evaluation of abdominal lymphadenopathy in children by ultra sonography, *PediatrRadiol* 1997;27:860-864 (Medline).
6. Rao PM Rhea JT Novelline RA, CT diagnosis of mesenteric adenitis. *Radiology* 1997;202:145-149.
7. Grossman.M, Shriamizy B Evaluation of lymphadenopathy in children. *Curr Opin Pediatr* 1994; 6:68-76 (Medline).
8. Importance of sonographic details of large abdominal lymph node in children NahaliaSimanous.

## AUTHORS:

1. Vinod Jacob
2. A. S. Krishna Kumar

## PARTICULARS OF CONTRIBUTORS:

1. Associate Professor, Department of Radiodiagnosis, Sree Gokulam Medical College and Research Foundation.
2. Associate Professor, Department of Radiodiagnosis, Sree Gokulam Medical College and Research Foundation.

## NAME ADDRESS EMAIL ID OF THE CORRESPONDING AUTHOR:

Dr. Vinod Jacob,  
Associate Professor,  
Sree Gokulam Medical College and Research  
Foundation, Venjaromoodu P.O.,  
Thiruvananthapuram – 695 607.  
Email – drvinoojacob@hotmail.com

Date of Submission: 05/11/2013.

Date of Peer Review: 06/11/2013.

Date of Acceptance: 15/11/2013.

Date of Publishing: 21/11/2013