

# CASE REPORT

---

## REGIONAL NERVE BLOCK FOR FEMORO-POPLITEAL AND TIBIAL ARTERIAL RECONSTRUCTIONS

Aarti Balakrishnan<sup>1</sup>, Sahajanand H<sup>2</sup>

### HOW TO CITE THIS ARTICLE:

Aarti Balakrishnan, Sahajanand H. "Regional nerve block for femoro-popliteal and tibial arterial reconstructions". Journal of Evolution of Medical and Dental Sciences 2013; Vol. 2, Issue 47, November 25; Page: 9205-9209.

**ABSTRACT:** Presenting here, the effectiveness of combined lumbar plexus and sciatic nerve block in femoro-popliteal and femoro-tibial bypass surgeries. Patients were stable throughout the procedure and postoperatively with no complaints of pain.

**KEYWORDS:** Lumbar plexus block, Sciatic nerve block.

**INTRODUCTION:** This article briefs about 2 vascular surgeries, two high-risk patients underwent lower extremity revascularization anesthetized with a regional nerve block technique. Femoro-popliteal and femoro-tibial bypasses were performed for limb salvage and disabling claudication. Analgesia was adequate. Regional nerve block is an effective anesthetic technique that should be considered if general or spinal anesthesia is inappropriate.

**CASE 1:** A 62year old male had presented with complaints of severe pain of rt. Lower limb which aggravated on walking which was diagnosed to be because of occluded SFA. He was a known case of IHD who had undergone angiogram 6 years back for left inferior wall MI and was on T. ECOSPIRIN 150 BD, T. PROLOMET XL 25 OD and T. AZTOR 20 HS. He also gave a history of chronic smoking since last 45years (5 beedi/day). On examination rt dorsalis pedis was absent and rt popliteal pulsations feeble. Effort tolerance was good. Nothing abnormal was detected on respiratory system examination and cardiovascular system examination with Mallampatti grade 1, full range of head and neck movements and no loose teeth. ECG showed t wave inversion in lead iii, avR and avF; ECHO showed IHD, resting RWMA present, Trivial MR, Sclerotic aortic valve, EF -55%.

**CASE 2:** A 34yr old male had presented with complaints with a non healing ulcer in the web space between 4th and 5th toe and on the great toe of left leg which was diagnosed due to left SFA occlusion. He was a known case of IHD on T. ECOSPIRIN 150 BD, T. PROLOMET XL 25 OD and T. AZTOR 20 HS. He also gave a history of chronic smoking since last 20years (2packs /day) On examination left dorsalis pedis and posterior tibial absent. Effort tolerance was good. Nothing abnormal was detected on respiratory system examination and cardiovascular system examination with Mallampatti grade 1, full range of head and neck movements and no loose teeth. ECG- t wave inversion in lead iii, avR and avF. ECHO showed IHD, resting RWMA present; Trivial MR, Sclerotic aortic valve, EF – 53%. CHEST X RAY- increased broncho-vascular hilar markings

Premedicated the patients with Inj. Midazolam (1mg) and Inj. Fentanyl (50mcg). Lumbar plexus block and sciatic nerve block given after identifying the landmarks and using a nerve stimulator initially set at 3 and brought down to 0.5. Drug used was 30ml of 0.5% Bupivacaine with 20ml NS (25ml for lumbar plexus block and 25ml for sciatic nerve block). Vitals were maintained stable throughout the procedure and post operatively the patient was shifted to SICU where he was monitored for next 2 days. Inj. Paracetamol 1gm TID and Inj. Tramadol 150mg SOS was prescribed

# CASE REPORT

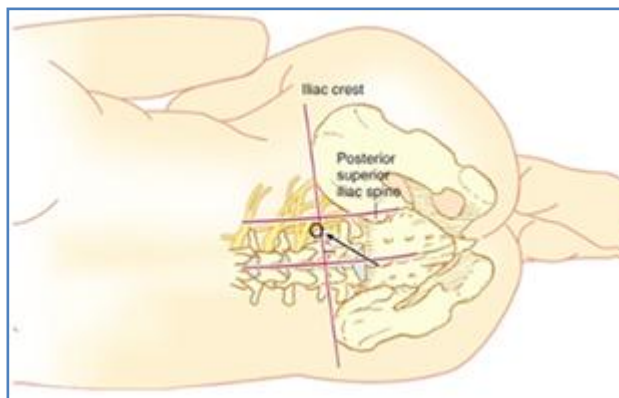
---

for post operative analgesia. The first analgesic dose given was after 8 hours and 6 hours after the block respectively. Patients neither had any sleep disturbances nor any other complaints. Graft pulsations were felt for both. Inj. Clexane s/c was given for next 3 days in OD dose and patients shifted from SICU on post op day 4.

## DISCUSSION:

**ANATOMY:** The Lumbar Plexus describes the association of nerves derived from the segmental lumbar spinal roots. The lumbar plexus receives input from L1 (variable input from T12) to L4 and produces the femoral nerve, lateral cutaneous nerve of the thigh, obturator nerve, as well as the iliohypogastric, ilioinguinal and genitofemoral nerves. <sup>1</sup>

**Lumbar Plexus Origins:** The lumbar plexus is formed from the ventral rami of L1-L3 (sometimes including T12), with a major contribution from L4. The nerve roots then run anteriorly to form the lumbar plexus, which lies between the quadratus lumborum and psoas major muscles. The plexus and branches then angle caudally to descend within the mass of the psoas major muscle, anterior to the transverse processes of the lumbar vertebrae. The L1 nerve root (occasionally with a contribution from T12), splits into an upper and a lower branch. The upper branch then divides into the iliohypogastric and ilioinguinal nerves. The lower branch forms the genito femoral nerve with a contribution from L2 nerve root. The ventral branches of L2, L3 and L4 form the obturator nerve. The dorsal roots of L2 and L3 have lesser branches, which make up the lateral cutaneous nerve of the thigh, and greater branches, that along with the dorsal root of L4 are the origins of the femoral nerve. <sup>5</sup>



## LUMBAR PLEXUS BLOCK

As with all regional anaesthesia procedures: consent must be obtained from the patients, iv access established and standard monitoring attached, resuscitation facilities must be available and the procedure carried out in an aseptic manner. <sup>2</sup>

Lumbar plexus blocks, like all regional anaesthetic techniques, should ideally be performed on awake or lightly sedated patients, however many practitioners will safely undertake the block following general or spinal anaesthesia. At least some sedation is recommended for posterior approaches to the lumbar plexus because it is a deep block, with the needle having to pass through a

# CASE REPORT

---

reasonable amount of muscle mass. A small, sub-cutaneous and intradermal injection of lidocaine (or similar) at the point of needle insertion is recommended for patient comfort. <sup>3</sup>

## **Absolute contraindications<sup>3</sup>**

Patient refusal

Local anaesthetic allergy

Local sepsis or infection at puncture site (or within psoas muscle)

INR > 1.5 or < 12 hours post LMWH (many practitioners consider a posterior approach to lumbar plexus comparable to central neuroaxial blockade.)

## **Relative contraindication and cautions<sup>3</sup>**

Systemic sepsis, especially for catheter placement.

Poor cardiac function or fixed cardiac output – The risk of epidural and subarachnoid spread from the posterior approaches means that caution should be exercised in considering this block in patients with poor cardiac function or fixed cardiac output. However, lumbar plexus block may be the best option for analgesia in major lower limb surgery in such patients. <sup>3</sup>

Dose and volume of Local Anaesthetic - This is a “tissue plane” block and thus requires a large volume of local anaesthetic to obtain a reliable block of the plexus. Volumes of 30 to 40 mls are recommended. The dose of local anaesthetic needs to be considered in the context of the size of the patient and any other local anaesthetic administered (e. g. a sciatic nerve block) to ensure maximum safe dose is not exceeded. The psoas muscle is a relatively vascular area and systemic absorption of local anaesthetic can be significant. <sup>4</sup>

Total dose of local anaesthetic should not exceed maximum recommended doses (i. e. 150mg or 2mg/kg of Bupivacaine/ levobupivacaine /marcaine or 300mg of Ropivacaine). Due to the vascularity of the psoas muscle it would be wise to stay well under the maximum dose. A suitable example would be 30mls 0.25% Bupivacaine for <75kg patient and 40mls 0.25% Bupivacaine for >75kg patient.<sup>4</sup>

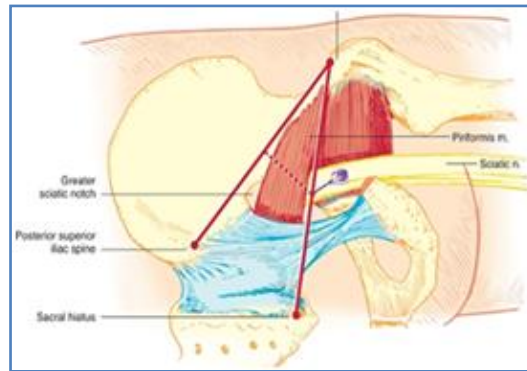
**Patient Position:** There are several posterior landmark based approaches to the lumbar plexus all of which require the patient to be in the lateral position with the operative side uppermost, the hips and knees are flexed to 90 degrees<sup>5</sup>

An intercrystal line is drawn at L4/L5, and another parallel with the spine through the Posterior Superior Iliac Spine (PSIS). The needle is inserted at the intersection of these lines with a slight medial inclination. The needle should be between the transverse processes of L4 and L5. The needle can be redirected caudally if the transverse process of L5 is encountered. Winnie used paresthesia as his end point but as described later in this article today the accepted end point for the lumbar plexus is stimulation of the femoral nerve component, observed by contraction of the quadriceps muscle<sup>5</sup>.

The sciatic nerve supplies motor and sensory innervation to the posterior aspect of the thigh as well as the entire lower leg, except for the medial leg, which is supplied by the saphenous nerve (the terminal branch of the femoral nerve). The sciatic nerve, formed from the anterior rami of

# CASE REPORT

spinal nerves L4–S3, is the largest nerve in the body. Because the sciatic nerve is so large, it can be blocked from several different locations along the lower extremity. <sup>7</sup>Labat's sciatic nerve block is the classic approach, targeting the nerve in the gluteal region. Other sciatic nerve blocks include the anterior and lateral approaches, which allow the patient to remain in the supine position, as well as the parasacral and prone approaches. Raj's subgluteal approach is performed in the supine position with the hip flexed.<sup>4</sup>



## SCIATIC NERVE BLOCK

In Labat's classic approach, the patient is placed in lateral decubitus position (operative side up), and the leg is flexed at the knee. If the patient is unable to flex the leg, the leg should be extended at the hip as far as possible without producing patient discomfort. Draw a line between the greater trochanter to the posterior superior iliac spine (PSIS). Draw a second line from the greater trochanter to the patient's sacral hiatus (Winnie's modification). Determine the point of initial needle insertion by drawing a line perpendicular from the midpoint of the first line to its intersection with the second line. A fourth line can be drawn along the "furrow" formed by the medial edge of the gluteus maximus muscle and the long head of the biceps femoris muscle. The furrow represents the course of the sciatic nerve toward the lower leg. The triangle formed by the first, second, and fourth lines further defines initial needle placement, and subsequent adjustments of the needle within the triangle can improve success at sciatic nerve stimulation.<sup>4</sup>

The posterior approach to the sciatic nerve combined with a lumbar plexus block provides complete anesthesia of the lower extremity (a femoral nerve block often misses the obturator nerve). Labat's approach is well suited for continuous catheter techniques. Studies of this posterior approach have demonstrated that plantar flexion of the foot (tibial nerve stimulation) resulted in a shorter onset time and more frequent success of the block versus dorsiflexion (common peroneal nerve). The addition of the furrow line can be especially useful in obese patients, when palpation of traditional landmarks is difficult.<sup>4</sup>

**CONCLUSION:** Regional nerve block is a safe, effective option for lower extremity revascularization with no major systemic effects or complications resulting from its use<sup>6</sup>. The analgesia provided is adequate, although the amount of analgesia is probably more suitable for the relatively easy femoropopliteal bypass that can be completed within a 3-hour period. With this technique a sympathetic block does occur but only in the extremity anesthetized. Since regional nerve block

# CASE REPORT

---

usually avoids cardiovascular changes, systemic monitoring of central venous pressures or arterial wedge pressure can be avoided.

## REFERENCES:

1. Capdevila X, Macaire P, Dadure C, Choquet O, Biboulet P, Ryckwaert Y et al. Continuous Psoas Compartment Block for Postoperative Analgesia After Total Hip Arthroplasty: New Landmarks, Technical Guidelines, and Clinical Evaluation. ANESTH ANALG 2002; 94; 1606–13.
2. S. T. Touray, M. A. de Leeuw, W. W. A. Zuurmond and R. S. G. M. Perez. Psoas compartment block for lower extremity surgery: a meta-analysis. British Journal of Anaesthesia; 2008; 101 (6): 750–60.
3. Auroy Y, Benhamou D, Bargues L, Ecoffey C, Bruno Falissard B, Mercier F, Bouaziz H, Samii K. Major Complications of Regional Anesthesia in France. Anesthesiology 2002; 97:1274–80.
4. The Abbott pocket guide to practical peripheral nerve blockade. Nicholls, Conn, Roberts.
5. Patton K, Warman P. LUMBAR PLEXUS BLOCK – LANDMARK TECHNIQUE (PSOAS COMPARTMENT BLOCK) ANAESTHESIA TUTORIAL OF THE WEEK 263 18TH JUNE 2012.
6. Ronald D Miller. Miller's Anesthesia. 7th edition. Volume II. Pg: 1639-1679.
7. Vincent J Collins. Principles of Anaesthesiology; General And Regional Anaesthesia. 3rd edition. Volume II. Pg: 1395-1413.

## AUTHORS:

1. Aarti Balakrishnan
2. Sahajanand H.

## PARTICULARS OF CONTRIBUTORS:

1. Post Graduate, Department of Anaesthesia, Rajarajeswari Medical College and Hospital.
2. Professor and HOD, Department of Anaesthesia, Rajarajeswari Medical College and Hospital.

## NAME ADDRESS EMAIL ID OF THE CORRESPONDING AUTHOR:

Dr. Aarti Balakrishnan,  
Department of Anaesthesia,  
Rajarajeswari Medical College and Hospital,  
Kambipura, Mysore Road, Bangalore.  
Email – aarti0129@yahoo.com

Date of Submission: 09/10/2013.

Date of Peer Review: 11/10/2013.

Date of Acceptance: 19/11/2013.

Date of Publishing: 22/11/2013