

**COMPARATIVE STUDY OF SUBMENTAL INTUBATION CUFF IN VS CUFF OUT: A CASE SERIES**

Aprajita Pandey<sup>1</sup>, Shashikant Mhashal<sup>2</sup>, Rajesh R. Yadav<sup>3</sup>, Shruti Bansal<sup>4</sup>, Parag Kerkar<sup>5</sup>, Rashu Mittal<sup>6</sup>

<sup>1</sup>Medical Officer, Department of ENT, GM Hospital, Rewa.

<sup>2</sup>Associate Professor, Department of ENT, Cooper Hospital, Mumbai.

<sup>3</sup>Associate Professor, Department of ENT, Bhagwati Hospital, Mumbai.

<sup>4</sup>Specialist Medical Officer, Department of ENT, KEM, Mumbai.

<sup>5</sup>Honorary, Department of Dentistry, Bhagwati Hospital, Mumbai.

<sup>6</sup>Resident, Department of ENT, Bhagwati Hospital, Mumbai.

---

**ABSTRACT**

In patients with panfacial trauma where short-term intraoperative control of airway is required, submental intubation is an alternative to tracheostomy as it is associated with lesser morbidity. It is also an interesting alternative to oral and nasal intubation as intraoperatively the tube does not cause any hindrance to the surgeon and occlusion can also be assessed simultaneously. Out of 10 cases of maxillofacial trauma operated in our hospital using submental intubation, the cuff of the pilot tube was brought out in 5 of them through the midline incision, while in remaining 5 it was left inside the nasopharynx. It was observed subsequently that cuff inside the nasopharynx had some advantage, viz. there were lesser chances of accidental extubation, rupture of cuff and the incision size need not be extended to extract the cuff which resulted into a cosmetically better scar.

**KEYWORDS**

Panfacial Trauma, Submental Intubation, Tracheostomy, Maxillofacial Trauma.

---

**HOW TO CITE THIS ARTICLE:** Pandey A, Mhashal S, Yadav RR, et al. Comparative study of submental intubation cuff in vs cuff out: a case series. J. Evolution Med. Dent. Sci. 2016;5(50):3277-3280, DOI: 10.14260/jemds/2016/736

---

**INTRODUCTION**

Submental intubation in patients with panfacial trauma is an interesting alternative, as it offers a secure airway to the anaesthetist, an optimal operating field to the surgeon with the opportunity to check the occlusion simultaneously and causes lesser morbidity to the patients when compared to tracheostomy. It was first described by Altemir in 1986.<sup>1</sup> and it has undergone various modifications since then. Panfacial trauma involves the cranium, mid face and mandible.<sup>2</sup> Early reduction of these fractures with rigid internal fixation is the standard protocol. The maintenance of airway without interfering with the operative field is important as the surgeon and anaesthesiologist are essentially competing for the same space. Maxillomandibular fixation is often required intraoperatively for adequate reconstruction of facial fractures.<sup>3,4</sup> Oral intubation interferes in Maxillomandibular fixation and in patients where nasoendotracheal intubation is contraindicated. A cricothyrotomy or tracheostomy has been the traditional method of airway control.<sup>5</sup> In these cases, submental intubation has a major role to play, as it consists of the tube passing through the anterior floor of mouth, allowing free intraoperative access to oral cavity and nasal pyramid. It can thus be used as an alternative to tracheostomy in short term post-operative airway management. The purpose of this study was to compare a modified technique of submental intubation where the cuff remained inside the nasopharynx with the standard one where the cuff is brought outside and assess the outcome.

**MATERIALS AND METHODS**

This prospective clinical study was conducted between Jan. 2014 and Jan. 2015 on 10 patients with mean age being 26.9 who presented with panfacial trauma and in whom oral and nasal intubation was not possible were selected for study. Patients with neurological deficits, thoracic trauma and in patients for whom repeated operations were anticipated were excluded from the study. The technique used for submental intubation was an adaptation of the general principles published by Hernandez Altemir (1986). Standard orotracheal intubation was done. Following the sterile painting and draping of chin and mouth, 2% lignocaine with 1:80,000 adrenaline was infiltrated at the incision site (Fig. 1). A midline incision of 1.5 cm was made anterior to inferior border of mandible at the chin level. A curved haemostat was passed from the submental incision through the subcutaneous layer, platysma, mylohyoid, submucosa and mucosa. After entering the oral cavity at the junction of attached lingual alveolar mucosa and free mucosa of the floor, an incision of 1.5 cm in length was made parallel to gingival margin (Fig. 2). The haemostat was opened to create a soft tissue passage for endotracheal tube. With the curved haemostat deflated, pilot tube cuff was passed extraorally. Then the endotracheal tube was disconnected from the breathing circuit and the standard connector removed from the ET tube. Disconnection of the standard connector from the ET tube facilitated easy passage of the ET tube through the submental incision. The tube was then manually stabilized and the tip of ET tube gently pulled out through the submental incision with the help of a curved haemostat. After confirmation of its adequate tracheal position by capnography and bilateral auscultation of the lungs, the tube was reconnected to the breathing circuit and secured to skin of the submental area with 3-0 silk sutures. Intraorally, the tube was positioned between the tongue and mandible just above the mucosa of the floor of the mouth (Fig. 3). The tube should be freely movable to allow for intraoral manipulation. Out of 10 patients in 5 patients the cuff was left inside the oral

---

Financial or Other, Competing Interest: None.

Submission 30-04-2016, Peer Review 30-05-2016,

Acceptance 06-06-2016, Published 21-06-2016.

Corresponding Author:

Dr. Aprajita Pandey,

F-12, Doctor's Colony,

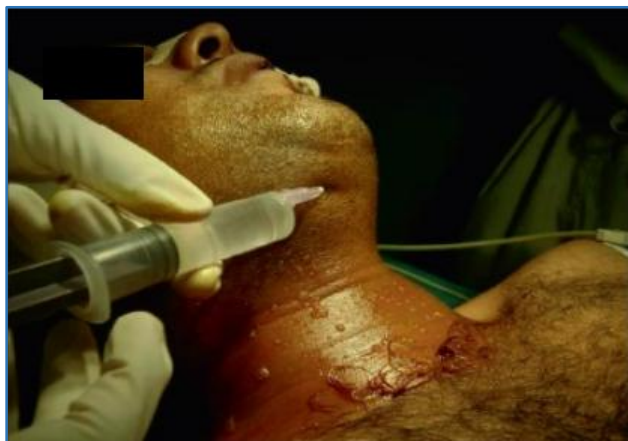Rewa.

E-mail: drsonal0123@gmail.com

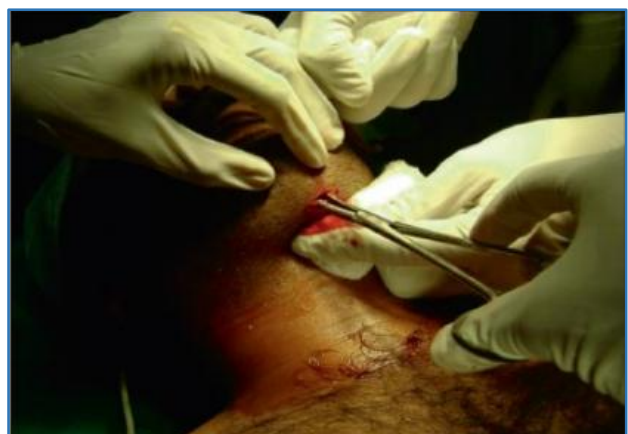DOI: 10.14260/jemds/2016/736

---

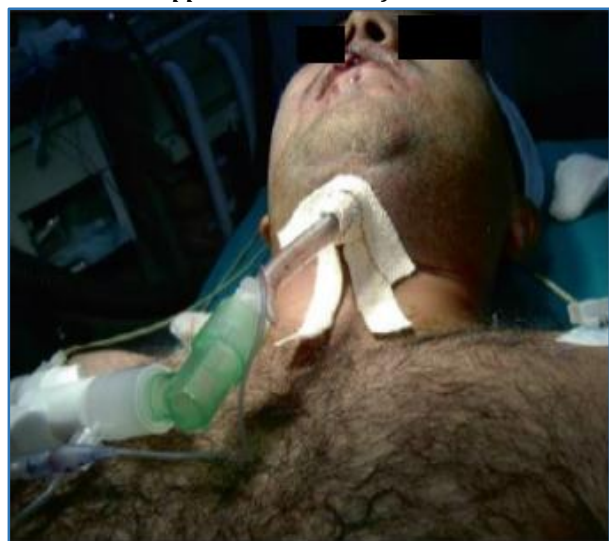cavity and in other 5 the cuff was brought out from the midline incision. At the end of the surgery submental intubation was converted to oral intubation. The ET tube was pulled back intraorally in the reverse order, i.e. first the reinforced tube and then the pilot tube cuff. The submental skin incision was closed with interrupted silk sutures and intraoral incision left to heal by secondary intention. The patients were followed up on regular basis and assessment was based on postop morbidity in terms of function and aesthetics.



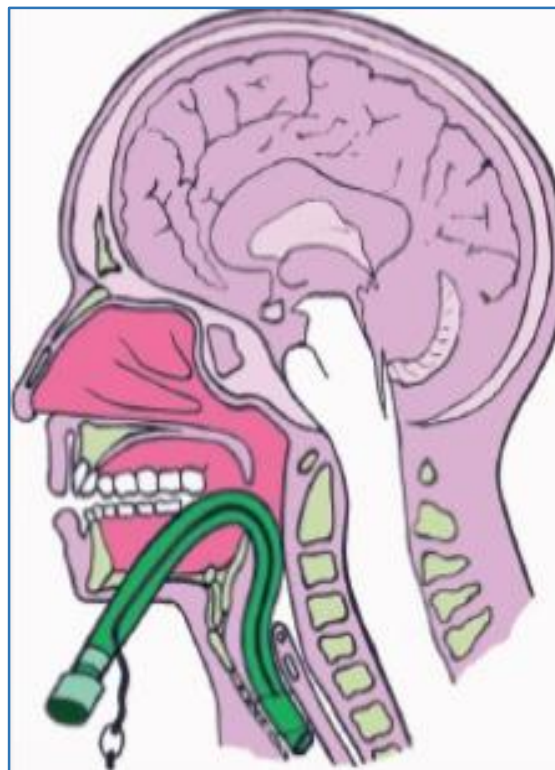
**Fig. 1: Anaesthetizing the Local Area**



**Fig. 2: Incision Placed and Tunnelling Done on the Medial Side of Mandible to Approach the Floor of Mouth**



**Fig. 3: Submental Exit and Stabilization of Endotracheal Tube with Adhesive Tape and Sutures**



**Fig. 4: Schematic View of the Tube Position**

## RESULTS

The technique of submental intubation was used in 10 patients from Jan. 2014 to Jan. 2015. Out of the 10 patients in 5 of them the cuff was brought outside, while in other 5 it remained inside. The intubation method itself did not lead to any intraoperative complication. In all patients, submental intubation allowed simultaneous treatment of all fractures without changing the method of intubation and without getting into the field of the surgeon and causing any hindrance during surgery. The average time taken in the procedure with the cuff outside was 7 min, while the time taken with the cuff inside was 3.2 min. Disconnection of the standard connector from the tube was done easily. During this manoeuvre, there was no incidence of complication such as accidental extubation or loosening of connector after reattachment. Time period for disconnection from the ventilator ranged from 1-2 min, meanwhile there was no significant oxygen desaturation. None of them required postop ventilatory support. Patients were evaluated periodically. Normal healing of the mucosa of floor of the mouth was observed. The postop scar in patients was well accepted and in patients in whom the cuff was kept inside the size of the scar was comparatively smaller.

Sl. No.	Age	Sex	Maxillofacial #	Complication (Intraoperative)	Complication (Post-operative)	Duration of Procedure (Minute)	Cuff	Duration of Postop Ventilation
1	20	M	LeFort II, NOE, Mandible	None	None	3	In	Nil
2	35	M	LeFort II, NOE, Mandible, Alveolar	None	None	3	In	Nil
3	25	M	LeFort III, NOE, Mandible	None	None	3.5	In	Nil
4	29	M	LeFort III, NOE, M Mandible	None	None	3	In	Nil
5	32	F	LeFort II, NOE, Mandible	None	None	3.5	In	Nil
6	24	M	LeFort III, NOE, Mandible	None	None	6.5	Out	Nil
7	21	M	LeFort III, NOE, Mandible	None	None	8	Out	Nil
8	22	M	LeFort II, NOE, Mandible	None	None	7	Out	Nil
9	29	M	LeFort III, NOE, Mandible	None	None	7	Out	Nil
10	32	M	LeFort II, NOE, Mandible Alveolar	None	None	6.5	Out	Nil
<b>Demographic and Clinical Data of Patients</b>								

NOE – Nasoorbitoethmoidal

## DISCUSSION

Ever since the concept of submental intubation was first introduced, it has undergone various modifications and found new indications.<sup>6</sup> It can be safely used in patients with mid-facial or panfacial fractures with base of skull fractures as well as in patients undergoing elective Le Fort osteotomies or simultaneous elective mandibular orthognathic surgery and rhinoplasty procedure.<sup>7,8</sup> In the present study, submental intubation was possible in all the patients without any major complication and facilitated unimpeded manipulation of fractured fragments, achievement of occlusion, establishment of maxillomandibular fixation, assessment of facial symmetry and at the same time allowing easy access to endotracheal tube for the anaesthetist. Oromaxillofacial procedures often present problems both to the surgeon and anaesthetist. Oral intubation per se interferes with checking the dental occlusion, while nasotracheal intubation is usually contraindicated in the presence of nasal bone fractures present in isolation or as a component of LeFort fractures.<sup>8,9</sup> Conventional tracheostomy which is an alternative in these situations has many short-term and long-term complications like haemorrhage, subcutaneous emphysema, pneumomediastinum, recurrent laryngeal nerve palsy, tracheal stenosis, tracheomalacia, etc.<sup>10-12</sup> The significant morbidity post-tracheostomy restricts its usage indiscriminately. Other methods have also been tried to achieve short-term airway management, viz. retromolar intubation and nasal tube switch technique. Retromolar intubation has disadvantages like being more traumatic, obtrusive, costly and requiring more operating time.<sup>13</sup> Nasal tube switch technique was not performed due to problems associated with the intraoperative re-intubation like risk of aspiration due to posterior nasal bleed, potential airway compromise with need for emergency tracheostomy.<sup>14</sup>

The technique of lateral incision through the body of mandible has also been advocated by some, but midline approach described by MacInnis is a safer approach as only a few anatomical structures are present and there is minimal risk of neurovascular damage and the midline incision heals better and is cosmetically superior.<sup>15</sup>

The present study reports good results with the submental endotracheal intubation with the cuff inside. This is the first comparative study in submental intubation with cuff outside

vs cuff inside. Submental intubation is always a second step after the airway has been secured. During this procedure, the endotracheal tube must be firmly secured intraorally to prevent accidental extubation. The cuff inside technique offers some clear advantage over cuff outside technique like lesser time, cosmetically better scar. The complications of submental intubation include displacement of the tube leading to accidental extubation.<sup>16</sup> This can be prevented by fixing the tube with sutures. Amin et al<sup>16</sup> have described the use of capnography during the process of conversion of orotracheal to submental intubation and throughout the surgery to confirm the position of the tube and to serve as a warning tool against accidental extubation.<sup>17</sup> Infection, orocutaneous fistula and post-operative submental scarring have been rarely associated with this technique.<sup>9</sup> Post-operative submental scarring is usually hidden from direct view in the submental region and is usually well accepted. The risk of injury to the lingual nerve, submandibular duct or sublingual gland is more seen with the lateral approach.

## CONCLUSION

Submental intubation technique can be used as an alternative to oral or nasal intubation during oromaxillofacial surgeries. This technique gives a clear field to the surgeon with the advantage of checking for occlusion simultaneously without causing significant morbidity to the patient. It also provides a secure airway to the anaesthetist. This is the first time where a study has been carried out comparing the submental intubation technique with the cuff placed outside with the modified technique where the cuff is placed inside the nasopharynx. We conclude that the modified technique with the cuff in is superior, as it takes comparatively lesser time and gives a comparatively better scar with no major disadvantage. The cuff can be monitored using a capnogram for any rupture or displacement. Overall, submental intubation is an answer to the problems faced by the surgeon and anaesthetist during oromaxillofacial surgeries and the technique used, i.e. cuff in or cuff out is the preference of the surgeon.

## REFERENCES

1. Altamir FH. The submental route for endotracheal intubation A new technique. J Maxillofac Surg 1986;14(1):64-5.

2. Adamo AK, Katsnelson T, Rodriguez ED, et al. Intraoperative airway management with panfacial fractures: alternative approaches. *J Craniomaxillofac Surg* 1996;2(3):30-5.
3. Markowitz BL, Manson PN. Panfacial fractures: organisation of treatment. *Clin Plast Surg* 1989;16(1):105-14.
4. Shumrick KA, Kersten RC, Kulwin DR, et al. Extended access internal approaches for the management of facial trauma. *Arch Otolaryngol Head Neck Surg* 1992;118(10):1105-12.
5. Phero JC, Weaver JM, Peskin RM. Anaesthesia for maxillofacial/mandibular trauma. In: Benumof JL, editor. *Anaesthesiology clinics of North America. Anaesthesia of otolaryngologic and head and neck surgery*. Philadelphia: Saunders 1993:509-23.
6. Green JD, Moore UJ. A modification of submental intubation. *Br j Anaesthesia* 1996;77:789-91.
7. Biglioli F, Mortini P, Goisis M, et al. Submental orotracheal intubation: an alternative to short term tracheostomy in transfacial cranial base surgery. *Skull Base* 2003;13(4):189-95.
8. Chandu A, Smith AC, Gebert R. Submental intubation: an alternative to short term tracheostomy. *Anaes Intensive Care* 2000;28:193-5.
9. Joo DT, Orser BA. External compression of a nasotracheal tube due to the displaced bony fragments of multiple lefort fractures. *Anaesthesiology* 2000;92(6):1830-2.
10. Stauffer JL, Olson DE, Petty TL. Complications and consequences of endotracheal intubation and tracheostomy a prospective study of 150 critically ill adult patients. *Am J Med* 1981;70(1):65-76.
11. Callahan V, Connor OAFF. Adult and paediatric tracheostomy technique, complications and alternatives. *Curr Pract Surg* 1994;6:219-22.
12. Johnson TR. Submental versus tracheostomy. *Br J Anaesth* 2002;89(2):344-5.
13. Martinez-Lage JL, Eslava JM, Cebrecos AI, et al. Retromolar intubation. *J oral maxillofac Surg* 1998;56:302-6.
14. Werter JR, Richardson G, Mcilwain MR. Nasal tube switch: converting from nasal to an oral endotracheal tube without extubation. *J Oral Maxillofac Surg* 1994;52(9):994-6.
15. Innis ME, Baig M. A modified submental approach for oral endotracheal intubation. *Int J Oral Maxillofac Surg* 1999;28(5):344-6.
16. Amin M, Dill-Russel P, Manisali M, et al. Facial fractures and submental intubation. *Anaesthesia* 2002;57(12):1195-9.