

## USEFULNESS OF ULTRASOUND IN ACUTE SCROTUM

Naushad Ali N. Malagi<sup>1</sup>, Rathinasamy<sup>2</sup>, Nedunchelian<sup>3</sup>, T.R.K Madhavan<sup>4</sup>

### HOW TO CITE THIS ARTICLE:

Naushad Ali N. Malagi, Rathinasamy, Nedunchelian, T.R.K Madhavan. "Usefulness of Ultrasound in Acute Scrotum". Journal of Evolution of Medical and Dental Sciences 2014; Vol 3, Issue 01, January 06; Page: 235-240.

**ABSTRACT: OBJECTIVE:** To find out real incidence of TT in pediatric age group as against EO. **BACKGROUND:** Acute painful scrotum is one of the most challenging urological emergencies. The early and accurate diagnosis of testicular torsion remains a clinical challenge and it accounts for approximately 25% to 35% of patients presenting with acute scrotum<sup>1</sup>. To date, no single reliable clinical feature or examination can give 100% diagnostic accuracy<sup>2</sup>. Though these problems are rare in pediatric age group, they pose a serious risk of loss of vital functions of testis. Torsion (TT) is not uncommon – a fact unknown to most pediatricians & general practitioners. Testicular torsion has a lifetime incidence of approximately 1/4000 males younger than 25 years<sup>3</sup>. This disease affects a wide age range, and most commonly occurs between the ages of 12 and 18 years, after which the incidence slowly decreases<sup>4</sup>. Early diagnosis leads to preservation & its endocrine function & fertility. Hence as it is very difficult to differentiate TT & Epididymo-orchitis (EO) clinically, all cases should be submitted for surgical exploration at the earliest. **METHODS:** A Total of 250 patients were observed. All cases in the concerned age group presenting with acute pain, swelling in the scrotum, fever, vomiting were examined. Those having inflammatory signs in scrotum or any other signs suggesting TT or EO were admitted & evaluated. **CONCLUSION:** As the loss of gonadal function occurs so rapidly in TT, surgical exploration should neither be delayed for sonography nor be denied because of negative imaging in all acute scrotal swelling cases.

**INTRODUCTION:** Torsion of testis and epididymo-orchitis, are the leading causes of acute scrotum in children. Testicular torsion was first described by Delasiauve in 1840. It was not widely regarded as a significant problem until 1907, when Rigby and Russell published their work on torsion of the testis in Lancet. The first description of neonatal torsion was by Taylor in 1897. Subsequently, Colt reported torsion of the appendage testis in 1922.

Testicular torsion can occur at any age, including the prenatal and perinatal periods, In neonates, the testicle frequently has not yet descended into the scrotum, or has not had its gubernacular attachment secure to the scrotal wall. This increased mobility of the testicle predisposes it to torsion and makes up a small percentage of the total number of cases of testicular torsion. About 65% of cases present between 12 and 18 years, the early and accurate diagnosis of testicular torsion remains a clinical challenge and it accounts for approximately 25% to 35% of patients presenting of acute scrotum<sup>1</sup> origin of scrotal pain could be inflammatory disease, hydrocele, inguinal hernia, testicular tumor and underlying causes such as -Henoch Schoenlein purpura. Testicular torsion has a lifetime incidence of approximately 1/4000 males younger than 25 years<sup>2</sup>. This disease affects a wide age range, and most commonly occurs between the ages of 12 and 18 years, after which the incidence slowly decreases<sup>3</sup>. The testes grow by a factor of five during puberty. This rapid growth, especially with respect to the stretched gubernacular attachments, which increases the propensity to fall forward and rotate, may explain this phenomenon. Testicular

torsion usually occurs in the absence of a precipitating event; only 4% to 8% of cases result from trauma <sup>4</sup>. Intravaginal testicular torsion is typically associated with pain of sudden or insidious onset, nausea, and vomiting and is frequently followed by swelling of the ipsilateral scrotum <sup>5</sup>. In addition to careful clinical evaluation, including history, symptoms and signs of acute scrotal pain, and measurements of laboratory data, ultrasonography, Doppler sonography has been increasingly used in the evaluation of patients with suspicion of testicular torsion since it can be performed rapidly and in many studies the sensitivity and specificity were equal to those of a nuclear testicular scan.

In several reports, researchers have described false-negative color Doppler sonography findings in patients with testicular torsion despite its high reported sensitivities <sup>6-9</sup>. In addition, seeing flow in the normal prepubertal testis may be difficult or impossible, making the diagnosis of torsion on the contralateral symptomatic side more difficult<sup>10-14</sup>. In fact, some authors have suggested that radionuclide scintigraphy remain the imaging technique of choice in prepubertal children <sup>12</sup>. Universally accepted criteria for ultrasound diagnosis of epididymitis have not been established. There is some thought that torsion of the appendix testis may be misdiagnosed as epididymitis on ultrasound because inflammation surrounding the ischemic appendage may mimic the focal hyperaemia seen with true epididymitis.

**MATERIALS AND METHODS:** It is a Descriptive study conducted in Institute of Child Health & Hospital for Children, Madras Medical College, Chennai from 2008 to 2013.

All children – Aged– One month to twelve years and all cases of acute scrotal swelling were considered for this study.

Patient aged less than one month, admitted & unoperated, definite injury with scrotal swelling were excluded.

All cases in the concerned age group presenting with acute pain, swelling in the scrotum, fever, vomiting were examined. Those having inflammatory signs in scrotum or any other signs suggesting TT or EO were admitted. Urine analysis & ultrasonography done for all. A classic physical examination finding has not been found to be reliable in distinguishing torsion from other causes of testicular pain. The most reliable examination findings are absence of the cremasteric reflex and the affected testis palpated in a horizontal lie <sup>15</sup>. And Laboratory results did not provide much aid in the diagnosis of testicular torsion. A urinalysis was typically normal, but up to half of patients had an elevated white blood cell count. Diagnosis was not certain. And further the cause of acute scrotal pain was clinically uncertain, surgical exploration was performed after complete informed consent.

The peroperative visualization was taken as confirmation of the diagnosis and all patients were managed surgically.

Statistical analysis – Proportions of various outcomes were arrived at.

**RESULTS:** In the concerned study period, 250 patients were admitted with acute scrotal swelling, of these 40 absconded & 180 were operated & 154 were subjected to ultrasonography.

Out of 210 cases followed, 33.3% were clustered around infancy, with a downward trend as the age advanced. A slow rise during adolescence 17.14% was observed.

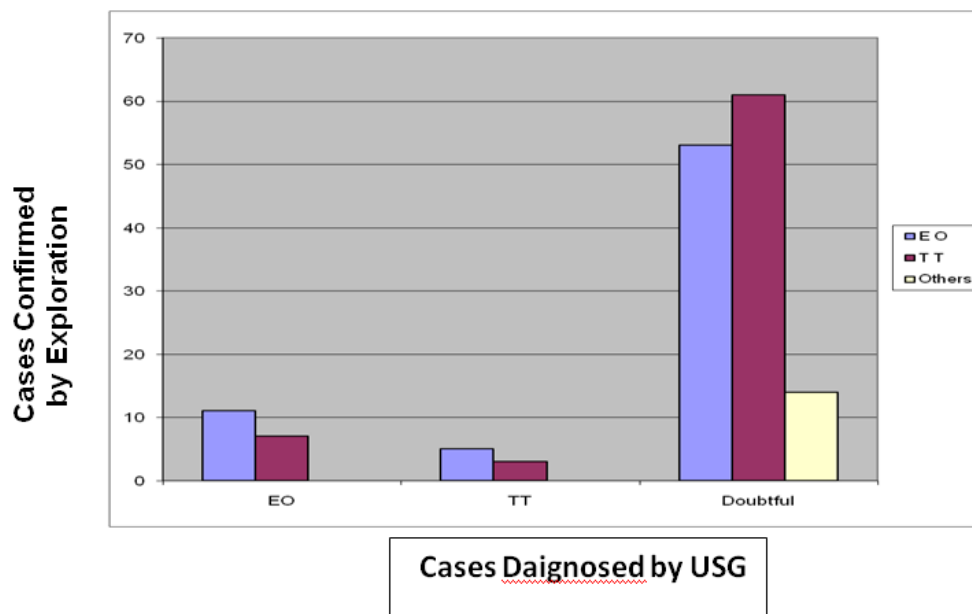
Most of the patients 60.47% presented after 6 hrs of the onset of symptoms with a few 13.3% presenting within 24 hrs.

# ORIGINAL ARTICLE

There was not much variation in the side of scrotum affected (L: R -- 1.03: 1)

Surprisingly ultrasonography could not add much to the diagnosis. In most of the cases 60.95% sonography was NOT contributory. When the diagnosis was made firmly (18 as EO and 08 as TT) it proved wrong in about 38% of cases.

When pediatric surgeon clinically diagnosed 101 as TT 68.3% (around 2/3<sup>rd</sup>) came out as TT & when he was in dilemma 91, preoperative visualization proved 35.16% (1/3<sup>rd</sup>) of these to be TT. Lastly even when he clinically diagnosed 18 as EO, 38.8% among these turned out to be TT.



Hence 180 out of 210 who were highly suspected of having testicular torsion after the history, laboratory and ultrasound examination underwent surgical exploration. When testicular torsion was confirmed by surgery (51.42%) turned out to be TT, 4 of the 14 other patients who underwent exploration had torsion of the testicular appendix, 5 had epididymo-orchitis, 3 had a scrotal hematoma, 1 had hydrocele, and 1 had testicular lymphoma

**DISCUSSION:** The diagnosis and treatment of patients presenting with acute scrotum continues to be one of the most challenging issues in pediatric urology.<sup>16</sup> The present data suggest that obligatory emergency scrotal exploration is not necessary in more than 75% of cases presenting with acute scrotum.<sup>1</sup> The need for urgent exploration of the twisted testis relates to the possible viability of the testes and for two further reasons. First, the anatomical abnormality responsible for the torsion (bare area in the classification of intravaginal type torsion) is often bilateral and therefore, the contralateral testis is usually routinely fixed at exploration. Second, several studies have disclosed that if a twisted testis is not removed, a reduced sperm count is not uncommon.<sup>17-20</sup> In our study, the pain duration was significantly different between groups. Testicular ischemia typically presents with sharp pain and epididymo-orchitis presents with indolent or slowly progressive pain.

Logistic regression analysis showed that the chance of testicular torsion decreased by 2% when the pain increased by 1 hour. However, patients or parents are often not so sure about the exact time of onset. Also, spontaneous detorsion and recurrent torsion are not uncommon, which could make the exact time of onset vague. A pain scale with a range of 1 to 10 to differentiate the

## ORIGINAL ARTICLE

---

severity of scrotal pain, might with the pain duration. A negative Prehn's sign, a high-riding testicle and loss of the cremasteric reflex might help in differentiation. In addition, logistic regression analysis showed the odds ratio for left side scrotal pain was 1.03, which means left side testicular torsion predominates. This could be anatomically related to the greater length of the left side spermatic cord which could have a higher incidence of twisting <sup>21</sup>Further detailed records should be emphasized in the next prospective study. Laboratory study showed that patients with epididymo-orchitis had higher rates of elevated inflammatory parameters, although there was no significant difference in multivariate analysis. However, not all patients completed all the laboratory examinations and further laboratory criteria should be used for comparison in further prospective study. Ultrasound has been increasingly used in the clinical evaluation of testicular pathology <sup>22</sup>. Ultrasound has proved to be a somewhat quite desirable modality in our study; 60.95% was not contributory. Special attention should be paid to the fact that spontaneous reduction with repeated torsion can reveal the picture as reactive hyperperfusion of the testicular parenchyma. A further exception is epididymo-orchitis complicated by testicular infarction, which probably arises as a consequence of edema compromising venous drainage leading to thrombosis of the pampiniform plexus. An experienced urologist might observe that a reversal of diastolic flow in the testicular artery is characteristic of venous thrombosis. Nonetheless, if facilities allow, scintigraphy may give some more information, by showing increased peripheral flow and central hypoperfusion, whereas with torsion peripheral flow will be normal.

**CONCLUSION:** Two not uncommon and potentially serious conditions are testicular torsion and epididymo-orchitis. To achieve the best possible outcome in these testicular conditions, it is critical to differentiate from other etiologies, perform an appropriate evaluation including physical examination and diagnostic testing (USG), and develop an optimal course of management. Because a delay in diagnosis and management can lead to loss of gonadal function which occurs so rapidly in TT, surgical exploration should neither be delayed for sonography nor be denied because of negative imaging in all acute scrotal swelling cases. Outcomes directly depend on the duration of ischemia; thus, time is of the essence.

**ACKNOWLEDGEMENT:** I thank all the staff, both teaching and non-teaching staff of ICH&HC, MMC, Chennai for their co-operation and support. I thank Dr. Veena Patil; post-graduate student for her help in writing the article.

### REFERENCES:

1. Gunther P, Schenk JP, Wunsch R, Holland-Cunz S, Kessler U, Troger J, Waag KL. Acute testicular torsion in children: the role of sonography in the diagnosis workup. *Eur Radiol* 2006; 16:2527-32.
2. Blaivas M, Batts M, Lambert M. Ultrasound diagnosis of testicular torsion by emergency physicians. *Am J Emerg Med* 2000; 18:198-200
3. Tumeh SS, Benson CV, Richie JP. Acute diseases of the scrotum. *Semin Ultrasound CT MRI* 1991; 2:115-30.
4. Ringdahl E, Teague L. Testicular torsion. *Am Fam Physician* 2006; 74:1739-4.
5. Rabinowitz R, Hulbert WC. Acute scrotal swelling. *Urol Clin North Am* 1995;22:101-5.

## ORIGINAL ARTICLE

---

6. Steinhardt GF, Boyarsky S, Mackey R. Testicular torsion: pitfalls of color Doppler sonography. *J Urol* 1993; 150:461-462.
7. Ingram S, Hollman AS, Azmy A. Testicular torsion: missed diagnosis on colour Doppler sonography. *Pediatr Radiol* 1993; 23:483-484.
8. Pryor L, Watson LR, Day DL, et al. Scrotal ultrasound for evaluation of subacute testicular torsion: sonographic findings and adverse clinical implications. *J Urol* 1994; 151:693-697.
9. Allen TD, Elder JS. Shortcomings of color Doppler sonography in the diagnosis of testicular torsion. *JUrol* 1995; 154:1508-1510.
10. Nussbaum Blask AR, Bulas D, Shalaby-Rana E, Rushton G, Shao C, Majd M. Color Doppler sonography and scintigraphy of the testis: a prospective, comparative analysis in children with acute scrotal pain. *Pediatr Emerg Care* 2002; 18:67-71.
11. Paltiel HJ, Connolly LP, Atala A, Paltiel AD, Zurakowski D, Treves ST. Acute scrotal symptoms in boys with an indeterminate clinical presentation: comparison of color Doppler sonography and scintigraphy. 1998; 207:223-231.
12. Albrecht T, Lotzof K, Hussain HK, Shedden D, Cosgrove DO, de Bruyn R. Power Doppler US of the normal prepubertal testis: does it live up to its promises? *Radiology* 1997; 203:227-231.
13. Luker GD, Siegel MJ. Scrotal US in pediatric patients: comparison of power and standard color Doppler US. *Radiology* 1996; 198:381-385.
14. Ingram S, Hollman AS. Colour Doppler sonography of the normal paediatric testis. *Clin Radiol* 1994; 49:266-267.
15. Wampler SM, Llanes M. Common scrotal and testicular problems. *Prim. Care*. 2010; 37:613Y26
16. Mor Y, Pinthus JH, Nadu A, Raviv G, Golomb J, Winkler H, Ramon J. Testicular fixation following torsion of the spermatic cord - does it guarantee prevention of recurrent torsion events? *J Urol* 2006;175:171-4.
17. Chapman RH, Walton AJ. Torsion of the testis and its appendages. *Br Med J*. Jan 15 1972;1 (5793):164-6.
18. Bartsch G, Frank S, Marberger H, Mikuz G. Testicular torsion: late results with special regard to fertility and endocrine function. *J Urol* 1980;124:375-8.
19. Barkley C, York JP, Badalament RA, Nesbitt JA, Smith JJ, Drago JR. Testicular torsion and its effects on contralateral testicle. *Urology* 1993;41:192-4.
20. Ryan PC, Whelan CA, Gaffney EF, Fitzpatrick JM. The effect of unilateral experimental torsion on spermatogenesis and fertility. *Br J Urol* 1988;62:359-66.
21. Williamson RCN. Torsion of the testis and allied conditions. *Br J Surg* 1976;63:465-76.
22. Sidhu PS. Clinical and imaging features of testicular torsion. *Clin Radiol* 1999;54:343-52.

# ORIGINAL ARTICLE

---

## **AUTHORS:**

1. Naushad Ali N. Malagi
2. Rathinasamy
3. Nedunchelian
4. T.R.K. Madhavan

## **PARTICULARS OF CONTRIBUTORS:**

1. Associate Professor, Department of Pediatrics, Al-Ameen Medical College, Bijapur.
2. Professor, Department of Pediatrics, Institute of Child Health & Hospital for Children, Madras Medical College, Chennai.
3. Professor, Department of Pediatrics, Institute of Child Health & Hospital for Children, Madras Medical College, Chennai.

4. Professor, Department of Pediatric-Surgery, Institute of Child Health & Hospital for Children, Madras Medical College, Chennai.

## **NAME ADDRESS EMAIL ID OF THE CORRESPONDING AUTHOR:**

Dr. Naushad Ali N. Malagi,  
Kausar Manzil, Nehru Nagar,  
Behind KSRTC Depot, Bijapur – 586101  
Karnataka, India.  
Email: drnaushadmalagi@gmail.com

Date of Submission: 08/07/2013.  
Date of Peer Review: 10/07/2013.  
Date of Acceptance: 14/12/2013.  
Date of Publishing: 06/01/2014