

## FISTULOTOMY VERSUS FISTULECTOMY FOR TREATMENT OF FISTULA-IN-ANO

Ravi Kumar H<sup>1</sup>, Sunil Kumar S. R<sup>2</sup>, Siddharth Gosavi<sup>3</sup>

<sup>1</sup>Associate Professor, Department of Surgery, Vydehi Institute of Medical Sciences & Research Centre, Bengaluru.

<sup>2</sup>Assistant Professor, Department of Surgery, Vydehi Institute of Medical Sciences & Research Centre, Bengaluru.

<sup>3</sup>Intern Medical Officer, Department of Surgery, Vydehi Institute of Medical Sciences & Research Centre, Bengaluru.

---

### ABSTRACT

Fistula-in-ano is notorious for its frequent exacerbations, recurrences and its chronic condition. The anorectal abscess is an acute inflammatory process that often is the initial manifestation of the underlying anal fistula and is the chronic condition following inadequate drainage of the abscess. Around 90% of the cases occur due to infected anal glands. Incision and drainage of the abscess cavity will result in complete resolution of the infection in 50% of the patients, whereas in the rest an anal fistula will develop. Most patients with an overt fistula have an antecedent history of abscess that drained spontaneously or for which surgical drainage had been performed. There are different surgeries mentioned in literature. The ultimate goal of fistula surgery is to eradicate it without disturbing or minimally disturbing the anal sphincter mechanism.

### MATERIALS AND METHODS

A total number of 300 patients diagnosed with low fistula-in-ano were included in this clinical study. These 300 patients presented to the general surgery OPD and were admitted under the Department of General Surgery in Vydehi Institute of Medical Sciences and Research Centre during the period of April 2012 to Jan 2016. The patients were not randomized for any imaging modality or surgical procedures. Detailed history including the past history of anorectal abscess and of previous fistula surgery was taken. The mode of presentation, other comorbid conditions like diabetes, the findings on clinical examination (Digital examination and proctoscopy) were recorded in the case sheet for individual patients. Complete blood count, random blood sugar, HIV, HBsAg, sono-fistulogram were done. The discharge from the external opening was sent for culture and sensitivity studies. High anal fistulas and tuberculous fistulas were excluded from the study.

### RESULTS

150 patients were treated with fistulotomy and 150 patients were treated with fistulectomy. More number of males had fistula compared to women; 15 out of 150 patients who underwent fistulectomy had recurrence. However, none of the patients who underwent fistulotomy had any recurrence. Average duration of the patient in the hospital following surgery was 4 days. None of the patients had any anal incontinence. Histopathology report following findings of patients who underwent fistulectomy showed nonspecific inflammation.

### CONCLUSION

According to our clinical study fistulectomy for fistula-in-ano has higher chance of recurrence. Both the surgical procedures had no anal incontinence. Hence, for an uncomplicated low fistula-in-ano fistulotomy is a better surgical procedure.

### KEYWORDS

Fistulotomy, Fistulectomy.

---

**HOW TO CITE THIS ARTICLE:** Kumar RH, Kumar SSR, Gosavi S. Fistulotomy versus fistulectomy for treatment of fistula-in-ano. J. Evolution Med. Dent. Sci. 2016;5(50):3317-3320, DOI: 10.14260/jemds/2016/746

### INTRODUCTION

Fistula-in-ano is notorious for its frequent exacerbations, recurrences and its chronic condition. The anorectal abscess is an acute inflammatory process that often is the initial manifestation of the underlying anal fistula.<sup>1</sup> and is the chronic condition following inadequate drainage of the abscess. Around 90% of the cases occur due to infected anal glands.<sup>2</sup> Incision and drainage of the abscess cavity will result in complete resolution of the infection in 50% of the patients, whereas in the rest an anal fistula will develop.<sup>3,4</sup> Most patients with an overt fistula have an antecedent history of abscess that drained spontaneously or for which surgical drainage had been performed.<sup>5</sup>

There are different surgeries mentioned in literature. The ultimate goal of fistula surgery is to eradicate it without disturbing or minimally disturbing the anal sphincter mechanism.

A fistula-in-ano or anal fistula is a chronic abnormal communication, usually lined to some degree by granulation tissue, which runs outwards from the anorectal lumen (The internal opening) to an external opening on the skin of the perineum or buttock (Or rarely, in women, to the vagina). Anal fistulae may be found in association with specific conditions, such as Crohn's disease, tuberculosis, lymphogranuloma venereum, actinomycosis, rectal duplication, foreign body and malignancy (Which may also very rarely arise within a longstanding fistula) and suspicion of these should be aroused if clinical findings are unusual. However, the majority are termed non-specific, idiopathic or cryptoglandular and intersphincteric anal gland infection is deemed central to them. Patients usually complain of intermittent purulent discharge (Which may be bloody) and pain (Which increases until temporary relief occurs when the pus discharges).

---

Financial or Other, Competing Interest: None.

Submission 04-05-2016, Peer Review 31-05-2016,

Acceptance 06-06-2016, Published 23-06-2016.

Corresponding Author:

Dr. Ravi Kumar H,

No. 28M, Gandhinagar,

Munekola, Marathahalli Post,

Bangalore-560037.

E-mail: dr\_ravikumar2000@yahoo.com

DOI: 10.14260/jemds/2016/746

---

There is often, but not invariably, a previous episode of acute anorectal sepsis that settled (Incompletely) spontaneously or with antibiotics or which was surgically drained. The passage of flatus or faeces through the external opening is suggestive of a rectal rather than an anal internal opening.

The types of anal fistula according to Parks' classification are intersphincteric, trans-sphincteric, suprasphincteric and extrasphincteric primary tracks. Intersphincteric fistulae (45%) do not cross the external sphincter (The most medial subcutaneous fibres running below the distal border of the internal sphincter); most commonly they run directly from the internal to the external openings across the distal internal sphincter, but may extend proximally in the intersphincteric plane to end blindly with or without an abscess or enter the rectum at a second internal opening.

Trans-sphincteric fistulae (40%) have a primary track that crosses both internal and external sphincters (The latter at a variable level) and which then passes through the ischioanal fossa to reach the skin of the buttock. The primary track may have secondary tracks arising from it, which often reach the roof of the ischioanal fossa, which may rarely pass through the levators to reach the pelvis and which may spread circumferentially (Horseshoe). Circumferential spread of sepsis may occur in the intersphincteric and pararectal planes as well as in the ischioanal plane.

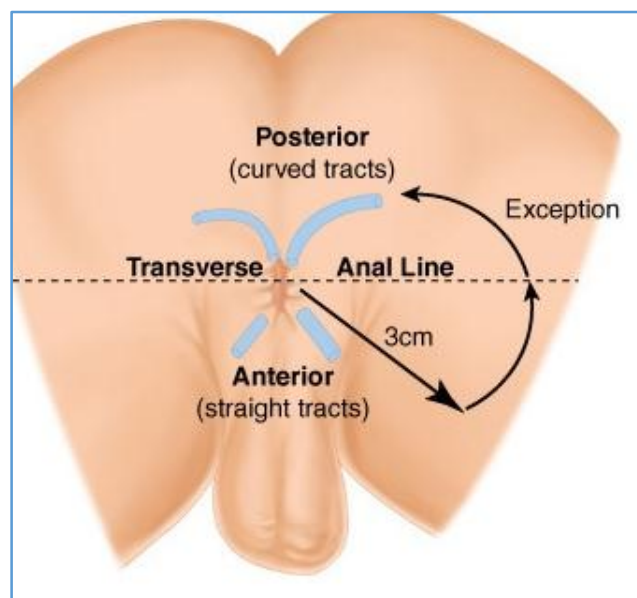
Suprasphincteric fistulae are very rare, are thought by some to be iatrogenic and are difficult to distinguish from high-level trans-sphincteric tracks (For which, fortunately, management strategies are similar). Extrasphincteric fistulae run without specific relation to the sphincters and usually result from pelvic disease or trauma.

Fistulotomy or laying open, is the surest way of getting rid of a fistula, but by definition it involves division of all those structures lying between the external and internal openings. It is therefore applied mainly to intersphincteric fistulae and trans-sphincteric fistulae involving less than 30% of the voluntary musculature (But not anteriorly placed fistulae in women); however, even then it is not immune to postoperative defects in continence. After full examination under anaesthesia in the lithotomy or prone jack-knife position, during which the internal opening should have been identified, a grooved fistula probe is passed from the external to the internal opening, the amount of sphincter below and above the probe is noted and if indicated the track is laid open over the probe. Granulation tissue is curetted and sent for histological appraisal and the wound edges are trimmed. Secondary tracks, often identified as granulation tissue that persists despite curettage should be laid open or drained. Marsupialisation reduces wound size and speeds up healing. Primary tracks crossing the external sphincter more deeply have been managed with good outcomes by fistulotomy and immediate reconstitution of the divided muscle – failure to eradicate all sepsis and subsequent breakdown of the repair, however, are very problematic. Alternatively, a staged fistulotomy may be carried out in which secondary tracks are laid open and only part of the sphincter enclosed by the primary track is divided with the remainder encircled by a loose seton. After sufficient time for healing of the wound and fibrosis, the set on-enclosed track is divided at a second stage.

Fistulectomy involves coring out of the fistula, usually by diathermy cautery; it allows better definition of fistula

anatomy than fistulotomy, especially the level at which the track crosses the sphincters and the presence of secondary extensions. If the sphincteric component of the fistula is deemed low enough to allow safe fistulotomy, then this may proceed (At the expense of longer healing times than conventional fistulotomy). If laying open is not advisable, then the sphincteric component can be managed by another method.<sup>6</sup>

Goodsall's rule can be used as a guide in determining the location of the internal opening. In general, fistulas with an external opening anteriorly connect to the internal opening by a short, radial tract. Fistulas with an external opening posteriorly track in a curvilinear fashion to the posterior midline. However, exceptions to this rule often occur if an anterior external opening is greater than 3 cm from the anal margin. Such fistulas usually track to the posterior midline.<sup>7</sup>



An alternative classification given by Van Koperen et al considers involvement of lower third of external sphincter as a criterion for low fistula.<sup>8</sup>

Anal fistula has also been appropriately classified as simple or complex.<sup>8</sup>

Majority of anal fistula consist of a primary tract extending between external opening and an internal opening and involving lower part of the sphincters. These fistulae can be cured by both fistulotomy and fistulectomy. This group includes subcutaneous, intersphincteric or low trans-sphincteric fistulae and can be categorized as simple anal fistula. This is the criteria we have considered in all our cases of low fistula-in-ano.

## MATERIALS AND METHODS

A total number of 300 patients diagnosed with low fistula in ano were included in this clinical study. These 300 patients presented to the general surgery OPD and were admitted under the Department of General Surgery in Vydehi Institute of Medical Sciences and Research Centre during the period of April 2012 to Jan. 2016. The patients were not randomized for any imaging modality or surgical procedures. Detailed history including the past history of anorectal abscess and of previous fistula surgery was taken. The mode of presentation, other comorbid conditions like diabetes, the findings on clinical

examination (Digital examination and proctoscopy) were recorded in the case sheet for individual patients. Complete blood count, random blood sugar, HIV, HBsAg, sono-fistulogram were done. The discharge from the external opening was sent for culture and sensitivity studies. High anal fistulas and tuberculous fistulas were excluded from the study. The study was commenced after approval from the Vydehi Institute of Medical Sciences and Research Centre Institutional Ethics Committee and is in accordance with the Declaration of Helsinki of 1975 and revised in 2000. Written, informed and understood consent was obtained from the patients before starting the study. Patients also gave consent for the data to be reported and published.

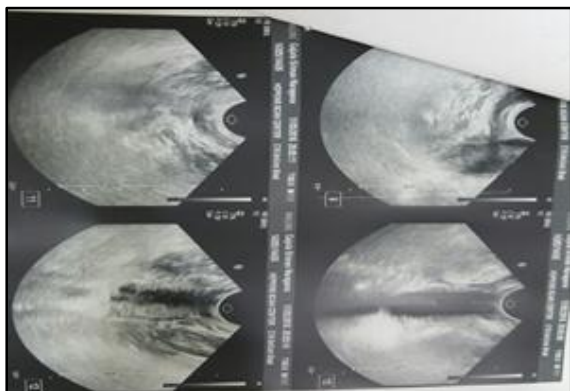
**THE FOLLOWING TWO METHODS WERE ADOPTED FOR TREATING THE PATIENTS**

**Fistulotomy**

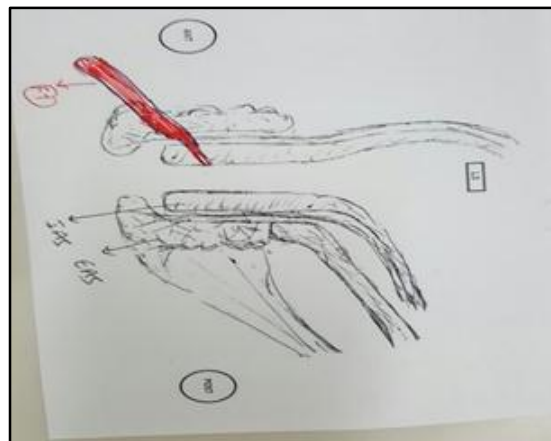
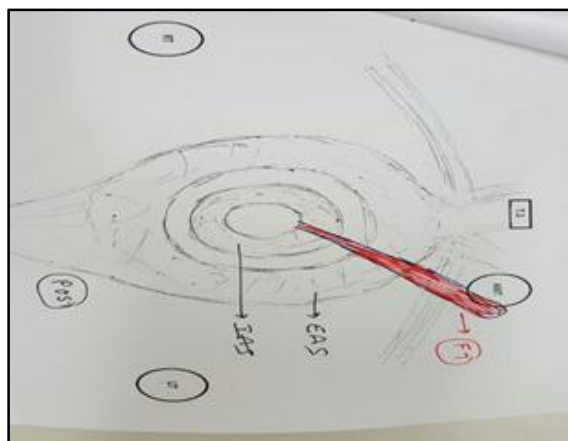
In fistulotomy, the entire tract from the internal opening to the external opening was laid open and haemostasis was achieved. A thorough cleansing with normal saline and Betadine was done. Anal pack was placed for 24 hrs.

**Fistulectomy**

The entire tract was excised in fistulectomy, which was sent for histopathology examination. Primary closure was an option depending on the wound size. On an average inpatient duration of patients undergoing both fistulotomy and fistulectomy was 4 days. After hospital discharge, patients were invited to attend to first follow-up visit 15 days after the initial procedure. The second consultation was on the 45th day. It was considered cured patients who denied leaking stool by wound.



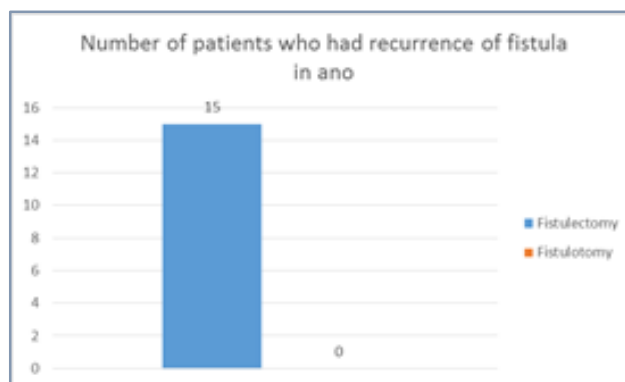
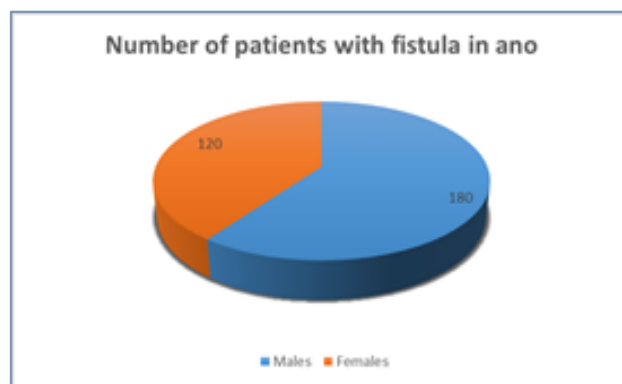
**Depiction of Low Fistula in Transrectal Ultrasound**



**Diagrammatic Representation of Fistulous Tract**

**RESULTS**

150 patients were treated with fistulotomy and 150 patients were treated with fistulectomy.



Average duration of the patient in the hospital following surgery was 4 days. None of the patients had any anal incontinence. Histopathology report following findings of patients who underwent fistulectomy showed non-specific inflammation.

**DISCUSSION**

This study has given an insight into the mode of presentation of anal fistula and the various investigative and treatment modalities, which can be offered to the patient. A digital anorectal examination and proctoscopy were sufficient to establish the diagnosis in approximately 90% of the patients. Sino-fistulogram could yield information regarding the presence of an internal opening and information regarding the fistula tracts relation to the anal sphincter complex. MRI is advisable in cases of complex fistulas. Out of 300 patients in

the study group, a fistulotomy was done in 150 patients and fistulectomy in 150 patients.

Fistulectomy showed 10% recurrence. The recurrent cases after fistulectomy were treated by fistulotomy. The average stay in the hospital in cases of fistulotomy and fistulectomy was approximately the same and the patients recovered well. Of the 150 cases in whom the samples were sent for HPE, they showed nonspecific inflammation.

In a study conducted by Osama Turki Abu Salem to compare the importance of fistulectomy against fistulotomy regarding fistula-in-ano, it was found that the recurrence rate and healing time following fistulectomy is better than fistulotomy.

Out of 272 patients who underwent surgery, 146 patients were in the first group who underwent fistulectomy and the second group was 126 patients who underwent fistulotomy. There were 190 males with (16-60 years) a mean age of 38 years and 82 females with (17-41) a mean age of 29 years. They were all of the same type of fistula (Low type of fistula in ano); other types of fistulas were excluded. The recurrence rate was 8 out of 146 (6%) in the 1st group, while was 13 out of 126 (10%) in the 2nd group. Twenty five patients of fistulectomy (1st) group (17%) complained of pain postoperatively on first postoperative day, while complaint of postoperative pain was noted in thirty three patients of fistulotomy group (26%). No one suffered incontinence in both groups. The postoperative hospital stay period in fistulectomy group was 2 days ranged between 1 to 4 days and that in fistulotomy group was 3 days ranging from 1 to 5 days. The time needed for healing in case of fistulectomy with or without primary closure was about 3 weeks, while in fistulotomy needs about 4 weeks with resolution of symptoms and morbidity of surgery. Over 220 (81%) patients were discharged within 3 days of surgery.<sup>9</sup> However, our study indicates that fistulotomy is a better option than fistulectomy. In our study, there were no recurrences occurring in patients who underwent fistulotomy. Also, in our study the average hospital stay following surgery for the patients was 4 days for both procedures.

In a randomized clinical trial conducted to compare fistulotomy and fistulectomy, forty patients with simple anal fistula were randomized into two groups. Fistulous tracts were managed by using a fistulectomy (Group A), while a fistulotomy with marsupialization was performed in group B. The primary outcome measure was wound healing time, while secondary outcome measures were operating time, postoperative wound size, postoperative pain, wound infection, anal incontinence, recurrence and patient satisfaction. Postoperative wounds in group B healed earlier in comparison to group A wounds (4.85±1.39 weeks vs. 6.75±1.83 weeks, P=0.035). No significant differences existed between the operating times (28.00±6.35 minutes vs. 28.20±6.57 minutes, P=0.925) and visual analogue scale scores for postoperative pain on the first postoperative day (4.05±1.47 vs. 4.50±1.32, P=0.221) for the two groups. Postoperative wounds were larger in group A than in group B (2.07±0.190 cm<sup>2</sup> vs. 1.23±0.87 cm<sup>2</sup>); however, this difference did not reach statistical significance (P=0.192). Wound discharge was observed for a significantly longer duration in group A than in group B (4.10±1.91 weeks vs. 2.75±1.71 weeks, P=0.035). There were no differences in social and sexual activities after surgery between the patients of the two

groups. No patient developed anal incontinence or recurrence during the follow-up period of twelve weeks. In comparison to a fistulectomy, a fistulotomy with marsupialization results in faster healing and a shorter duration of wound discharge without increasing the operating time.<sup>10</sup>

MRI performed adequately should be regarded as the "gold standard" for preoperative assessment, replacing surgical Examination Under Anaesthetic (EUA) in this regard. However, endoanal ultrasonography is used by many surgeons in the preoperative workup of anal fistulas. Although, there are some conflicting results, hydrogen peroxide-enhanced endoanal ultrasonography may be comparable with MRI. Endoanal ultrasound alone is sufficient in more simple cases; however, MRI is generally superior to endoanal ultrasonography. MRI helps not only to accurately demonstrate disease extension, but also to predict prognosis, make therapy decisions and monitor therapy. Missed extensions at surgery are usually the cause of recurrence and adequate surgery is warranted in more extensive disease. MRI has been shown to reduce recurrent disease and therefore reoperation.<sup>11</sup> Therefore, our study could have incorporated MRI, but due to financial constraint of the patient sonofistulogram was done.

## CONCLUSION

According to our clinical study, fistulectomy for fistula-in-ano has higher chance of recurrence. Both the surgical procedures had no anal incontinence. Hence, for an uncomplicated low fistula-in-ano fistulotomy is a better surgical procedure.

## REFERENCES

1. Standring S. Gray's Anatomy. The anatomical basis of clinical practice. 40<sup>th</sup> edn. Philadelphia: Churchill Livingstone 2009:1780-1.
2. Parks AG, Gordon PH, Hardcastle JD. A classification of fistula in ano. *Br J Surg* 1976;63(1):1-12.
3. Zinner M, Ashley SW. Maingot's abdominal operations. 12<sup>th</sup> edition. New York: McGraw Hill Company 2013:1443-51.
4. Fry RD, Birnbaum EH, Lacey DL. Actinomyces as a cause of recurrent perianal fistula in the immune compromised patient. *Surgery* 1992;111(5):591-4.
5. Barwood N, Clarke G, Levitt S, et al. Fistula in ano: a prospective study of 107 patients. *Aust N Z J Surg* 1997;67(2-3):98-102.
6. Williams NS, Bullstrode CJK, O'Connell PR. Bailey and Love Short Practice of Surgery. 25<sup>th</sup> edition. *Fistula in ano* 1263-6.
7. Kelli M, Bullard Dunn. Colon, Rectum and Anus. Chapter 29, Schwartz's Principles of Surgery. 9<sup>th</sup> edition.
8. Jain BK, Garg PK. Anal Fistula, Chapter 87, Textbook of Surgical Gastroenterology. Volumes 1 & 2:1009.
9. Salem OTA. Fistulectomy and fistulotomy for low anal fistula. *RMJ* 2012;37(4):409-11.
10. Jain BK, Vaibhaw K, Garg PK, et al. Comparison of a fistulectomy and a fistulotomy with marsupialization in the management of a simple anal fistula: a randomized, controlled pilot trial. *J Korean Soc Coloproctol* 2012;28(2):78-82.
11. Torkzad MR, Karlbom U. MRI for assessment of anal fistula. *Insights Imaging* 2010;1(2):62-71.