

CASE REPORT

RARE CASE OF LARGE ABDOMINAL AORTIC ANEURISM WITH A BIG THROMBUS

R. Asna¹, Shakeel Khan², Nalini Namoshi³

HOW TO CITE THIS ARTICLE:

R. Asna, Shakeel Khan, Nalini Namoshi. "Rare Case of Large Abdominal Aortic Aneurism with a Big Thrombus". Journal of Evolution of Medical and Dental Sciences 2014; Vol. 3, Issue 15, April 14; Page: 4013-4016, DOI: 10.14260/jemds/2014/2392

ABSTRACT: The most common location of abdominal aortic aneurysms is the infrarenal portion of the aorta including its bifurcation and extending to the iliac arteries.¹ To avoid rupture, which has nearly 90% mortality, early diagnosis and surgery are essential. Acute aortic occlusion, which commonly is secondary to saddle embolus or atherosclerotic thrombosis, has tremendous morbidity and mortality. Angiographic evaluation is very essential for patients with asymptomatic abdominal aortic aneurysms of 4.0-5.5 cm, and surgical intervention is required for rapidly growing or larger aneurysms.²

KEYWORDS: Abdominal aortic aneurysm, Thrombus, Aortogram.

CASE REPORT: A female lady with abdominal discomfort got admitted to the hospital. She also had history of visible lump over the abdomen in epigastric and in umbilical region. She had history of passing frank blood in urine on and off. Patient had four children with all the four delivered normally. Her discomfort increased after her fourth child birth.

EXAMINATION: It revealed a poorly nourished woman with pale texture. Her pulses were bounding in upper limbs and almost normal in lower limbs. Her blood pressure in upper limbs was 150/90 and in lower limbs was 110/70. Examination of abdomen revealed a mass of around 5x4 cms in epigastric region with visible pulsations. The mass was tender to palpate. Expansile pulsations were present. Other systems were in the normal limits.

INVESTIGATIONS: Hb-10.5gm%. Total count of 13,000 cells/mm³ and DC of N- 82%, L-14%, E-03%, and M-01% with ESR of 110mm/hr. Her blood urea was 113mg/dl and serum creatinine was 1.6mg/dl. Urine examination showed the presence of few pus cells and RBCs.

Abdominal CT and Aortogram were done which showed:

1. 105x80x161 sized (APxRLxCC) large aneurysm seen involving descending thoracic aorta and abdominal aorta.
2. Infrarenal abdominal aorta occluded.
3. Peripheral thrombus is seen in superolateral part of aneurysm. Inferiorly extending to a plane of about 35mm distal to origin of left renal artery.
4. Celiac and superior mesenteric arteries hypertrophied.
5. Inferior mesenteric artery occluded.
6. Left sided single renal artery visualized.
7. Near complete occlusion of right renal artery originating at a superior level. Rest of the renal artery showed marked stenosis.
8. 2nd renal artery originating at an inferior level also showed marked stenosis.
9. Right kidney shrunken.

CASE REPORT

CASE DISCUSSION: Abdominal aortic aneurysms occur more frequently in males than in females, and the incidence increases with age. Abdominal aortic aneurysms of more than 4.0 cm may affect 1–2% of men older than 50 years. At least 90% of all abdominal aortic aneurysms >4.0 cm are related to atherosclerotic disease, and most of these aneurysms are below the level of the renal arteries.⁽³⁾ Prognosis is related to both the size of the aneurysm and the severity of coexisting coronary artery and cerebrovascular disease. The risk of rupture increases with the size of the aneurysm: the 5-year risk for aneurysms <5 cm is 1–2%, whereas it is 20–40% for aneurysms >5 cm in diameter. The formation of mural thrombi within aneurysms may predispose to peripheral embolization.^{3,4}

An abdominal aortic aneurysm commonly produces no symptoms. It is usually detected on routine examination as a palpable, pulsatile, expansile, and nontender mass, or it is an incidental finding during an abdominal x-ray or ultrasound study performed for other reasons. As abdominal aortic aneurysms expand, however, they may become painful. Some patients complain of strong pulsations in the abdomen; others experience pain in the chest, lower back, or scrotum⁵. Aneurysmal pain is usually a harbinger of rupture and represents a medical emergency. More often, acute rupture occurs without any prior warning, and this complication is always life-threatening. Rarely, there is leakage of the aneurysm with severe pain and tenderness. Acute pain and hypotension occur with rupture of the aneurysm, which requires emergency operation.^{5,6}

Abdominal radiography may demonstrate the calcified outline of the aneurysm; however, about 25% of aneurysms are not calcified and cannot be visualized by plain x-ray. An abdominal ultrasound can delineate the transverse and longitudinal dimensions of an abdominal aortic aneurysm and may detect mural thrombus. CT with contrast and MRI are accurate, noninvasive tests to determine the location and size of abdominal aortic aneurysms and to plan endovascular or open surgical repair. Contrast aortography may be used for the evaluation of patients with aneurysms, but the procedure carries a small risk of complications, such as bleeding, allergic reactions, and atheroembolism. Since the presence of mural thrombi may reduce the luminal size, aortography may underestimate the diameter of an aneurysm.^{6,7}

Operative repair of the aneurysm and insertion of a prosthetic graft are indicated for abdominal aortic aneurysms of any size that are expanding rapidly or are associated with symptoms.⁸

DD:

1. PYLORIC OBSTRUCTION.
2. PANCREATIC CYST.
3. DUODINAL MASS.

REFERENCES:

1. Harrison's text book of principles of internal medicine 18e. Chapter 248. Diseases of aorta: 4166-4180.
2. Blankensteijn JD et al. Two-year outcomes after conventional or endovascular repair of abdominal aortic aneurysms. *N Engl J Med* 352:2398, 2005[PMID: 15944424].
3. Creager MA et al (eds). *Vascular Medicine: A Companion to Braunwald's Heart Disease*. Philadelphia, Saunders, 2006.

CASE REPORT

4. Fleming C et al. Screening for abdominal aortic aneurysm: A best-evidence systematic review for the U.S. Preventive Services Task Force. *Ann Intern Med* 142:203, 2005[PMID: 15684209]
5. Isselbacher EM. Thoracic and abdominal aortic aneurysms. *Circulation* 111:816, 2005[PMID: 15710776].
6. Lederle FA et al. Systematic review: Repair of unruptured abdominal aortic aneurysm. *Ann Intern Med* 146:735, 2007[PMID: 17502634].
7. Patel HJ, Deeb GM. Ascending and arch aorta: Pathology, natural history, and treatment. *Circulation* 118:188, 2008[PMID: 18606928].
8. Schermerhorn ML et al. Endovascular vs. open repair of abdominal aortic aneurysms in the Medicare population. *N Engl J Med* 358:464. 2008.

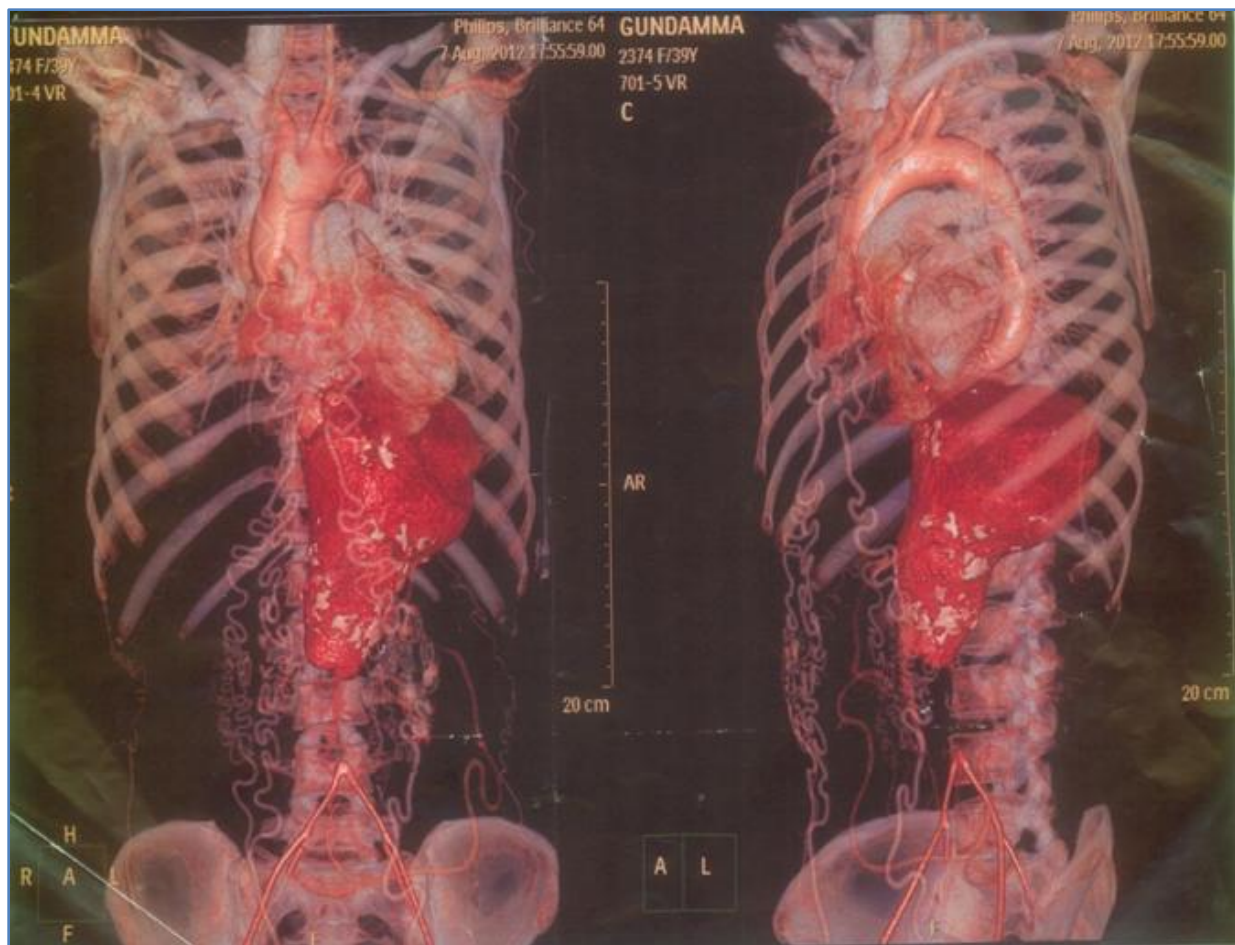


Fig. 1: CT Contrast aortography showing abdominal aortic aneurysm with a large thrombus

CASE REPORT

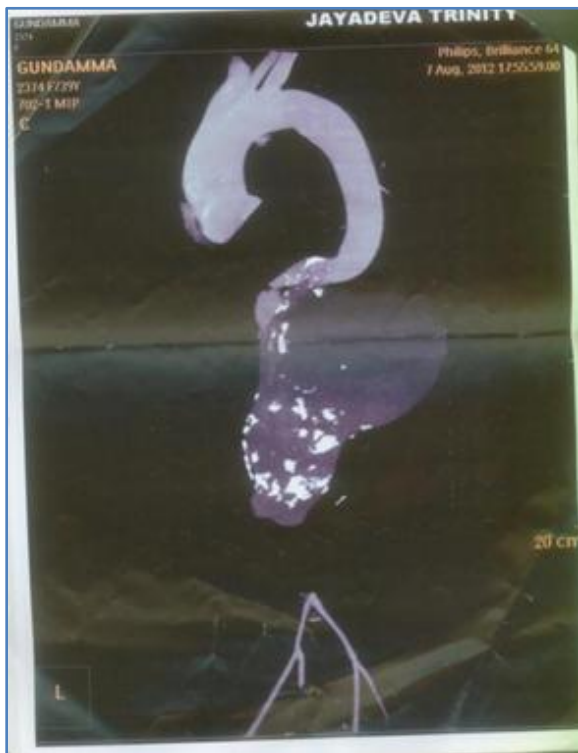

Fig. 2: Aortogram showing large thrombus

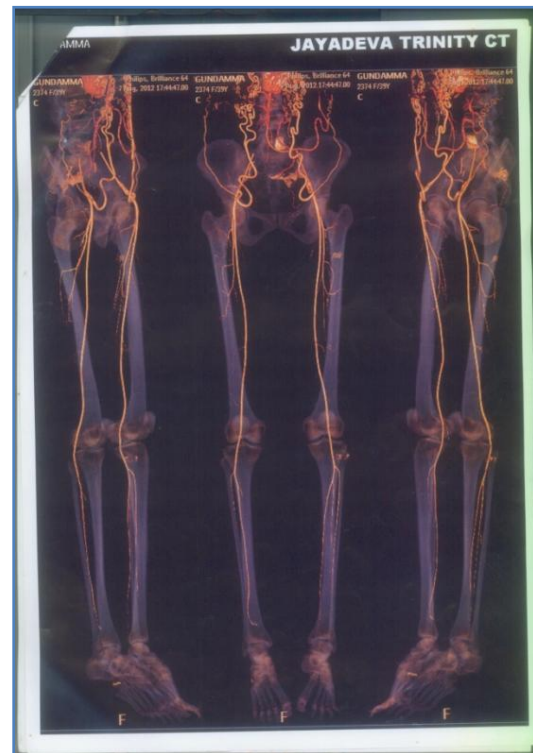


Fig. 3: CT angiography of both lower limbs

AUTHORS:

1. R. Asna
2. Shakeel Khan
3. Nalini Namoshi

PARTICULARS OF CONTRIBUTORS:

1. Senior Specialist, Department of Medicine, District Hospital, Gulbarga.
2. Paediatrician, Department of Paediatrics, Alnoor Speciality Centre, Gulbarga.
3. Dist. Surgeon, Department of Obstetrics and Gynaecology, District Hospital, Gulbarga.

NAME ADDRESS EMAIL ID OF THE CORRESPONDING AUTHOR:

Dr. Ruqia Asna Rabah,
H. No. 5-800, Roza (R),
Gulbarga – 585104.
E-mail: drasnakhan@gmail.com

Date of Submission: 12/03/2014.
Date of Peer Review: 13/03/2014.
Date of Acceptance: 24/03/2014.
Date of Publishing: 12/04/2014.