

CLINICAL STUDY OF ANORECTAL MALFORMATIONSUmesh N¹, Sowmya M²**HOW TO CITE THIS ARTICLE:**

Umesh N, Sowmya M. "Clinical Study of Anorectal Malformations". Journal of Evolution of Medical and Dental Sciences 2015; Vol. 4, Issue 09, January 29; Page: 1466-1473, DOI: 10.14260/jemds/2015/206

ABSTRACT: BACKGROUND: Anorectal malformations are relatively encountered anomalies. Presentations may vary from mild to severe and bowel control is the main concern. **AIM:** To study the modes of presentation, types of anomalies, associated anomalies, reliability of clinical signs and radiological investigations in the diagnosis and the prognosis and continence in the post-operative in relation to type of anomaly and associated anomaly (s). **MATERIAL AND METHODS:** 50 cases of anorectal malformations admitted to Department of Paediatric Surgery, in Medical College and Research Institute, were included in the study. Data related to the objectives of the study were collected. **RESULTS:** Commonest mode of presentation was failure to pass meconium 50%. 59% of males had high anomalies, while 53% females had intermediate anomalies. The diagnosis of low anomaly was made clinically, while high and intermediate anomalies needed further investigations. Associated anomalies were noted in 46.6% of the cases. 71.42% of these patients had either a high or intermediate ARM. All patients with high anomalies underwent a 3 stage procedure, while low anomalies underwent a single stage procedure followed by anal dilatations. Rectal mucosal prolapse (2 cases), wound infection (4 cases), stenosis (3 cases), retraction of neo anus (1 case) was seen. All the patients with low anomalies had a good functional result post operatively, while 57% and 28% of patients with intermediate and high anomalies had good results. **CONCLUSION:** Anorectal malformations are common congenital anomalies. Males are more commonly affected (1.3:1). Low anomalies are the commonest lesions noted in both the sexes (36.67%). High anomalies are more frequent in males. Invertogram offer an accurate diagnosis for planning management in patients with anorectal malformations. Low anomalies have a better outcome following surgery. For intermediate and high anomalies a staged repair offers better results. The situation would improve further if MRI Imaging is more readily available and these children are brought for appropriate treatment at the earliest.

KEYWORDS: Anorectal malformation; Invertogram; Anorectal stenosis, Functional outcome.

INTRODUCTION: Anorectal malformations (ARM) presents with imperforate anus and persistent cloaca occur 1 in 5000 live births and affect male and female equally. The embryological basis includes failure of descent of urorectal septum. The most frequent defect in males is imperforate anus with rectourethral fistula and in females rectovestibular defect. Approximately 60% of them have associated malformations. The most common is urinary tract defect occurs in 50% of patients.

They can have variable clinical presentations ranging from mild forms which require minor surgical interventions, complicated cases need to manage with multi-staged operations. ARM can be non-syndromic, syndromic, sporadic or familial with different modes of inheritance.¹

The main concern for the future children with anorectal malformation is bowel control and urinary control. In extreme cases sexual function is also compromised. Most of the times, early diagnosis, followed by an efficient and meticulous repair results in good bowel control.

The present prospective study includes 50 consecutive cases of anorectal malformations admitted to Department of Paediatric Surgery.²

ORIGINAL ARTICLE

AIM: The present study was done to find out the various clinical manifestations, sex incidence, types, management and outcome of anorectal malformations.

MATERIAL AND METHODS: 50 cases were taken for clinical study and analysis. In these all types of congenital anorectal anomalies are included and importance is given to those cases where all stages of treatment and follow up are completed. A detailed history was recorded on admission. Special attention was given to the pregnancy history to detect any complications during pregnancy, Congenital malformation in the family and relatives were enquired into, apart from consanguinity and parity of the mother. Blood and urine examination, invertogram, ultrasound abdomen was done. The data presented in the form of a master chart.

Routine pre-operative preparations were done. Intraoperatively precautions were taken to prevent heat loss and to replace the blood and fluid loss. All cases were operated under general anaesthesia with endotracheal intubation. Operative procedures for-Low anomalies: Anoplasty, cutback V-Y Anoplasty, Primary minimal PSARP, Intermediate anomalies: Anoplasty followed by limited PSARP, High anomalies: 3 stage repair with colostomy, PSARP and colostomy closure was done. Oral fluids were started post operatively after the colostomy started functioning. Instructions on colostomy care were given on discharge and instructed to come for regular follow up to monitor the growth and development. If the general condition was good after an interval of 3-6 months, then they were subjected to the definitive procedure.

The definitive procedure after colostomy was a posterior sagittal anorectoplasty (PSARP) in our series. Distal colonic washes were done with normal saline to wash out debris from the blind rectal pouch at least 2 days prior to surgery. Oral fluids were started as early as the evening of surgery depending on the patients' condition. Post operatively the patients were started on anal dilatation after 2 weeks. Once the desired size of the anus is achieved by dilatation, the colostomy was closed by a limited resection and anastomosis.

Then patient was kept nil by mouth till patient passed stools through the anus. Discharge from the hospital was on the 10th post-operative day after suture removal. Patients were advised to come for weekly follow up and to continue anal dilatations. During follow up the local area was examined and parents enquired about the bowel movements. Assessment was based on the Kelly score.

RESULTS: About 50 cases of congenital anorectal malformations were taken for the study. Out of 50 cases 27 patients were males and 23 were female patients. Out of 27 male patients 10 had high anomalies and 17 had low anomalies. Out of 23 female patients 2 had intermediate anomalies, 21 had low anomalies. Commonest mode of presentation in the neonatal period was the failure to pass meconium after birth with or without the presence of anal opening.

It was seen in 23 patients. Among the female patients 10 presented with passing of stools from vestibule/vagina. 11 patients presented with constipation or narrow anal opening and 16 patients presented with absent anal opening and history of not passing meconium since birth. 11 patients had anteriorly placed anal opening/ (Anterior ectopic anus). 7 patients presented with passing meconium in urine. Consanguineous marriage was noted in 8 out of the 50 cases. 45 patients had a hospital delivery and 5 of them had a home delivery.

ORIGINAL ARTICLE

Sl. No.	Modes of presentation	No. of patients
1	Not passed stools / meconeum since birth	23
2	Anteriorly placed anal opening	11
3	Meconeum in urine	7
4	Bulge in perineum with absent anus	16
5	Constipation / narrow anal opening	11
6	Passing meconeum from vagina/vestibule	10
7	Vomiting / abdominal distention	23

Table 1: Modes of presentation

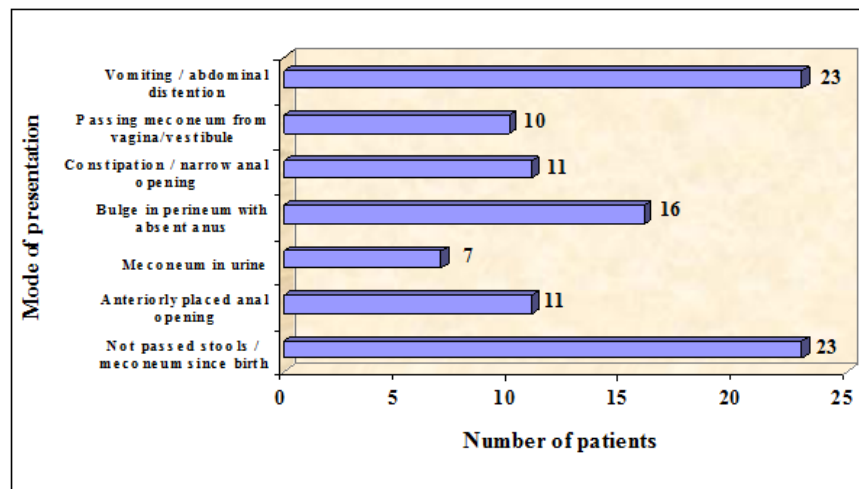


Figure 1: Modes of presentation

A clinical diagnosis of low and intermediate anomalies was made in almost all the cases in both males and females. Both intermediate anomalies were found in females, out of which both were rectovestibular fistulae. All the 10 high anomalies in the male patients had absent anal opening and needed invertogram for confirmation. A total of 10 out of 50 patients underwent preliminary colostomy. Transverse loop colostomy was performed in 7 patients and remaining 3 patients had sigmoid colostomy. Once the final diagnosis regarding the type of anomaly was made, it was found that low anomalies were more common than high anomalies, 38 and 10 cases out of 50 respectively.

Male patients	
High anomalies	10 patients. 3 had rectal atresia
Intermediate anomalies	None
Low anomalies	17 cases (6 membranous anus, 6 anocutaneous fistula, 5 anal stenosis)
Female patients	
High anomalies	None
Intermediate anomalies	2 rectovestibular fistula
Low anomalies	21 cases (5 ano cutaneous, 6 anal stenosis, 2 membranous anus, 8 anovestibular fistula)
Cloaca / rare anomalies	None

Table 2: Sex wise incidence of anomalies

ORIGINAL ARTICLE

	Sex	Anocutaneous fistula	Anal stenosis	Membrane anus	Anovestibular fistula
Present study	Males	15.78%	13.15%	5.26%	0.00%
	Females	13.15%	15.78%	15.78%	21.05%

Table 3: Comparative distribution of low anomalies

	Sex	Fistula	No fistula
Present study	Males	48.1%	51.9%
	Females	56.5%	43.5%

Table 4: Comparative relation of fistula among males and females

Investigations were done for confirmation of diagnosis and to plan for treatment. Management for 1) High anomalies-All 10 patients were males, underwent colostomy. Subsequently underwent PSARP. Closure of colostomy was the final procedure undertaken once the perineal wound healed well and was dilated to adequate size. 2) Intermediate anomalies-2 underwent cut back anoplasty as the primary procedure followed by limited PSARP.3) Low anomalies-8 cases of membranous anus underwent anoplasty. 11 of ano-cutaneous fistula, out of which 6 under-went cut back V-Y anoplasty and 5 underwent limited PSARP. 11 case of anal stenosis underwent V-Y anoplasty. 8 case of ano vestibular fistula underwent primary limited PSARP. Complications noted in low anomalies were wound infection (3 cases), anal stenosis (2 cases) and in colostomy were excoriation (4 cases), bleeding (1 case), constipation (1 case), and wound infection (2 cases).

Complications following the definitive procedure for high and intermediate anomalies were, stenosis, wound infection. Follow up period from 2 weeks to 2 years. The physical and mental development milestones of the child were assessed. The overall growth of the child was also monitored. The accurate assessment of the sphincteric control was possible only after the age of 2 years. Assessment of results was done based on the Kelly's score. A score of 5 – 6 was considered good, 3– 4 as fair and 1– 2 as poor.

Results	Number of cases	Percentage
Good	45	90
Fair	4	8
Poor	1	2
Total	50	100

Table 5: Results of surgery

ORIGINAL ARTICLE

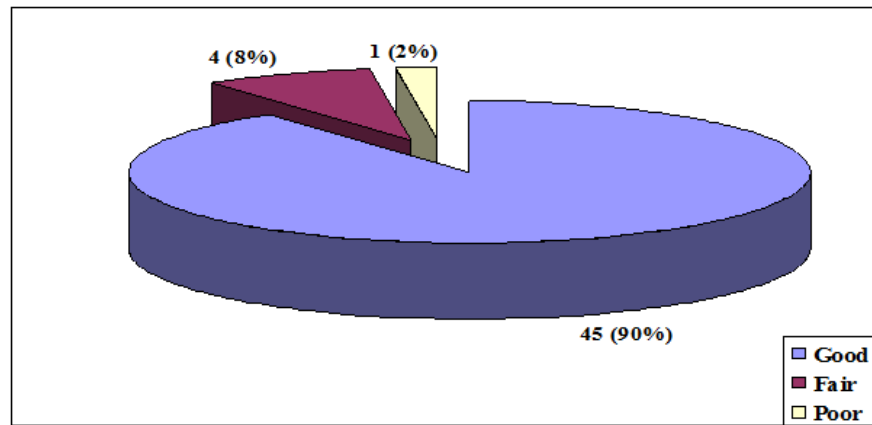


Figure 2: Results of surgery

Type of anomaly	Good	Fair	Poor
Low	94.73%	5.27%	0
Intermediate	50%	50%	0
High	80%	10%	10%

Table 6: Results in different anomalies

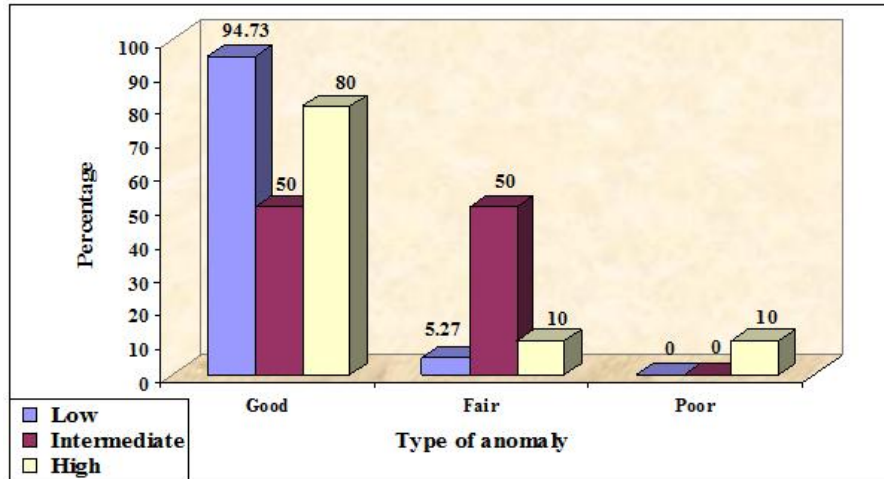


Figure 3: Results in different anomalies

Sex	Good	Fair	Poor
Males	92.59%	3.70%	3.70%
Females	86.95%	13.05%	0%

Table 7: Results in males and females

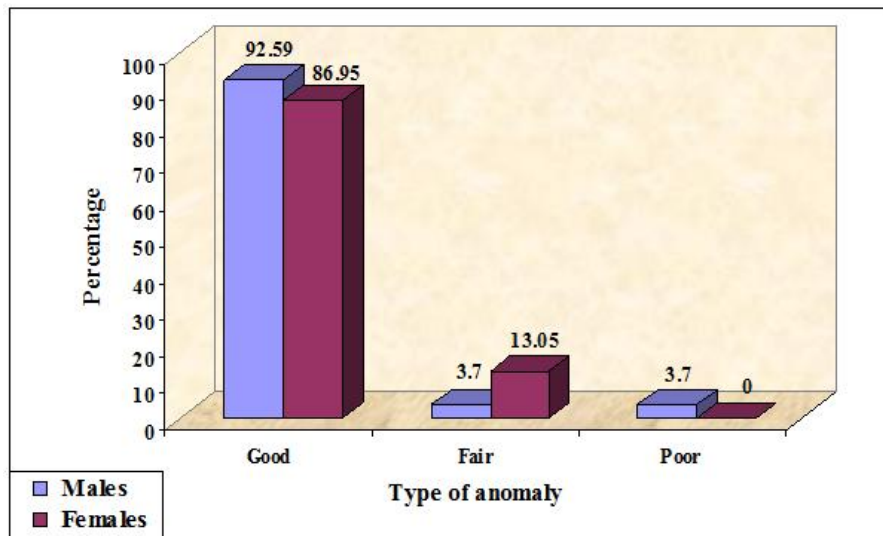


Figure 4: Results in males and females

DISCUSSION: The present study of 50 cases of anorectal malformation (ARM) was meant to study the various types, mode of presentation and management. Incidence in India has been reported at 1:6000 live births. Our series has included sporadic referrals from around the region, from different districts and also children presenting later in life. Higher incidence of ARM among males. Low anomalies are the commonest type of ARM. Low anomalies are common in females and high anomalies are commoner in males. Anocutaneous fistula was the commonest in low anomalies. In intermediate anomalies, rectobulbar urethral fistula was the main anomaly noted in males, in females rectovestibular fistula was the commonest.

In high anomalies recto prostatic urethral fistula was the commonest case. Majority of patients with anorectal malformations present early in the neonatal period 48(96%) of them presented in the first 28 days of life. we had a higher incidence of neonatal presentations. Those who presented late were females with an external fistula that was mistaken for a normal anus. Associated with this these patients had an unattended birth at home where a thorough search for congenital anomalies is usually not made. Clinical presentation was newborn passing meconium/stools from an abnormal opening. The other group presented with symptoms suggestive of intestinal obstruction. In the study symptoms of not passing stools/meconium were the commonest presentation (46%). Diagnosis was made by clinical examination most often reveals the nature of anomaly by presence of an external fistula or meticulous perineal inspection.

The surgical procedures performed for low anomalies were anoplasty, cut back anoplasty, primary minimal PSARP. In our series we have performed 8 anoplasty, 6 cut back V-Y Anoplasty, 11 V-Y Anoplasty, 5 limited PSARP and 8 primary limited PSARP. The advantage of performing a posterior sagittal anoplasty in the situation is to replace the anus at its normal site without causing any injury to the adjacent structures. The outcome is uniformly good in all the procedures that are performed for low anomalies. For intermediate anomalies among 2 cases of Intermediate ARM, all were female patients had recto-vestibular fistula, underwent cut back anoplasty followed by limited PSARP. For high anomalies all the 10 patients underwent preliminary colostomy as part of 3 stage repair and subsequently underwent PSARP and colostomy closure. Postoperative complications

ORIGINAL ARTICLE

following colostomy are Diarrhoea, Prolapse, Excoriation, Haemorrhage, Retraction/Necrosis, Wound infection. In the study excoriation and wound infection was noted more often, Local complications of the neo-anus include wound infection, dehiscence, stenosis, retraction/necrosis and rectal mucosal prolapse. In the study, wound infection (5 cases), stenosis (2 cases), excoriation (4 cases), constipation (1 case) and bleeding (1 case) were noted. All of them were treated conservatively followed by anal dilatation. Abdominal complications noted were mild wound infection which was treated conservatively. The duration of follow up varies from 2 months to 24 months.

CONCLUSION: Males are more commonly affected by this condition (1.17:1). Most of the children (96 %) presented within 28 days after birth. Low anomalies are the commonest, noted in both the sexes (76.00%). High anomalies are more frequent in males. In the study high anomalies noted in males. Low anomalies have better outcome following surgery. For intermediate and high anomalies a staged repair offers better results, Posterior Sagittal Ano Rectoplasty (PSARP) approach in treating these patients' offers more accurate correction. 90% of children had good results.

BIBLIOGRAPHY:

1. Grosfeld JL. ARM – a Historical Overview. In: Holschneider AM, Hutson JM editors. Anorectal malformations in children, embryology, diagnosis, surgical treatment, follow-up. Berlin: Springer; 2006. p. 3-10.
2. Wangenstein OH, Rice CO. Imperforate anus. *Ann Surg* 1930; 92:77.
3. Rehbein F. Imperforate anus: Experience with abdominal-perineal and abdominal-sacral-perineal pull through procedures. *JPS* 1967; 12:99.
4. Pena A., deVries PA. Posterior sagittal ano-rectoplasty: important clinical consideration and new applications. *JPS* 1982; 17:796.
5. Pena A. Current management of Anorectal anomalies. *Surgical clinics of North America* 1992; 72(6):1393-416.
6. Tuggle DW. Operative Treatment of Anterior Ectopic Anus. The Efficacy and Influence of Age or Results. *Journal of Pediatric Surgery* 1990; 25(9):996-8.
7. Langemeijer RATM, Rotterdam JCM. Continence after posterior sagittal anorectoplasty. *J of Pediatric Surg* 1991; 26 (5): 587-90.
8. Rintala R, Mildh L, Lindahl H. Faecal continence and quality of life for adult patients with an operated high or intermediate anorectal malformation. *J Paediatric Surg* 1994; 29 (6): 777-80.
9. Ragnhild E. Anal endosonography and physiology in Adolescent with corrected Low Anorectal Anomalies. *J Paediatric Surgery* 1994; 29 (3): 447-51.
10. Georgeson KE. Laparoscopic assisted anorectal pull-through for high imperforate anus – a new technique. *J Pediatr Surg* 2000; 35: 927-31.
11. Rintala R. Do children with Repaired low Ano rectal Malformation, Have Normal bowel Function. *Journal of Pediatric Surgery* 1997;32(6):823-6
12. Patrick J. Immediate and long term Results of Surgical Management of low Imperforate Anus in Girls. *J of Paediatric Surgery* 1998; 33 (2):198-203.
13. Freeman NV. Ano rectal anomalies. In: Rickham PP, Johnson JH editors. Neonatal surgery. London: Butterworth Co; 1963. p. 633.
14. Reffensperger JG. Swenson's pediatric surgery. 5th ed. Norwalk (CN): Appleton and Lange; 1990. p. 87-621.

ORIGINAL ARTICLE

15. Hutson JM, Sebastiaan CJ. The Embryology of Anorectal Malformations. In: Holschneider AM, Hutson JM editors. Anorectal malformations in children, embryology, diagnosis, surgical treatment, follow-up. Berlin: Springer; 2006. p. 49-62.
16. Sinnatamby CS. Last's Anatomy Regional and Applied. 10th ed. Edinburgh: Churchill Livingstone; 1994. p. 280-4.
17. Shafiq A. A new concept of the anatomy of the anal sphincter mechanism and the physiology of defecation. Investigative Urology 1975; 12: 412.
18. Schouten WR, Gordon PH. Anorectal physiology. In: Gordon PH, Nivatvongs S, editors. Principles and practise of surgery of the colon, rectum and anus 2nd ed. New York: Quality Medical Publishing Inc; 1999. p. 55-87.
19. Stephen FD, Smith ED. Ano rectal malformation in children. Chicago: Book Medical; 1971.
20. Murphy F, Puri P, Hutson JM, Holschneider AM. Incidence and Frequency of Different Types and Classification of Anorectal Malformations. In: Holschneider AM, Hutson JM editors. Anorectal Malformations in Children, Embryology, Diagnosis, Surgical Treatment, Follow-up. Berlin: Springer; 2006. p. 163-81.
21. Lawson J. Anorectal agenesis. In: Keighley MRB, Williams NS, editors. Surgery of the anus, rectum and colon. London: WB Saunders Company Ltd; 1993. p. 2448.

AUTHORS:

1. Umesh N.
2. Sowmya M.

PARTICULARS OF CONTRIBUTORS:

1. Senior Resident, Department of General Surgery, DM Wayanad Institute of Medical Sciences.
2. Senior Resident, Department of Ophthalmology, DM WIMS, Wayanad.

NAME ADDRESS EMAIL ID OF THE CORRESPONDING AUTHOR:

Dr. Umesh N,
1359, 5th Stage,
6th Main, Ist Phase,
BEML Layout,
Rajarajeshwari Nagar,
Bangalore-98.
E-mail: umeshn.doc@gmail.com

Date of Submission: 08/01/2015.
Date of Peer Review: 09/01/2015.
Date of Acceptance: 19/01/2015.
Date of Publishing: 27/01/2015.