

HISTOGENESIS AND MORPHOGENESIS OF HUMAN LARYNGEAL EPITHELIUM: A PRENATAL STUDYRachna Magotra¹, Sanjay Raina², Shyama K. Razdan³**HOW TO CITE THIS ARTICLE:**

Rachna Magotra, Sanjay Raina, Shyama K. Razdan. "Histogenesis and Morphogenesis of Human Laryngeal Epithelium: A Prenatal Study". Journal of Evolution of Medical and Dental Sciences 2015; Vol. 4, Issue 28, April 06; Page: 4816-4821, DOI:10.14260/jemds/2015/698

ABSTRACT: The anatomy of epithelium of human foetal larynx has not been fully described. In the present study we observed the development of epithelium of human larynx, in 40 fetuses with gestational ages ranging from 75mm C. R. L. (crown rump length) to 220mm C. R. L. (Crown rump length). Tissues were prepared for microtomy by paraffin wax embedding method. Step sections (every fifth) were fixed and stained by Hematoxylin and Eosin (H&E) and Masson's Trichrome method. In the present study, the entire laryngeal cavity is lined uniformly by respiratory epithelium initially, i. e., ciliated pseudostratified columnar type. Later on the epithelium over the true vocal cords and dorsal surface of the epiglottis changes into stratified squamous type. Besides, there is flattening of epithelium, over the true vocal cords as a result of desquamation. Larynx, though is a common organ to reptiles, amphibians and mammals with function of breathing, sound production and preventing food particles going into the trachea but the advancement of human has make it a very important organ for physicians, paediatricians, otorhinolaryngologists etc. So the knowledge of anatomy of fetal airway and its development is important for the diagnosis and treatment of various diseases. Our aim was to study the type of epithelium during different stages of development of human fetal larynx.

KEYWORDS: Larynx, Fetus, Epithelium.

INTRODUCTION: If one wishes to become acquainted with the structure and form of any organ, there is perhaps no better way than to trace its development, step by step back into the earlier embryonic stage as quoted by Harrison D. F. N.⁽¹⁾An important and unusual fact about larynx is that phylogenetically it is eons older than those brain and muscle structures, responsible for the language and articulation.⁽²⁾Larynx, also called the voice box is a two inch, long tube shaped organ, in the neck. In adult males, it lies opposite third to sixth cervical vertebrae, although it is somewhat higher in children (C1- C4) and adult females. The wall of the larynx consists of mucosa, poorly defined submucosa and series of irregularly shaped cartilages connected by joints of fibroelastic membranes and a group of intrinsic skeletal muscles which act upon the cartilages. The laryngeal epithelium is mainly ciliated pseudostratified (ie., respiratory epithelium), where it covers the inner aspects of the larynx, including the posterior surface of epiglottis.

However, over the vocal cords, it is nonkeratinised stratified squamous which protects the tissue from the effects of the considerable mechanical stresses acting on the surface of the vocal cords. According to the various controversial studies conducted on larynx, there was tremendous interest in, what type of cell composes the mucus membrane of larynx? Where is the epithelium squamous and where is it ciliated? Does squamous epithelium occurs in the area of the larynx in which it is present because of a functional or pathological transition or does it begin to differentiate in the embryo as part of an orderly process of development?

ORIGINAL ARTICLE

These questions generated tremendous interest and were debated by every laryngologist HOPP, E. S (1955).⁽³⁾ According to HOPP, E. S. (1955),⁽³⁾ epithelium of the larynx differentiates in a definite pattern throughout embryonic life to achieve its adult appearance, a process called as physiological metaplasia. The embryonic epithelium of the true vocal cord becomes cuboidal and then stratified squamous.

Scanning and thorough study of the available literature thus reveals vast controversy and a difference of opinion regarding the embryogenesis and histogenesis of epithelium of human fetal larynx.

The present study has been undertaken to enable us to study the pattern of development of epithelium of human fetal larynx and compare the results so obtained with those of the earlier studies.

MATERIAL AND METHODS: The present study was carried out on 40 human foetuses ranging from 75 mm C. R. L. to 220 mm C. R. L. The foetuses were collected from operation theatres, labour rooms and obstetric wards of Department of Gynaecology and Obstetrics of Government Medical College, Jammu. Government Hospital, Gandhi Nagar Jammu and various Nursing homes operating in and around Jammu city.

The fetuses were obtained as the byproducts of still births and abortions which were either induced or natural or from hysterotomy procedures. Specimens having any type of congenital malformations were not taken up for the present study. Foetuses were preserved in 10% formalin and their crown lump length was measured with a vernier calliper. Assessment of the age of the foetuses was done, according to the rule described by Hamilton, Boyd and Mossman.⁽⁴⁾ (Table -1). Out of 40 foetuses dissected 15 foetuses were female and 25 were male. Two paramedian incisions were given on the anterior surface of the neck, skin was removed and larynx was removed enbloc along with epiglottis and some part of base of tongue. The tissues was fixed in 10% formalin for 7 to 10 days and prepared for microtomy by paraffin wax embedding method. 7 micron thick step sections (every 5th) were taken for fixation and staining. Staining was done by Harris Haematoxylin and Eosin stain (H and E) and Massons's Trichrome stain.

OBSERVATIONS: The human foetuses were divided into four groups (Table 2).

Group- I (75mm- 125mm C. R. L.).

Nine foetuses were dissected in this group. The lining epithelium of the entire laryngeal cavity is pseudostratified columnar and the cells appear to be arranged in several layers as their nuclei are situated at different levels. In the present study, the cilia are seen on the epithelial surface lining the ventricular cavity at 112 mm C. R. L. Basement membrane is visible separating the surface epithelium from the underlying connective tissue of lamina propria (Fig-1) The epithelium lining the true vocal cords appear to be similar to the one lining the entire ventricular cavity. Goblet cells seen occasionally in few foetal specimen.

Group-II (128-145mm C. R. L.) Eleven foetuses were dissected in this group. Well-formed epithelium lines the whole of the ventricular cavity which is of same type ie., ciliated pseudostratified columnar or respiratory type. The epithelium shows proximo- distal developmental gradient which means that the development of the epithelium in the proximal part of the ventricular cavity is advanced as compared to its distal end (Fig. 2). There is change of epithelium lining the true vocal

ORIGINAL ARTICLE

cords i. e. from ciliated pseudostratified columnar type to stratified squamous epithelium. Occasional goblet cells may be seen in few foetuses.

Group-III (146mm-168mm C. R. L.) Eight foetuses were dissected in this group. The ventricular cavity is uniformly lined by ciliated pseudostratified columnar epithelium except the true vocal folds and the dorsal surface of the epiglottis which shows stratified squamous epithelium on them (Fig. 3). Well ciliated pseudostratified columnar epithelium is observed on the laryngeal surface of the epiglottis in the ventricle. In the true vocal cords, diminished height of the stratified squamous epithelium is observed as a result of desquamation Goblet cells are more in number in the lower part of the laryngeal mucosa as compared to the previous group (Fig. 4).

Group-IV (170mm-220mm C. R. L.) Twelve foetuses were dissected in this group showing same features as the previous group as regards its lining epithelium. Stratified squamous epithelium of the true vocal folds appears flattened now due to desquamation. Goblet cells have increased in number and are more abundant in the lower part of the laryngeal ventricle and are well developed and well recognised by 21 st week of intrauterine life (Fig. 5).

DISCUSSION: In the present study, the emphasis is laid on the epithelium of developing human larynx. The present study shows pseudostratified ciliated columnar epithelium lining the ventricular cavity uniformly in all the four groups starting from 12 wks of foetus except the true vocal folds and anterior surface of epiglottis where the lining epithelium is of stratified squamous variety. This finding is similar to the finding of Hopp, ES (1955)⁽³⁾ and Meena Negi and Chandrama Anand (1987).⁽⁵⁾ This study shows flattening of stratified squamous epithelium of the vocal folds due to desquamation which is especially marked in group 3 and 4 foetuses. This observation is consistent with the observation made by Nakashima et al (1981)⁽⁶⁾ who observed diminished height of stratified squamous epithelial cells of true vocal folds.

These findings were further supported by similar findings of Hopp E. S. (1955)⁽³⁾ who observed same changes of foetus of 30wks intrauterine life and by those of Meena Negi and Chandrama Anand (1987)⁽⁵⁾ who observed them at the 17 wks of intrauterine life. The present study reveals respiratory type of epithelium that is ciliated pseudo stratified columnar type lining the laryngeal surface of epiglottis in the ventricular cavity. This is in accordance with the findings of Meena Negi and Chandrama Anand (1987)⁽⁵⁾ however Kooli. H. et al (2001)⁽⁷⁾ differed by observing that the laryngeal surface of the epiglottis has keratinizing stratified squamous epithelium in 60%, and respiratory type in 44%. In the present study the cilia are observed from 16 wks of gestation. This observation is contrary to the observation of Nakashima T. et al (1981)⁽⁶⁾ who reported the appearance of first cilia in larynx in 12wks fetus. Our observations do not coincide with the observations of Meena Negi and Chandrama Anand (1987)⁽⁵⁾ who observed cilia at 15wks of intrauterine life.

SUMMARY: The present study shows the development of the laryngeal epithelium in 40 human foetuses ranging from 75 mm CRL to 220 mm CRL. The entire laryngeal cavity is lined initially uniformly by the respiratory epithelium that is ciliated pseudostratified columnar type. Later on the epithelium over the true vocal cords and dorsal surface of the epiglottis changes into the stratified squamous type. Besides there is flattening of the epithelium over the true vocal cords as a result of desquamation.

REFERENCES:

1. Harrison, D. F. N.; (1995) (Donald Frederickn Norris): The anatomy and Physiology of the Mammalian Larynx/DFN Harrison. Published by the Press Syndicate of the University of Cambridge, the Pitt Building, Trumpington street, Cambridge CB2 IRP ISBN 0-521-45321-6 (hardback). Pg. 51.
2. Aronson, A. E; Bless, D. M; Petty B. E; (1928): In clinical voice disorders, 4th edition Published by Thieme Medical Publishers, United States of America pg 1-2 ISBN -978-1-58890-662-S.
3. Hopp, E. S., (1955): The development of the epithelium of the larynx; in "laryngoscope" Vol. 65, Pg 475-499.
4. Hamilton, W. J. and Mossman, H. W.; (1978): Hamiton, Boyd and Mossman; s Embryology, 4th edition. Published by Macmillan London. Pg 291-376.
5. Meena Negi and Chandrama Anand (1987): Histology and Histo-chemical studies on developing human larynx in J. Ant. Soc, India, Vol. 36 No. 1. Pg 1-7.
6. Nakashima, T., Makishima, K., Komiyama, S., Takeda, K. And Hiroto, I.: (1981): local Immune system in the developing Fetal Larynx in the Laryngoscope, 91: 1981. Pg. 398-407.
7. Kooli, H., Zhioua, A., Zekris, Najeh D., Jaafoura, M. H., and Ferjaoui, M., Histology of Larynx; Rev. Laryngol otol Rhinol (Bord) 2001; 122 (5). Pg. 291-294.

FIGURE 1: BASEMENT MEMBRANE (A), PSEUDOSTRATIFIED COLUMNAR EPITHELIUM (B), SHOWING CILIA (C) IN 115 mm C. R. LENGTH FETUS H & E X 400.

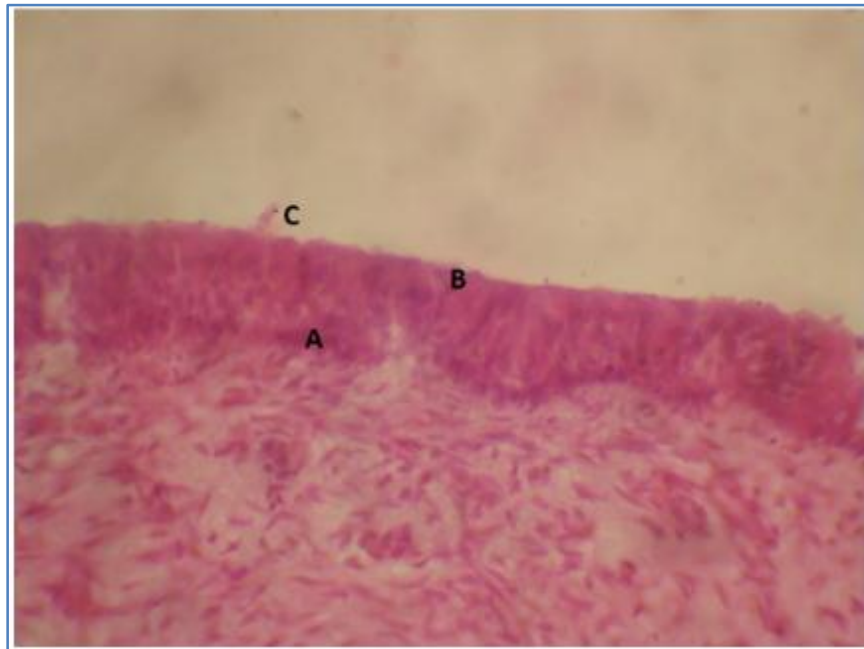


Fig. 1

ORIGINAL ARTICLE

FIGURE 2: PROXIMO – DISTAL (A & B) DIFFERENTIATION OF EPITHELIUM OF LARYNGEAL CAVITY (C) SEEN IN 135 mm C. R. LENGTH FETUS MASSON'S TRICHROME X100.

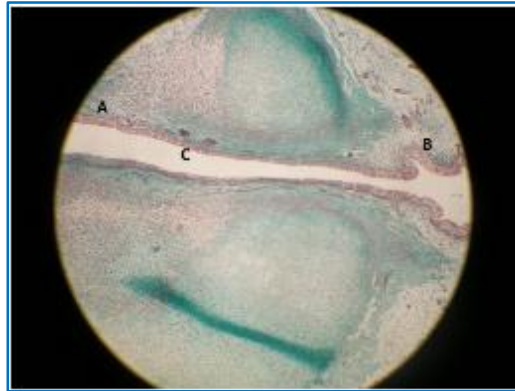


Fig. 2

FIGURE 3: TRUE VOCAL FOLD SHOWING STRATIFIED SQUAMOUS EPITHELIUM (A) LINING VENTRICULAR CAVITY (B) IN 158 mm C. R. LENGTH FETUS H&E X400.

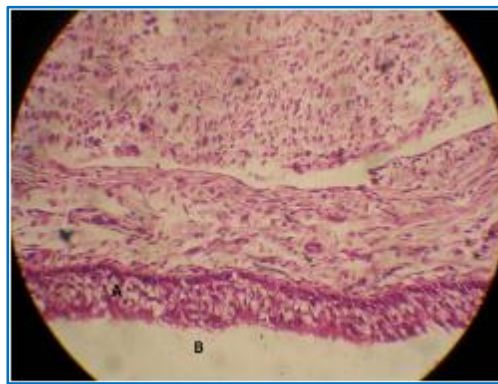


Fig. 3

FIGURE 4: WELL ESTABLISHED GOBLET CELL (B) IN CILIATED PSEUDOSTRATIFIED COLUMNAR EPITHELIUM (A) IN 168 mm C. R. LENGTH FETUS MASSON'S TRICHROME X400.

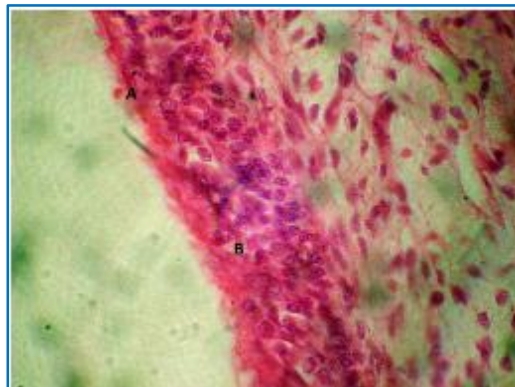


Fig. 4

ORIGINAL ARTICLE

FIGURE 5: NUMEROUS GOBLET CELLS (A) PRESENT IN EPITHELIAL LINING (B) OF LARYNGEAL CAVITY SEEN IN 172 mm C. R. LENGTH FETUS H&E X400.

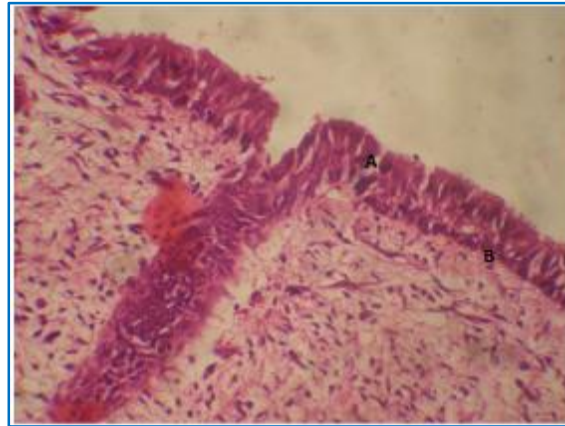


Fig. 5

Age of the Embryo /fetus	Crown –Rump length (C. R. L.) in mm
32 days	5 mm
33 -55 days	5mm +1mm per day
56 days onwards	Calculated age of fetus at 55 days +1. 5mm per day

TABLE 1

Group No.	Crown- Rump Length (C. R. L.) in mm	Number of Fetuses
I	75 to 125	09
II	128 to 145	11
III	146 to 168	08
IV	170 to 220	12

TABLE 2

AUTHORS:

1. Rachna Magotra
2. Sanjay Raina
3. Shyama K. Razdan

PARTICULARS OF CONTRIBUTORS:

1. Assistant Professor, Department of Anatomy, Government Medical College, Jammu.
2. Demonstrator, Department of Anatomy, Government Medical College, Jammu.

FINANCIAL OR OTHER

COMPETING INTERESTS: None

3. Ex HOD & Professor, Department of Anatomy, Government Medical College, Jammu.

NAME ADDRESS EMAIL ID OF THE CORRESPONDING AUTHOR:

Dr. Rachna Magotra,
242/7 Channi Himmat,
Jammu-180015.
E-mail: drmagotrarachna@gmail.com

Date of Submission: 12/03/2015.
Date of Peer Review: 13/03/2015.
Date of Acceptance: 23/03/2015.
Date of Publishing: 03/04/2015.