

MRI & MR SPECTROSCOPIC EVALUATION OF PROSTATIC CARCINOMA

Rupak Bhuyan¹, Prabhu B. J², Dibyajyoti Nath³, Siva Dutta⁴, Dinanath Chavan⁵, Malabika Goswami⁶, Alagiri K⁷

HOW TO CITE THIS ARTICLE:

Rupak Bhuyan, Prabhu B. J, Dibyajyoti Nath, Siva Dutta, Dinanath Chavan, Malabika Goswami, Alagiri K. "MRI & MR Spectroscopic Evaluation of Prostatic Carcinoma". Journal of Evolution of Medical and Dental Sciences 2015; Vol. 4, Issue 75, September 17; Page: 13025-13039, DOI: 10.14260/jemds/2015/1877

ABSTRACT: BACKGROUND: Prostate cancer is the most common malignancy among men more than fifty years of age (Cancer foundation of India). Imaging may help in clarifying several important issues in localized prostate cancer. MRI provides the best depiction of the contours of the prostate as well as its internal zonal anatomy. Recent evidence suggests that multi-parametric MRI could improve the accuracy of diagnostic assessment in prostate cancer. In addition, MRI also allows functional assessment with techniques such as diffusion-weighted MRI (DWI), MR spectroscopy (MRS), and dynamic contrast enhanced MRI (DCE-MRI). Strong opinions are held about the need for endorectal coil imaging. Endorectal coils provide large gains in signal with reductions in noise, most noticeably at 1.5 T; however, endorectal coils are uncomfortable and expensive. At 3 T, the need for endorectal coils has been debated. Clearly, the highest-quality MRI results from the combined use of endorectal coils and phased array body coils at 3 T. Prostate cancer is associated with proportionately lower levels of citrate and higher levels of choline and creatine than are seen in benign prostatic hyperplasia (BPH) or in normal prostate tissue. This difference can be detected by magnetic resonance spectroscopic imaging (MRSI). MRSI uses a strong magnetic field to obtain metabolic information (spectra) that identifies the relative concentrations of various metabolites in the cell cytoplasm and the extracellular space. This technique can identify metabolic differences in prostate tissue (BPH, prostate cancer, and normal prostate tissue). **AIM:** To evaluate the role of MRI and MR Spectroscopy in the diagnosis of prostatic carcinoma by pelvic phased array coil in the detection of prostatic carcinoma in men with Prostatomegaly & elevated PSA levels and establishing statistical analysis of the same. **METHOD:** A prospective study of minimum 50 consecutive cases with Prostatomegaly & raised PSA levels were carried out in the department of Radio-diagnosis for one calendar year, by MRI & MR spectroscopy & correlated histopathologically. MR Imaging and spectroscopy was performed with a 1.5-T Body MR imaging system. The pelvic phased-array coil was used for both excitation and signal reception. Imaging was done using standard protocols. Histological material was obtained either by a prostate biopsy/FNAC or from prostate chippings from a patient undergoing a TURP. **RESULTS:** With results of histopathologic examination as reference standard, T2-weighted images detected 32 patients who proved to have cancer on biopsy (Sensitivity 84.2%, Specificity 41.6%, and Accuracy 74%). MRSI detected 35 patients who proved to have cancer on biopsy (Sensitivity 87.5%, Specificity 60%, Accuracy 82%). MRSI was more sensitive and specific compared to T2-weighted images alone. **CONCLUSION:** MRI and MRSI of the prostate have high accuracy in detection of organ confined prostate cancer and differentiating it from benign hyperplastic prostatic tissue. MRSI is more sensitive and specific than MRI alone and combined imaging with MRI and MRSI is recommended. MRI and MRSI of prostate are feasible with pelvic phased array coil without endorectal coil, though more research would be necessary to prove this. In centres where imaging with endorectal coil is not feasible, imaging with pelvic phased array coil has comparable accuracy and may be used.

ORIGINAL ARTICLE

KEYWORDS: MRI, MR spectroscopy, Prostatic carcinoma.

INTRODUCTION: In India, prostate cancer has an incidence rate of 3.9 per 100,000 men and is responsible for 9% of cancer-related mortality.¹ Prostate cancer is the second most frequently diagnosed cancer and the sixth leading cause of cancer death in males worldwide; it is least common in South and East Asia, more common in Europe, and most common in the United States. According to the American Cancer Society, Prostate cancer is the most common malignancy in American men and the second leading cause of deaths from cancer, after lung cancer.² It is the only malignancy that is diagnosed with an apparently blind technique, i.e., transrectal sextant biopsy.¹ Prostate cancer is a common cause of morbidity and mortality in developed countries worldwide, particularly in Europe and North America. Prostate cancer differs from many other solid tumours in that the prevalence of latent disease – the number of men with undetected prostate cancer – far exceeds the number of men diagnosed with, or dying from, the disease.³

The widespread and repeated use of serum prostate-specific antigen (PSA) tests and extended-pattern transrectal ultrasound (TRUS)-guided biopsy has resulted in considerable stage migration. Few men now present with locoregional or metastatic disease identified by standard imaging (ie, bone scan or cross-sectional pelvic imaging with magnetic resonance imaging [MRI] or computerized tomography [CT]). Therefore, most clinicians have shifted from the use of imaging-based staging paradigms to a combination of clinical variables (Serum PSA, T stage, Gleason score, and extent of disease on biopsy) as a more efficient means to assess the likely extent of disease and determine the best initial treatment.⁴

However, despite the efficiency of clinical staging, it remains imperfect for precise local cancer staging and intraprostatic tumor localization, both of which play important roles in initial assessment, treatment, and, in many cases, follow-up. Under staging, which was reported to be in the range of 30% to cancer is often performed to exclude lymph node metastases in patients who are thought to be candidates for definitive local therapy. CT and MRI have similar sensitivities for this purpose. However, the incidence of lymph node metastases is currently low, and imaging is costly with limited sensitivity. A review of the literature that encompassed 15 series and 1354 patients, with an incidence of lymph node metastases of 22%, revealed a sensitivity of CT and MRI of approximately 36% and a specificity of 97%.⁵ Prostate Imaging Prostate Anatomy as Assessed by Endorectal MRI Endorectal MRI utilizes a magnetic coil placed in the rectum to better visualize the zonal anatomy of the prostate and better delineate tumor location, volume, and extent (stage). Patients are imaged in a whole-body scanner, using a pelvic phased array coil combined with an inflatable, balloon-covered, endorectal surface coil positioned in the rectum. Both T1- and T2-weighted spin-echo MRI images are required to evaluate prostate cancer. Thin-section axial images are used for tumor localization and assessment of the extent (stage) of the tumor. Specifically, the presence of extra capsular extension (ECE) and/or seminal vesicle invasion (SVI) is noted.

Coronal imaging may be helpful for tumor localization and in assessing SVI. Prostate zonal anatomy cannot be fully appreciated on T1-weighted images, as the gland is of intermediate signal intensity on such images. However, on T2-weighted images, zonal anatomy is evident: the peripheral zone is of high-signal intensity and is surrounded by a thin rim of low-signal intensity, representing the capsule of the gland. The central and transition zones are both of lower T2 signal intensity than the peripheral zone, likely due to its smooth muscle.⁴ However in present study MR imaging & MR spectroscopy of prostate was done by pelvic phased array coil in the detection of prostatic carcinoma.

ORIGINAL ARTICLE

With use of 3D MR spectroscopic imaging, significantly higher choline and significantly lower citrate levels were observed in regions of cancer compared in those areas of benign hypertrophy & normal prostate tissue. With increasing numbers of high-Tesla magnetic resonance imaging (MRI) equipment being installed in India, the radiologist needs to be cognizant about endorectal MRI and multiparametric imaging for prostate cancer.¹ Advanced prostate cancer may present with bone pain from metastases, anemia and renal failure, due to obstructive changes or rarely spinal cord compression. Early prostate cancer, however, is mainly asymptomatic with its detection often being the result of an elevated PSA test. PSA was first described in 1979⁵ and later proposed as a marker for prostate cancer⁶. It is a kallikrein-like serine protease and is produced almost exclusively by the epithelial cells of the prostate⁷. The below table⁸ shows age related PSA range.

<i>Age (years)</i>	<i>Normal PSA Range (ng/ml)</i>
40–49	0.0–2.5
50–59	0.0–3.5
60–65	0.0–4.5
70–79	0.0–6.5

Grading follows the Gleason system established in 1974⁹. The Gleason grade is achieved by looking at the histological architecture of the prostate. The two most commonly seen patterns are added together to give the patient a final Gleason score. A final score will therefore be between 2 and 10 with 2 being the least and 10 the most aggressive type of cancer. The table⁹ below represents the Gleason grading.

<i>Pattern</i>	<i>Tumor border</i>	<i>Stromal invasion</i>	<i>Gland</i>			<i>Cytoplasm</i>
			<i>Appearance</i>	<i>Size</i>	<i>Architecture</i>	
1	Circumscribed pushing	Minimal	Round, monotonous replicated	Medium regular	Closely packed rounded masses	Similar to benign epithelium
2	Early infiltration	Mild with definite separation of glands by stroma	Round, with some variation	Medium less regular	Loosely packed, rounded masses	Similar to benign epithelium
3	Infiltration	Marked	Angular with variation	Irregular	Variably packed, irregular masses	More basophilic than patterns 1 and 2
4	Ragged infiltration	Marked	Microacinar, papillary and cribriform	Irregular	Fused with chains and cords	Dark
5	Ragged infiltration	Marked	Difficult to identify lumina	Sheets of glands	Fused sheets and masses	Variable

Tumor node metastasis (TNM) classification

TNM Designation	Anatomic Findings
Extent of Primary Tumor (T)	
T1	CLINICALLY INAPPARENT LESION (BY PALPATION/IMAGING STUDIES)
T1a	Involvement of ≤5% of resected tissue
T1b	Involvement of >5% of resected tissue
T1c	Carcinoma present on needle biopsy (following elevated PSA)
T2	PALPABLE OR VISIBLE CANCER CONFINED TO PROSTATE
T2a	Involvement of ≤5% of one lobe
T2b	Involvement of >5% of one lobe, but unilateral
T2c	Involvement of both lobes
T3	LOCAL EXTRAPROSTATIC EXTENSION
T3a	Extracapsular extension
T3b	Seminal vesical invasion
T4	INVASION OF CONTIGUOUS ORGANS AND/OR SUPPORTING STRUCTURES INCLUDING BLADDER NECK, RECTUM, EXTERNAL SPHINCTER, LEVATOR MUSCLES, OR PELVIC FLOOR
Status of Regional Lymph Nodes (N)	
N0	NO REGIONAL NODAL METASTASES
N1	METASTASIS IN REGIONAL LYMPH NODES
Distant Metastases (M)	
M0	NO DISTANT METASTASES
M1	DISTANT METASTASES PRESENT
M1a	Metastases to distant lymph nodes
M1b	Bone metastases
M1c	Other distant sites
PSA, prostate-specific antigen.	

Histological material is obtained either by a prostate biopsy/FNAC or from prostate chippings from a patient undergoing a TURP. The standard approach to prostatic biopsy is to biopsy each sextant of the prostate and in addition to sampling the peripheral zone at apex laterally and the base¹⁰. Biopsy cores obtained in this way include the peripheral zone which is the most common location for early prostate cancer.

Risk factors³:

- Smoking.
- Alcohol.
- Physical activity.
- Obesity Diet and nutritional supplements.
- Medications.
- Genetics.

ORIGINAL ARTICLE

AIMS AND OBJECTIVES:

1. To evaluate the role of MRI and MR Spectroscopy in the diagnosis of prostatic carcinoma by pelvic phased array coil using histopathologic examination of prostatic biopsy specimen as reference standard.
2. To evaluate the accuracy of Magnetic Resonance Imaging and Magnetic Resonance Spectroscopic imaging by pelvic phased array coil in the detection of prostatic carcinoma in men with elevated PSA levels in comparison to previous studies on endorectal coil.
3. To establish a statistical analysis of the cases. Descriptive statistics will be including sensitivity, specificity and their corresponding positive and negative predictive values for each test.

MATERIALS & METHODS:

SUBJECTS AND METHODS: This study will be conduct in department of Radio-diagnosis for one calendar year.

SOURCE OF DATA: A prospective study of minimum 50 consecutive cases with Prostatomegaly & raised PSA levels who met selection criteria were carried out in the department of Radio-diagnosis for one calendar year, by MRI & MR spectroscopy & correlated histopathologically during 2014-15.

SAMPLE SIZE: 50 consecutive cases with Prostatomegaly & raised PSA levels who met selection criteria.

DURATION: July 2014 to June 2015 for a period of 1yr.

INCLUSION CRITERIA:

1. Patient aged between 50 to 70 years presenting with Prostatomegaly & raised PSA levels.
2. All patient who have PSA level of > 4 and <10ng/ml.
3. All patients already diagnosed with prostatic cancer.
4. All patients who have an incidental finding of prostatic carcinoma or suspicion of prostatic carcinoma on imaging will be included.

EXCLUSION CRITERIA:

1. Patient aged less than 50 year.
2. Patient aged more than 70 year.

SETTING:

1. Informed consent was taken from the patients & care taker.
2. Clearance by the ethical committee of SMCH was taken.

MRI EVALUATION:

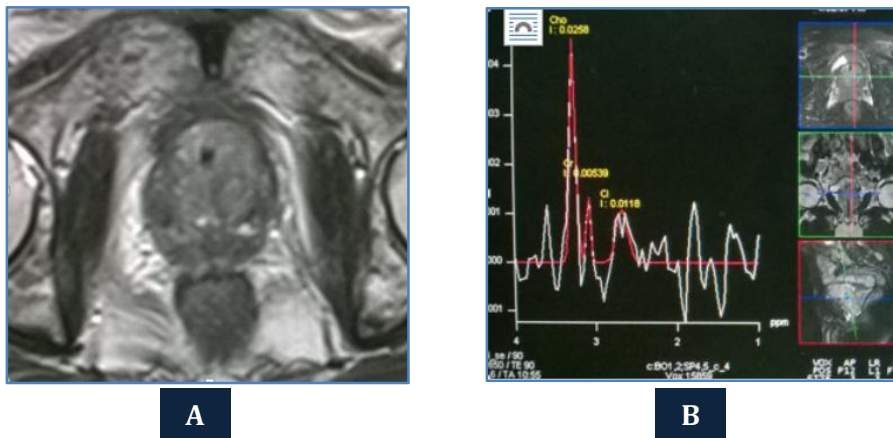
- MRI evaluation was carried out in a SIEMENS TIM AVANTO 1.5T SCANNER.
- MR Imaging and spectroscopy was performed with a 1.5-T Body MR imaging system. The pelvic phased-array coil was used for both excitation and signal reception.
- After acquisition of a sagittal T2-weighted fast spin-echo localizer image, transverse high resolution T2-weighted fast spin-echo images was obtained from below the apex of the prostate to above the seminal vesicles with the following parameters: repetition time msec/echo time msec (effective) of 4,000/100, 3-mm section thickness, no intersection gap, 14-

ORIGINAL ARTICLE

cm field of view, 256x192 matrix. Transverse T1-weighted images (500–700/12, 4-mm-thick sections, 1-mm section gap, 14-cm field of view, 256x192 matrix) was obtained from below the apex of the prostate to the level of the aortic bifurcation to assess pelvic lymphadenopathy. T1 and high resolution T2-weighted sagittal and T2-weighted coronal images of the prostate was also obtained with similar parameters.

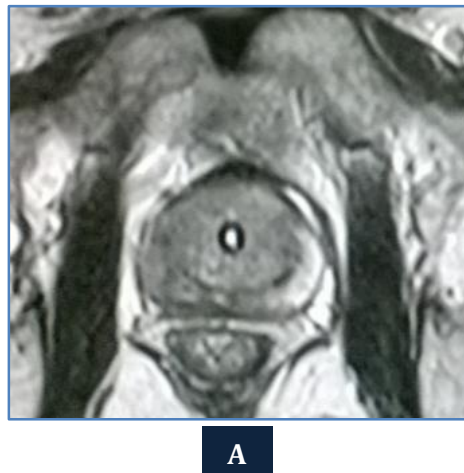THREE-DIMENSIONAL MR SPECTROSCOPIC IMAGING PROTOCOL: From the high spatial-resolution transverse T2-weighted images, a spectroscopic volume was selected with the point-resolved spectroscopic (PRESS) technique to encompass as much of the prostate as possible, while excluding peri-prostatic fat. The echo delay of the point-resolved spectroscopic sequence was optimized for the quantitative detection of both citrate and choline. The position of the selected volume and the accuracy of localization was evaluated by means of MR imaging.

Case 1.

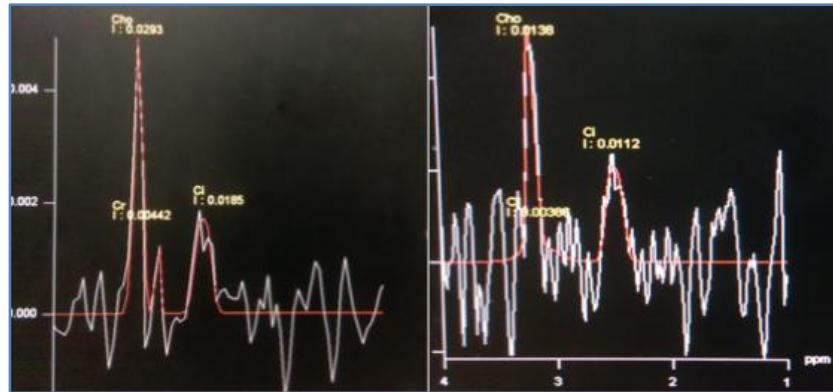


- A) Axial high resolution T2W image showing decreased signal intensity in the posterior peripheral zone
 B) Spectroscopic tracing through one of the voxels displaying elevated Choline and low Citrate-Creatine.

Case 2:



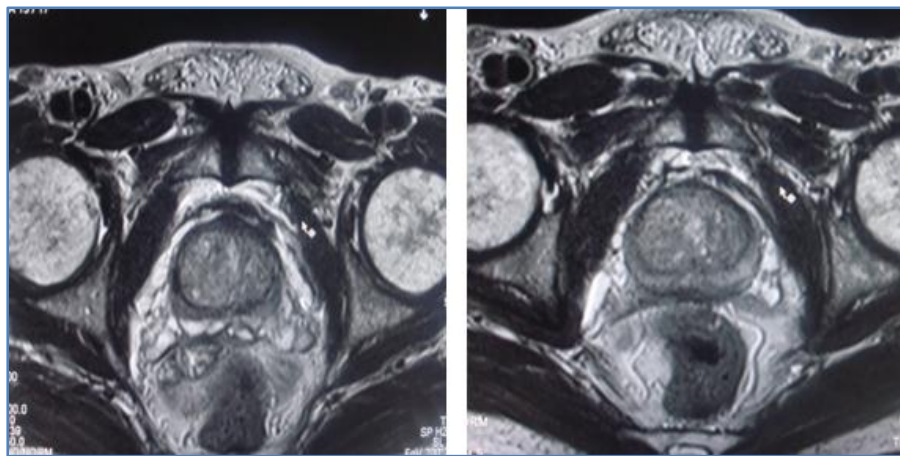
ORIGINAL ARTICLE



B & C

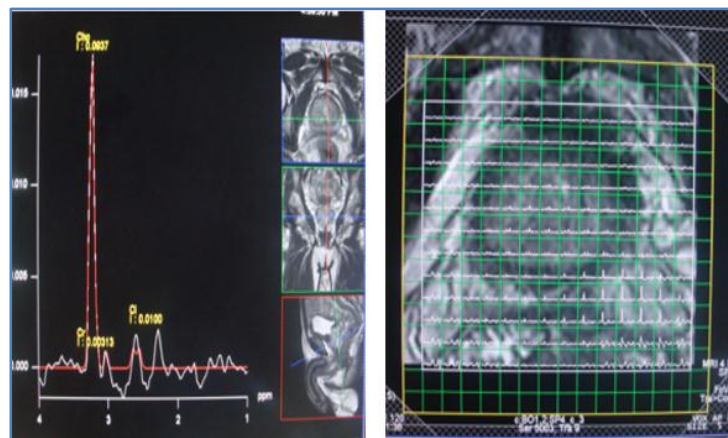
A) Axial high resolution T2W image showing diffusely decreased signal intensity in the posterior and right lateral peripheral zone. Spectroscopic tracing [B, C] through two voxels displaying elevated Choline and depleted Citrate-Creatine.

Case 3:



A

B



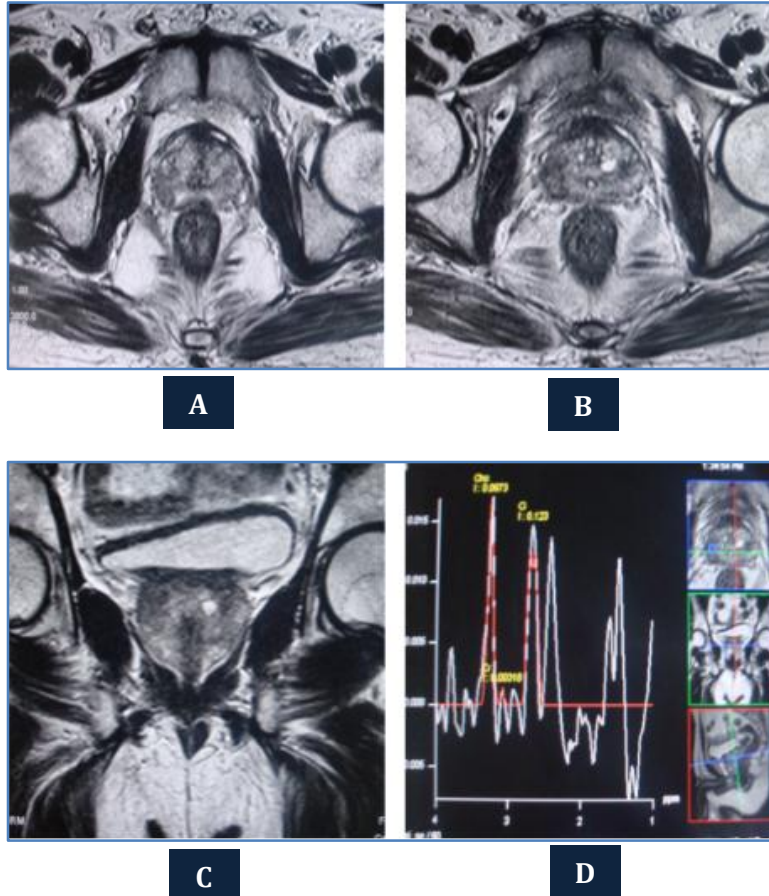
C

D

ORIGINAL ARTICLE

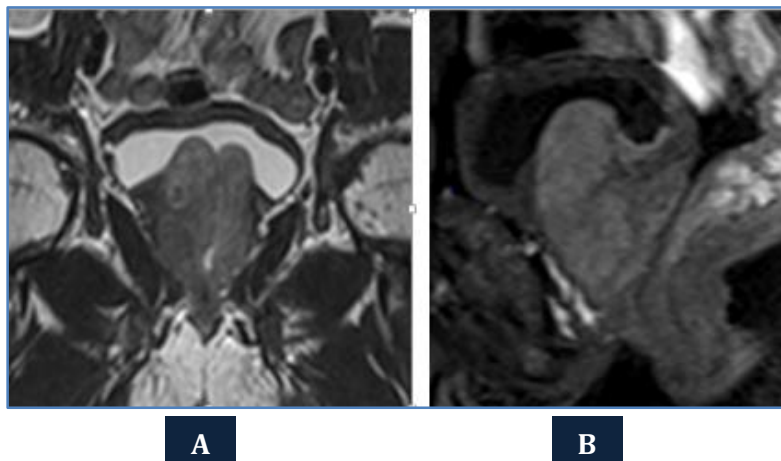
Axial high resolution T2w images [A, B] showing diffuse decreased signal intensity in peripheral zone and hyperplastic central gland. Spectroscopic tracing [c] through one of the voxels displaying elevated Choline and depleted Citrate-Creatine. Placement of Spectroscopic volume.

Case 4:

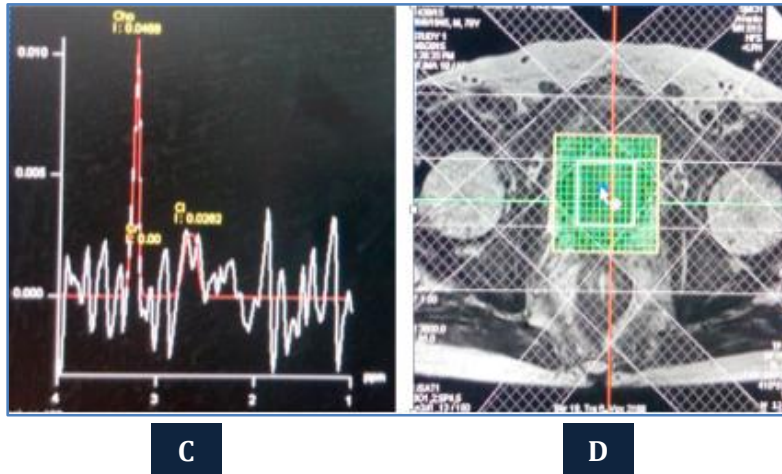


Axial high resolution T2w images [A, B] showing area of decreased signal intensity in left posterolateral peripheral zone with extra capsular extension. Spectroscopic tracing [C, D] through two voxels displaying elevated Choline and depleted Citrate-Creatine.

Case 5:



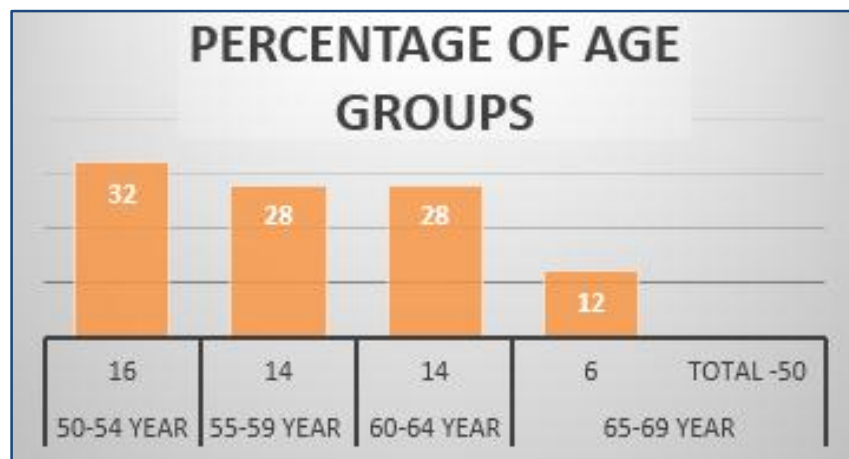
ORIGINAL ARTICLE



Axial high resolution T2w images [A, B] showing area of decreased signal intensity in Right posterolateral peripheral zone with extracapsular extension. Spectroscopic tracing [C, D] through two voxels displaying elevated Choline and depleted Citrate-Creatine.

Analysis:

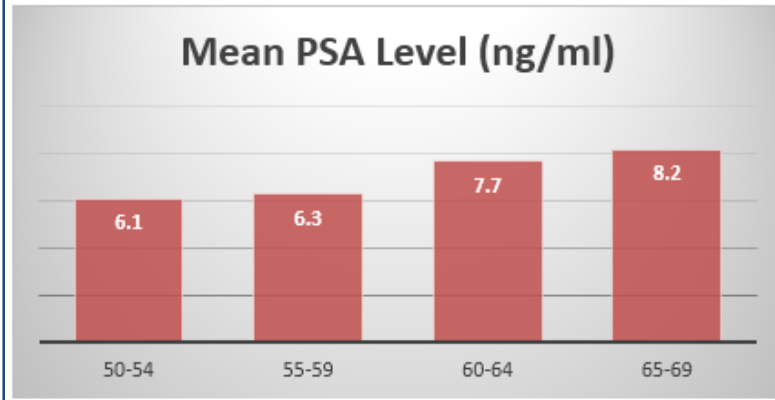
1. Age of Patient:		
AGE (yr)	No	Percentage (%)
50-54	16	32
55-59	14	28
60-64	14	28
65-69	6	12
	Total -50	



ORIGINAL ARTICLE

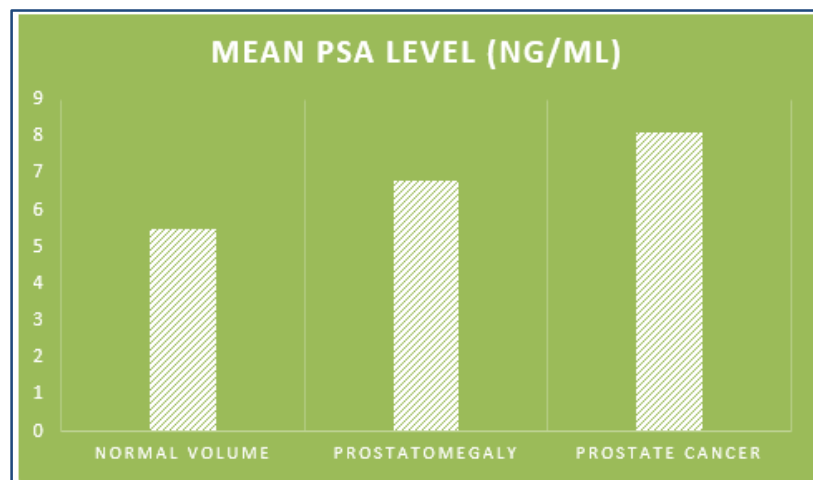
2. PSA level distribution among age groups:

Age (Yr)	Mean PSA Level (ng/ml)
50-54	6.1
55-59	6.3
60-64	7.7
65-69	8.2



3. PSA distribution with relation to prostate size:

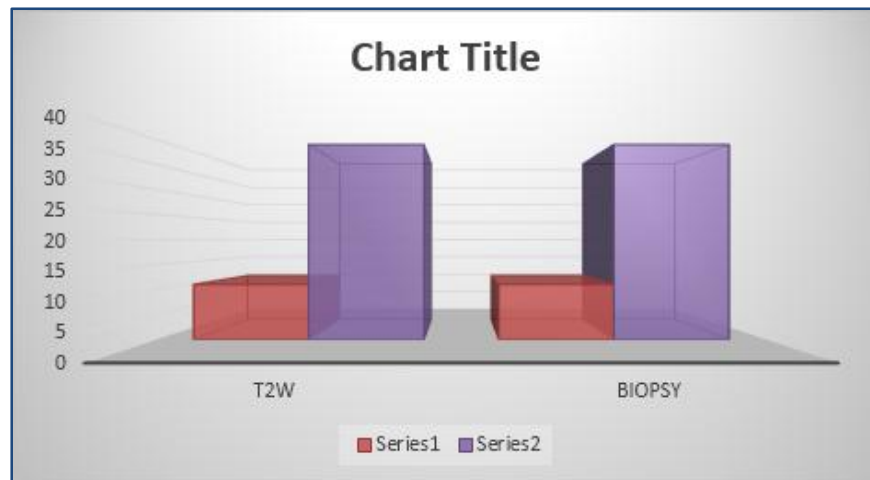
Prostate	Mean PSA level (ng/ml)
Normal volume	5.5
Prostatomegaly	6.8
Prostate Cancer	8.1



ORIGINAL ARTICLE

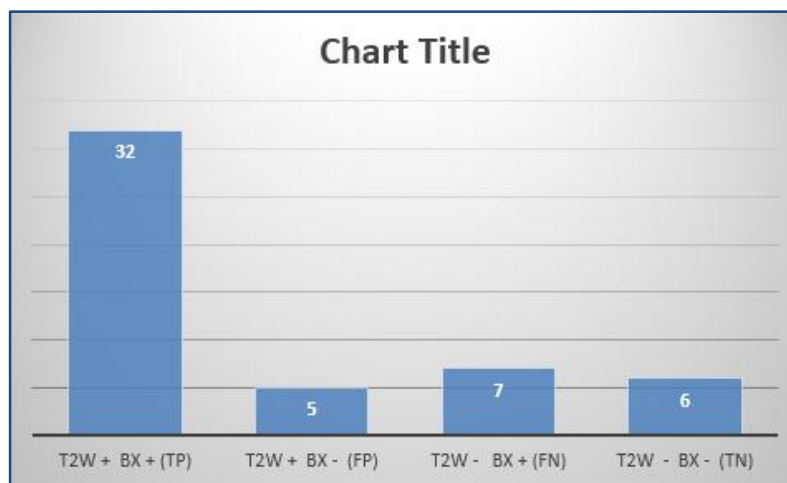
4. Comparison between T2 weighted imaging & biopsy results.

	T2WI	Biopsy
BPH	11	11
Cancer	39	39
Total	50	50



T2w + <u>Bx</u> + (TP)	32
T2w + <u>Bx</u> - (FP)	5
T2w - <u>Bx</u> + (FN)	7
T2w - <u>Bx</u> - (TN)	6

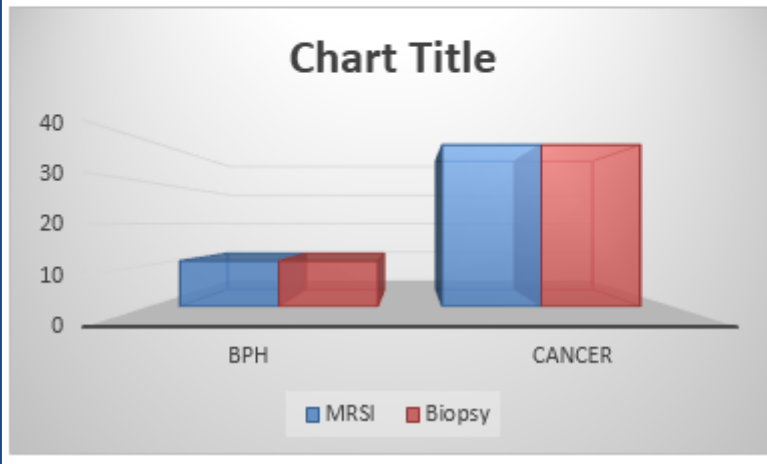
[TP – TRUE POSITIVE, FP – FALSE POSITIVE, FN – FALSE NEGATIVE, TN – TRUE NEGATIVE, Bx – BIOPSY]



ORIGINAL ARTICLE

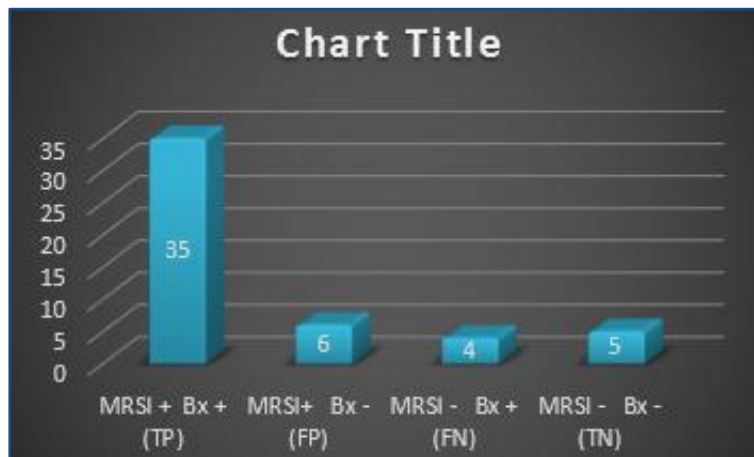5. Comparison between MR spectroscopy & biopsy results.

	MRSI	Biopsy
BPH	11	11
Cancer	39	39
Total	50	50



MRSI + <u>Bx</u> + (TP)	35
MRSI+ <u>Bx</u> - (FP)	6
MRSI - <u>Bx</u> + (FN)	4
MRSI - <u>Bx</u> - (TN)	5

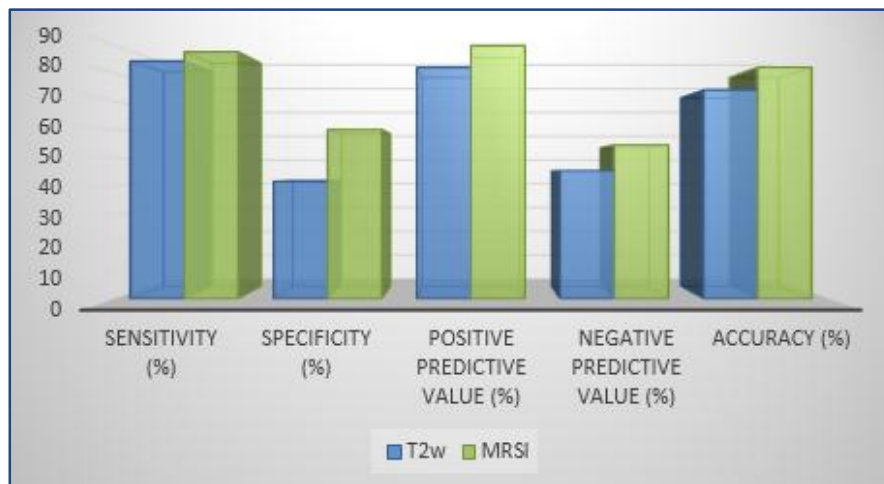
[TP - TRUE POSITIVE, FP - FALSE POSITIVE, FN - FALSE NEGATIVE, TN - TRUE NEGATIVE, Bx - BIOPSY]



ORIGINAL ARTICLE

	T2w	MRSI
True Positive	32	35
True Negative	5	6
False Positive	7	4
False Negative	6	5
Total	50	50

	T2w	MRSI
Sensitivity (%)	84.2	87.5
Specificity (%)	41.6	60
Positive Predictive Value (%)	82	89.7
Negative Predictive Value (%)	45.4	54.5
Accuracy (%)	74	82



RESULT AND OBSERVATION: With results of histopathologic examination as reference standard, T2-weighted images detected 32 patients who proved to have cancer on biopsy (Sensitivity 84.2%, Specificity 41.6%, and Accuracy 74%). MRSI detected 35 patients who proved have cancer on biopsy (Sensitivity 87.5%, Specificity 60%, Accuracy 82%). MRSI was more sensitive and specific compared to T2-weighted images alone.

DISCUSSION:

- Among study population of 50 patients, 32% were in age group of 50 to 55 years, 28% were in age 55 to 59, 28% were in age group of 60 to 64 years, years and 12% between 65 to 70 years. Prostate cancer was most common in age group of 60 to 64 years. Patients with prostate cancer and prostatomegaly had higher PSA levels. PSA level was higher in patients with prostate cancer than BPH.

ORIGINAL ARTICLE

- Sensitivity, specificity and accuracy of T2-weighted images and MRSI were 84.2%, 41.6%, 74% and 87.5%, 60%, 82% respectively. MRSI demonstrated higher sensitivity, specificity and accuracy compared to T2-weighted images.
- False positive instances on T2-weighted images may be attributed to prostatitis, low Gleason grade and biopsy not being taken from the site of lesion. False positive results on MRSI may have occurred due to prostatitis and biopsy not being targeted at the lesion. Possible causes of false negatives on T2 may be due to small size of the lesion and low signal to noise ratio and that on MRSI may be attributed to low Gleason grade and low signal to noise ratio.

CONCLUSION:

- Our study has demonstrated that MRI and MRSI of the prostate have high accuracy in detection of organ confined prostate cancer and differentiating it from benign hyperplastic prostatic tissue. MRSI is more sensitive and specific than MRI alone and combined imaging with MRI and MRSI is recommended.
- Demonstration of cancer to the confines of prostatic capsule is one of the most important roles of imaging in prostatic cancer and determination of a management strategy. MRI has significant accuracy in detection of organ confined disease and inclusion of MRI is recommended in the evaluation of suspected organ confined prostate cancer.
- We may also state that MRI and MRSI of prostate are feasible with pelvic phased array coil without endorectal coil, though more research would be necessary to prove this.
- Many studies have proven the superiority of imaging with endorectal coil over pelvic phased array coil and have strongly recommended use of the former for optimal imaging of prostate. We may suggest that, in centres where imaging with endorectal coil is not feasible, imaging with pelvic phased array coil has comparable accuracy and may be used.

BIBLIOGRAPHY:

1. Hedgire SS, Oei TN, Mcdermott S, Cao K, Patel ZM, Harisinghani MG. Multiparametric magnetic resonance imaging of prostate cancer. *Indian J Radiol Imaging* 2012;22: 160-9.
2. Mahyar Ghafoori*, Manijeh Alavi, Mounes Aliyari Ghasabeh. MRI in Prostate Cancer. DOI: 10.5812/ Iran Red Cres Med J.16620.
3. Gerald Andriole and Manfred Wirth. Prostate Cancer. An International Consultation on Prostate Cancer Berlin, Germany, October 16-20, 2011. Published by the Société Internationale d'Urologie (SIU).
4. Peter R. Carroll, MD, Fergus V. Coakley, MD, John Kurhanewicz, PhD. Magnetic Resonance Imaging and Spectroscopy of Prostate Cancer. *Rev Urol*. 2006;8(suppl 1): S4-S10
5. Wang MC, Valenzuela LA, Murphy GP et al. Purification of a human prostate specific antigen. *Invest Urol* 1979; 17: 159 – 63.
6. Stamey TA , Yang N , Hay AR et al. Prostate-specific antigen as a serum marker for adenocarcinoma of the prostate. *N Engl J Med* 1987; 317: 909 – 16.
7. Lilja H, Christensson A, Dahlen U et al. Prostate-specific antigen in serum occurs predominantly in complex with α 1 antichymotrypsin. *Clin Chem* 1991; 37 1618 – 25.

ORIGINAL ARTICLE

8. Oesterling JE, Jacobsen SJ, Chute CG et al. Serum prostate specific antigen in a community-based population of healthy men. Establishment of age-specific reference ranges. JAMA 1993; 270: 860 – 4.
9. Gleason DF, Mellinger GT. Prediction of prognosis for prostatic adenocarcinoma by combined histological grading and clinical staging. J Urol 1974; 111: 58 – 64.
10. Aus G, Bergdahl S, Hugosson J et al. Outcome of laterally directed sextant biopsies of the prostate in screened males aged 50–66 years. Implications for sampling order Eur Urol 2001; 139: 655 – 60.

AUTHORS:

1. Rupak Bhuyan
2. Prabhu B. J.
3. Dibyajyoti Nath
4. Siva Dutta
5. Dinanath Chavan
6. Malabika Goswami
7. Alagiri K.

PARTICULARS OF CONTRIBUTORS:

1. Assistant Professor, Department of Radio-diagnosis, SMC & H, Silchar.
2. Post Graduate Trainee, Department of Radio-diagnosis, SMC & H, Silchar.
3. Associate Professor, Department of Radio-diagnosis, SMC & H, Silchar.
4. Post Graduate Trainee, Department of Radio-diagnosis, SMC & H, Silchar

FINANCIAL OR OTHER

COMPETING INTERESTS: None

5. Post Graduate Trainee, Department of Radio-diagnosis, SMC & H, Silchar.
6. Post Graduate Trainee, Department of Radio-diagnosis, SMC & H, Silchar.
7. Post Graduate Trainee, Department of Radio-diagnosis, SMC & H, Silchar

NAME ADDRESS EMAIL ID OF THE CORRESPONDING AUTHOR:

Dr. Rupak Bhuyan,
Assistant Professor,
Department of Radio-diagnosis,
SMC & H, Silchar.
E-mail: bhuyan.rupak@gmail.com

Date of Submission: 10/09/2015.
Date of Peer Review: 11/09/2015.
Date of Acceptance: 14/09/2015.
Date of Publishing: 15/09/2015.