

**COMPARATIVE STUDY OF FOREARM FRACTURES TREATED WITH LOCKING COMPRESSION PLATE LIMITED CONTACT DYNAMIC COMPRESSION PLATE**B. Jayachandra Reddy<sup>1</sup>, L. Abhishek<sup>2</sup>, R. Kathyayini<sup>3</sup>**HOW TO CITE THIS ARTICLE:**

B. Jayachandra Reddy, L. Abhishek, R. Kathyayini. "Comparative Study of Forearm Fractures Treated with Locking Compression Plate Limited Contact Dynamic Compression Plate". Journal of Evolution of Medical and Dental Sciences 2015; Vol. 4, Issue 12, February 09; Page: 2001-2010, DOI: 10.14260/jemds/2015/289

**ABSTRACT: OBJECTIVES:** This study has been carried out to compare the functional outcome of fracture fixation in diaphyseal forearm fractures by using Locking Compression Plate versus Limited contact dynamic compression Plate. To study the difference in the duration of union & complications with LCP & LC-DCP. **METHODOLOGY:** It is a prospective randomised comparative study which was carried out from December 2012 to December 2014 in our Institution. In Group I, 20 patients were subjected to open reduction and internal fixation with 3.5 mm stainless steel LCP and locking head/nonlocking screws. In Group II, 20 patients were managed by 3.5mm LCDCP and non-locking screws. Clinical assessments regarding pain and function, radiological assessments were undertaken at the final follow-up. **RESULTS-** The time required for LCP fixation (mean 93.5 min, range 75-120 min) was found to be more than that required for LC-DCP (mean 81.94 min, range 60-110 min). But this time difference was not significant ( $P=0.07$ , unpaired t test). The mean time of union for the forearm fixed with LCP was found to be 18 weeks (range 14-26 weeks) in comparison to 16 weeks (range 10-22 weeks) for the LC-DCP group. **CONCLUSION-** LC plating is an effective treatment option for fractures shaft of forearm. The present study could not prove the superiority of LCP over LC-DCP. It is the proper application of the principles of plating and not the type of plate which decides the outcome. Further long-term multicentric study is required to prove behaviors of the implant.

**KEYWORDS:** LCP, LC-DCP, PC-FIX, biologic plating

**INTRODUCTION:** Forearm bones fractures are commonly encountered in today's industrial era. The encouraging results that have been reported with recent advances in internal fixation techniques and instrumentation have led to an expansion of surgical indications for such fractures & implant of choice.

Open reduction and internal fixation with plating is generally accepted as the best method of treatment for displaced diaphyseal fractures of forearm. The biologic plating entails a sufficiently stable fixation of the bone fragments, allowing early mobilization without major disturbance of the vascularization.

The limited contact dynamic compression plates (LC-DCP) was said to reduce the bone-plate contact by approximately 50% to minimize the disruption of periosteal blood vessels beneath the plate. It still relied on the plate-bone interface for stability and the problem of confluent contact areas was not completely resolved.

Locking compression plate (LCP) was devised by combining the features of a LC-DCP and a Point Contact Fixator (PC-Fix). Theoretically, this allows for:

## ORIGINAL ARTICLE

- More rapid bone healing.
- Besides decreasing infection, bone resorption, delayed union/non-union and secondary loss of reduction.

But reports on the results of clinical application of LCP are few, especially on its efficacy, or superiority over other plates in the treatment of diaphyseal fractures of forearm.

### OBJECTIVES:

- This study has been carried out to compare the functional outcome of fracture fixation in diaphyseal forearm fractures by using Locking Compression Plate versus Limited contact dynamic compression Plate.
- To study the difference in the duration of union & complications with LCP & LC-DCP.

**METHODOLOGY:** It is a prospective randomized comparative study which was carried out from December 2012 to December 2014 in our Institution.

In Group I, 20 patients were subjected to open reduction and internal fixation with 3.5 mm stainless steel LCP and locking head/non locking screws.

In Group II, 20 patients were managed by 3.5mm LCDCP and non-locking screws. Clinical assessments regarding pain and function, radiological assessments were undertaken at the final follow-up.

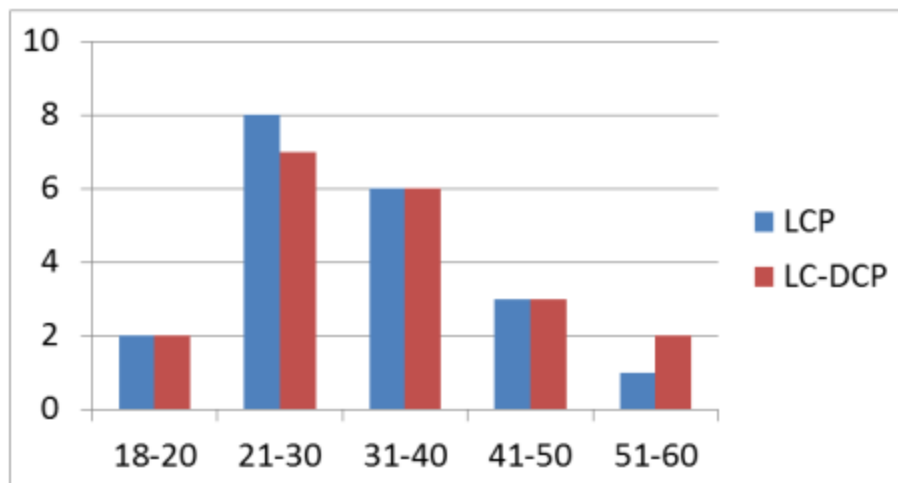
### INCLUSION CRITERIA:

- Patients with diaphyseal fractures of both bones of forearm.
- Patients above the age of 18 years.

### EXCLUSION CRITERIA:

- Compound fractures of forearm bones.
- Segmental fractures of forearm bones.

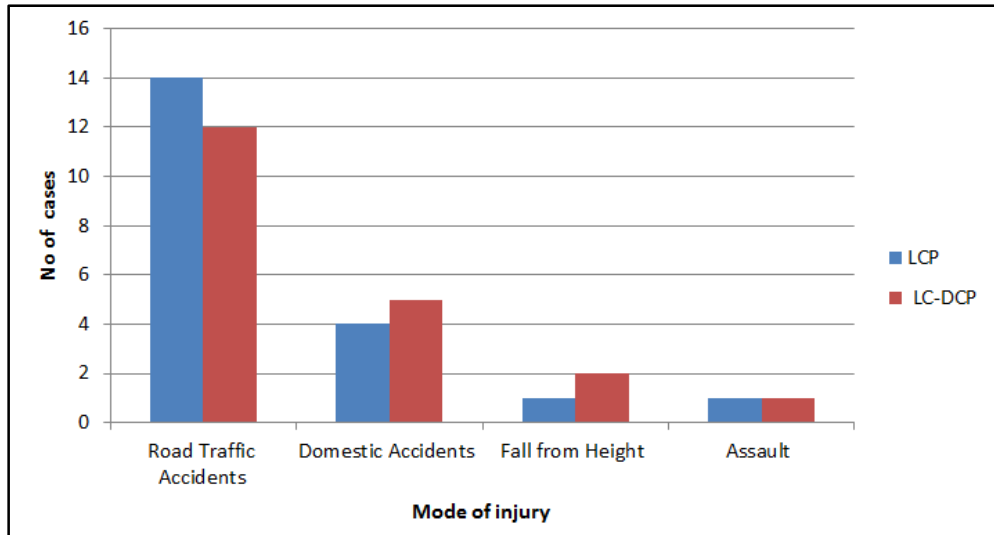
### AGE DISTRIBUTION:



Graph 1

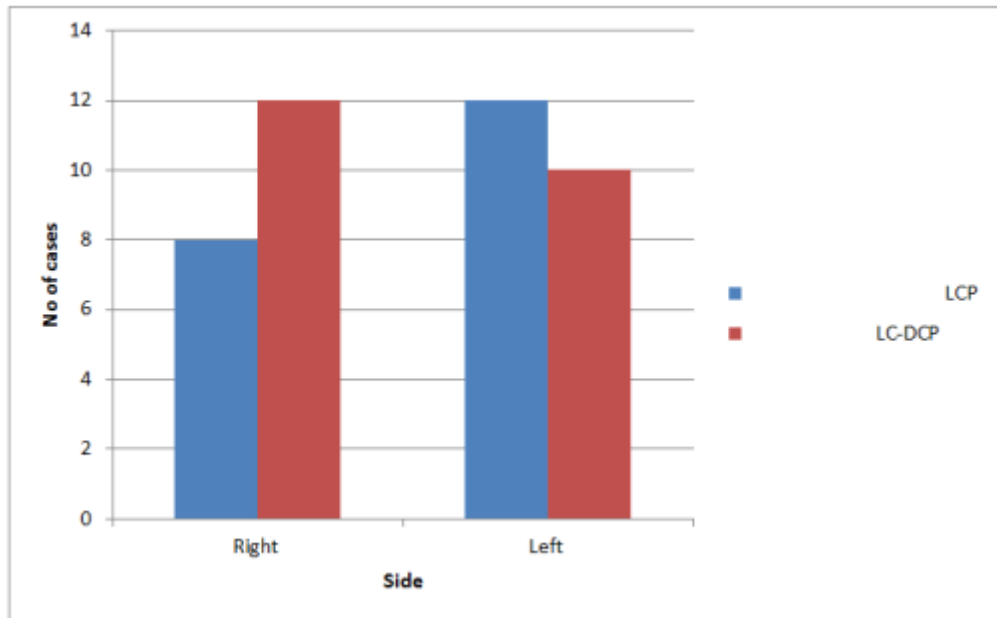
# ORIGINAL ARTICLE

## MODE OF INJURY:



Graph 2

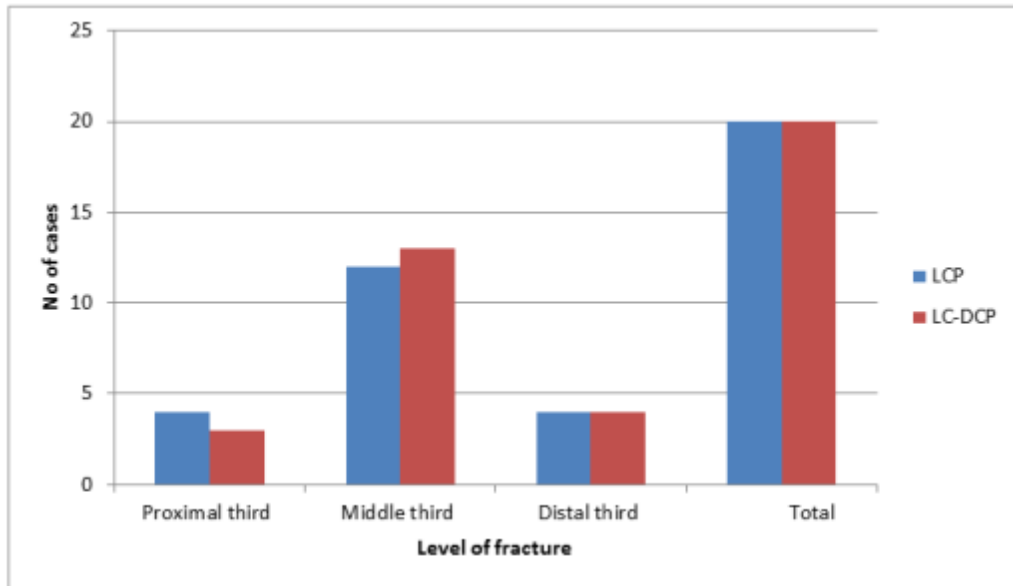
## SIDE OF INJURY:



Graph 3

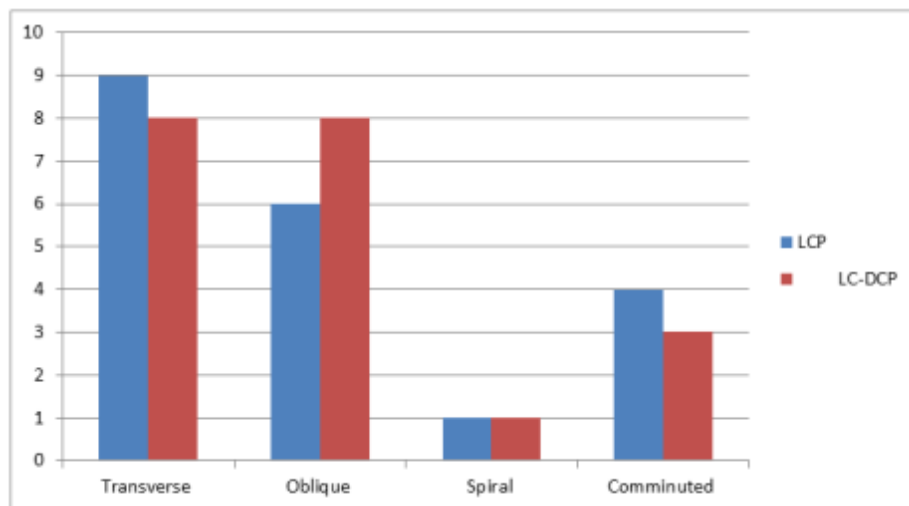
## ORIGINAL ARTICLE

### LEVEL OF FRACTURE:



Graph 4

### TYPE OF FRACTURE:



Graph 5

**OPERATIVE TECHNIQUE:** In LCP fixation for axial compression, the plate was first fixed with a conventional screw after reducing the fracture, followed by another conventional screw in the opposite fragment. Locking head screws were used for the rest of the screw holes. For the bridging technique, only locking head screws were used. We uniformly used bicortical locking head screws.

## ORIGINAL ARTICLE

Patients were followed up at 1, 2, 3, 6 months and 1 year, with radiographs being taken at regular intervals.

### The results were evaluated on the basis of:

- Fracture union,
- Range of movements &
- Subjective complaints.

According to ANDERSON ET AL SERIES GRADING.

### ANDERSON ET AL SERIES GRADING:

#### EXCELLENT:

- Solid union - anatomic reconstitution,
- Less than 10% loss of range of motion,
- No significant subjective complaints.

#### GOOD:

- Solid union - anatomic reconstitution.
- 10-20% loss of range of motion.
- Minimal subjective complaints.

#### POOR:

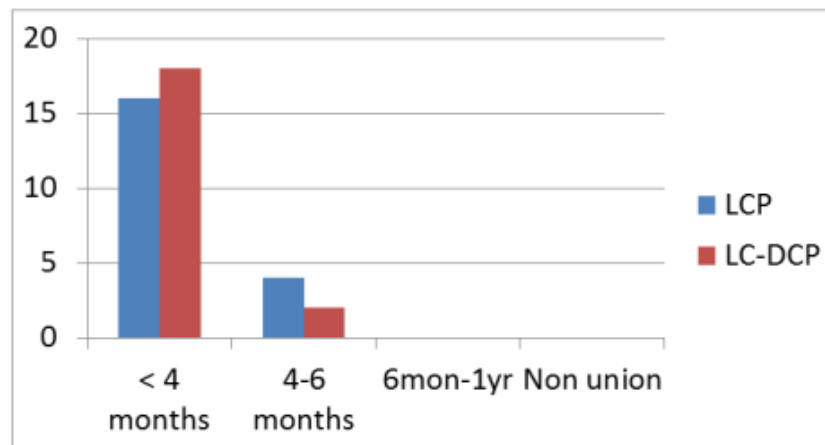
- Non anatomic results or non-union.
- Greater than 20 degree loss of range of motion.
- Moderate subjective complaints.

### RESULTS:

#### DURATION OF SURGERY:

- The time required for LCP fixation (mean 93.5 min, range 75-120 min) was found to be more than that required for LC-DCP (mean 81.94 min, range 60-110 min). But this time difference was not significant ( $P=0.07$ , unpaired t test).

#### DURATION OF UNION:



Graph 6

## ORIGINAL ARTICLE

The mean time of union for the forearm fixed with LCP was found to be 18 weeks (range 14-26 weeks) in comparison to 16 weeks (range 10-22 weeks) for the LC-DCP group.

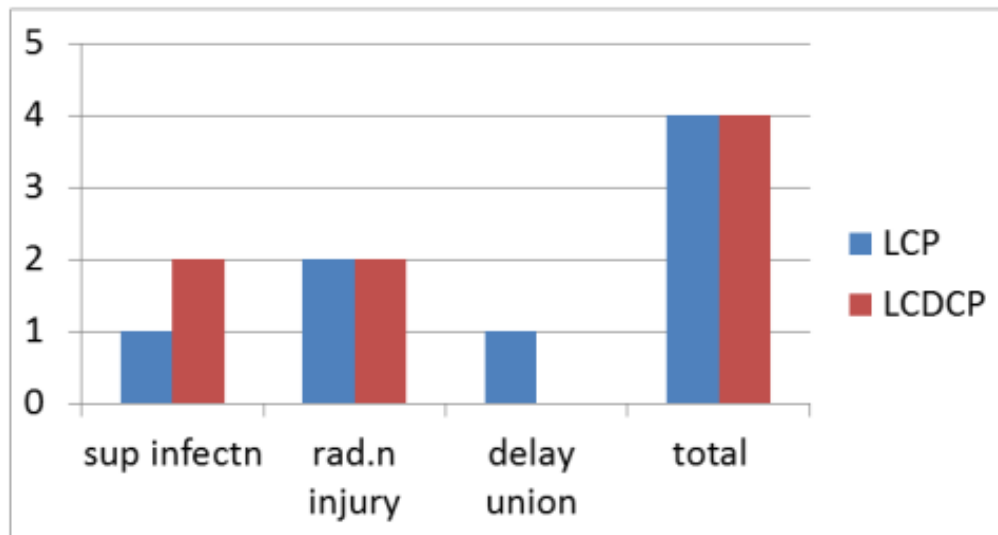
### ANDERSON ET AL SERIES GRADING:

### FUNCTIONAL ASSESSMENT:

Result	LCP	LC-DCP
Excellent	18	17
Good	2	3
Poor	0	0
<b>Total</b>	<b>20</b>	<b>20</b>

Table 1

### COMPLICATIONS:

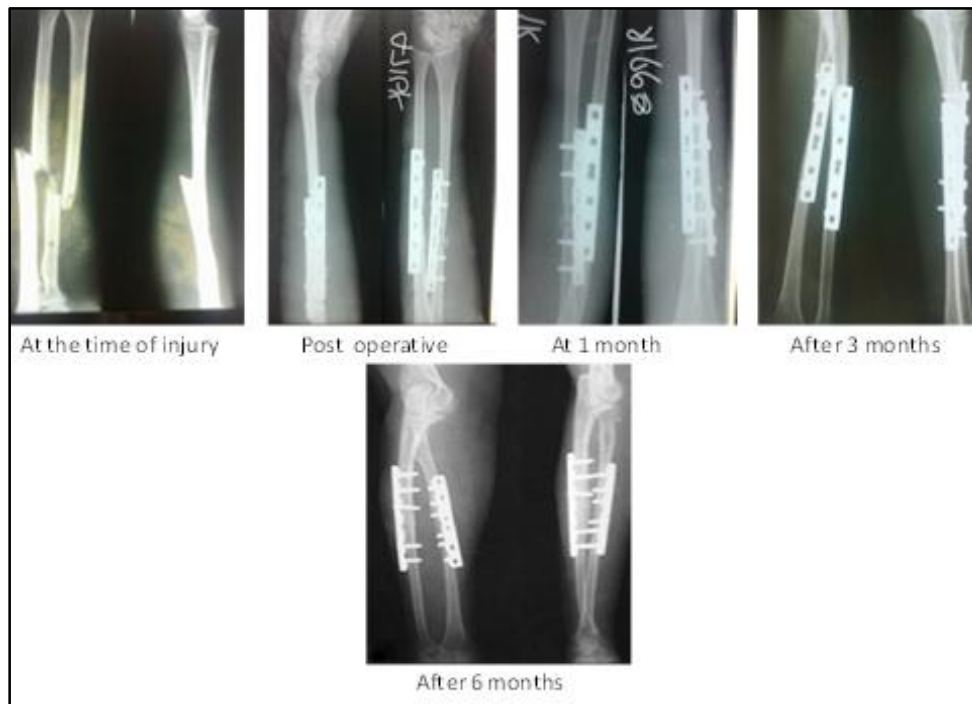
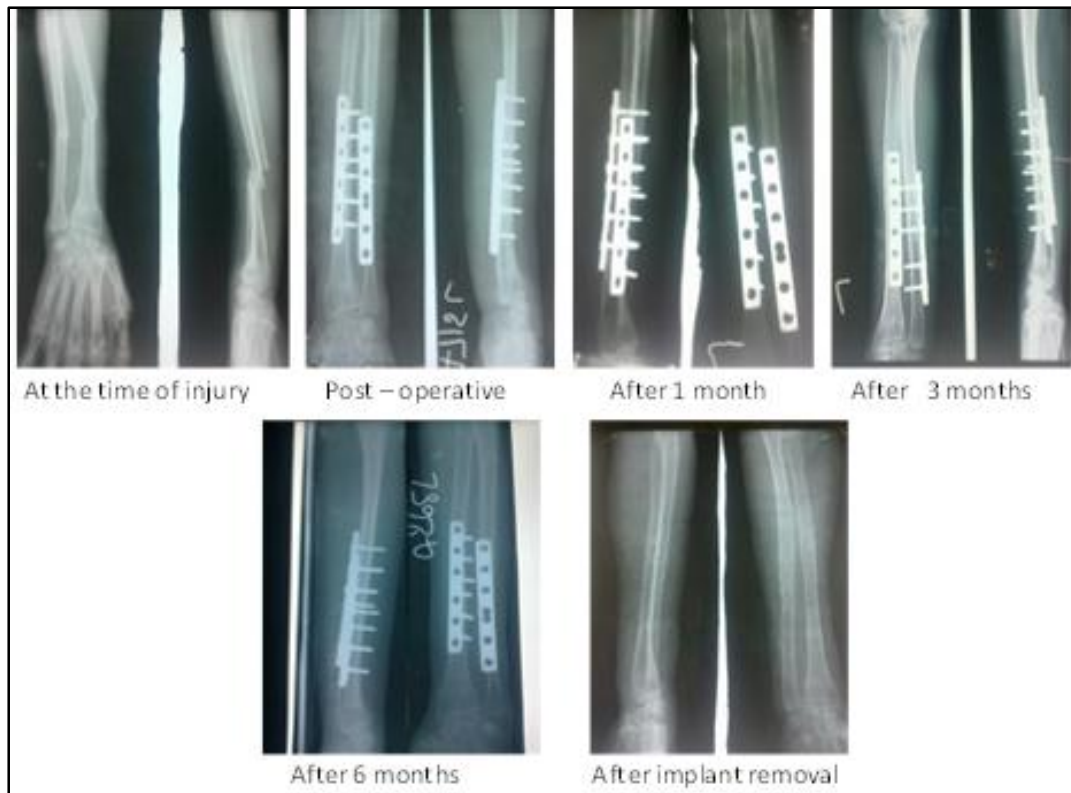
Graph 7

# ORIGINAL ARTICLE

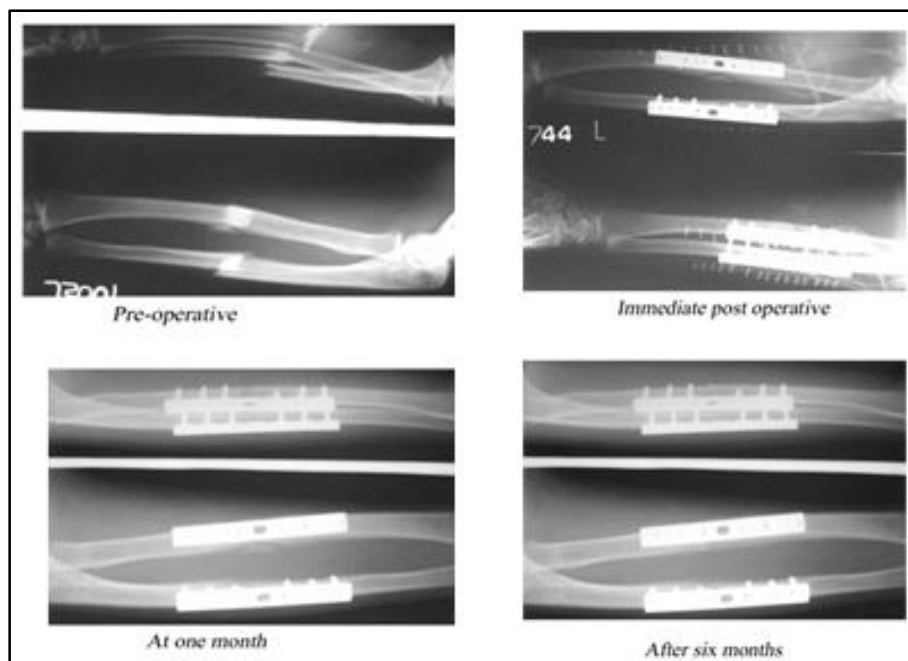
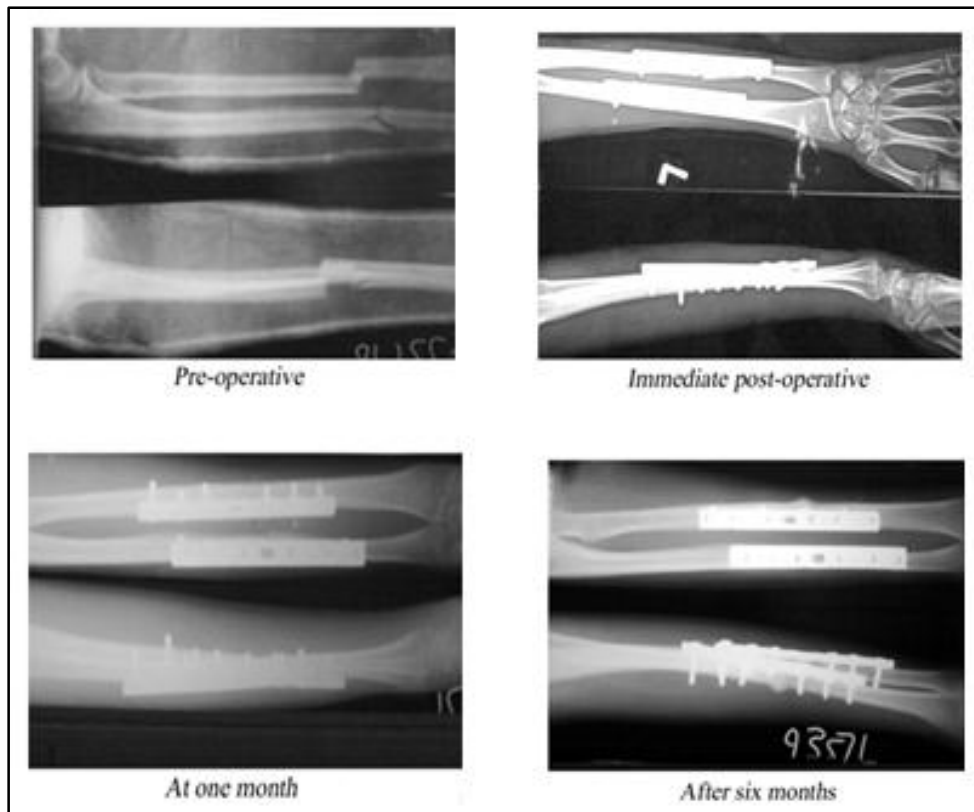
## CLINICAL PHOTOGRAPHS:

### LCP:



# ORIGINAL ARTICLE

LDCP:





**DISCUSSION:**

- Open reduction and plate fixation has been the gold standard treatment of diaphyseal forearm fractures. But the most effective type of plate fixation for diaphyseal fractures of forearm has not been well defined.
- Locked plates the “internal external fixators”, does not rely on frictional force between the plate and the bone to achieve compression and provide absolute stability.
- Thus, the local blood supply under the plate to be preserved, thereby leading to superior bone healing and minimal complications.
- It has been proved to be valuable in situations like osteoporosis, comminuted fractures, complex intra articular fractures or fractures in close proximity to the joints.
- LCP fixation was found to consume more time (mean 87.05 minutes) compared to that required for LC-DCP fixation (mean 75.94 min). This time difference was statistically not significant.
- Our study had a union rate of 100%, with one delayed union in the LCP group. The mean time of union (18.16 weeks, range 10-29 weeks) in the LCP group was found to be bit higher in comparison to LC-DCP group (16.27 weeks, range 8-21 weeks).
- LCP group has functionally better outcome [18(90%) patients had excellent results, 2(10%) patients had good results] as compared to LC-DCP group [17(85%) patients had excellent results, 3(15%) patients had good results].

**LIMITATIONS:**

- The limitation of this study is small sample size study from a single center hence significant conclusions could not be drawn.
- Conclusion-
- LC plating is an effective treatment option for fractures shaft of forearm.
- The present study could not prove the superiority of LCP over LC-DCP.
- It is the proper application of the principles of plating and not the type of plate which decides the outcome.
- Further long-term multicentric study is required to prove behaviors of the implant.

**REFERENCES:**

1. Anderson LD, Sisk D, Tooms RE, Park WI III. “Compression plate fixation in acute diaphyseal fractures of radius and ulna”. *J Bone Joint Surg AM* 1975; 57: 287-97.
2. CHAPMAN MW, Gordon JE, Zissimos AG,. “Compression plate fixation of acute fractures of the diaphyses of the radius and ulna”. *J Bone Joint Surg Am* 1989;71: 159-69.
3. Ross ER, Gourevitch D, Hasting GW. Retrospective analysis of plate fixation of diaphyseal fractures of forearm bones”. *Injury*1989 jul 20 (4): 211-4.
4. Andrew H. Crenshaw, Jr. and Edward A. Fractures of forearm treated with plates and screws. *CAMPBELL’S Operative Orthopaedics*. Vol 3. 11 edition pg: 3428-31.
5. Grace TG, Eversmann WW Jr. Forearm fractures: treatment by rigid fixation with early motion. *J Bone Joint Surg Am*. 1980 Apr; 62 (3): 433-8.
6. SMITH JE. Internal fixation in the treatment of fractures of the shafts of the radius and ulna in adults; the value of delayed operation in the prevention of non-union. *J Bone Joint Surg Br*.1959 Feb; 41-B (1): 122-131.

## ORIGINAL ARTICLE

7. Dodge HS, Cady GW. Treatment of fractures of the radius and ulna with compression plates. J Bone Joint Surg Am. 1972 Sep; 54 (6): 1167-76.
8. Schemitsch EH, Richards RR. The effect of malunion on functional outcome after plate fixation of fractures of both bones of the forearm in adults. J Bone Joint Surg Am. 1992 Aug; 74 (7): 1068-1078.
9. Droll KP, Perna P, Potter J, Harniman E, Schemitsch EH, McKee MD. J Bone Joint Surg Am. 2007 Dec; 89 (12): 2619-24.
10. Leung F, Chow SP:" Locking compression plate in the treatment of forearm fractures' a prospective study. J Orthop Surg (Hong Kong). 2006 Dec; 14 (3): 291-4.
11. S. Sharma, H. Dang, V. Sharma & S. Sharma: Treatment of diaphyseal forearm bone fractures by Locking compression Plate (LCP)." The internet journal of orthopaedic surgery.2009 volume 11 no: 1.
12. Fernando Baldy dos Reis, Flavio Faloppa."Outcome of diaphyseal forearm fracture- non-union treated by autologous bone grafting and compression plating" Annals of surgical innovation and research 2009, 3: 5.
13. Marek F.M: Axial fixation of forearm fractures. JBJS, 43-A, 1099, 1961.

### AUTHORS:

1. B. Jayachandra Reddy
2. L. Abhishek
3. R. Kathyayini

### PARTICULARS OF CONTRIBUTORS:

1. HOD, Department of Orthopaedics, Government Medical College, Ananthapuram.
2. Specialist Resident, Department of Orthopaedics, Government Medical College, Ananthapuram.
3. Post Graduate, Department of General Medicine, Rajarajeshwari Medical College.

### NAME ADDRESS EMAIL ID OF THE CORRESPONDING AUTHOR:

Dr. L. Abhishek,  
Care & Cure Clinic,  
# 13-2-392-4,  
Opp. Shanthi Nursing Home,  
Ananthapuramu.  
E-mail: abheeshake\_atp@yahoo.com

Date of Submission: 27/01/2015.  
Date of Peer Review: 28/01/2015.  
Date of Acceptance: 31/01/2015.  
Date of Publishing: 07/02/2015.