

EXTERNAL DACRYOCYSTORHINOSTOMY VERSUS ENDOSCOPIC ENDONASAL DACRYOCYSTORHINOSTOMY: A COMPARATIVE STUDYPhani Kumar Sarkar¹, Biplab Nath², Umakanta Acharjee³, Sandip Sarkar⁴, Ciranjit Noatia⁵**HOW TO CITE THIS ARTICLE:**

Phani Kumar Sarkar, Biplab Nath, Umakanta Acharjee, Sandip Sarkar, Ciranjit Noatia. "External Dacryocystorhinostomy versus Endoscopic Endonasal Dacryocystorhinostomy: A Comparative Study". Journal of Evolution of Medical and Dental Sciences 2014; Vol. 3, Issue 13, March 31; Page: 3347-3359, DOI: 10.14260/jemds/2014/2291

ABSTRACT: Background: Dacryocystitis is the inflammation of the lacrimal sac due to nasolacrimal duct obstruction. Chronic dacryocystitis is a constant threat to cornea and orbital soft tissue & always dictates surgery for correction of symptomatology. The gold standard procedure of choice for the treatment of epiphora is Dacryocystorhinostomy. This study proposes to evaluate and compare the surgical outcome of external DCR and endoscopic endonasal DCR. **METHODS:** A Retrospective, comparative, randomized interventional study was conducted from January 2012 to December 2013. 40 diagnosed cases of chronic dacryocystitis were randomized into two groups. Group A included 20 patients who underwent external Dacryocystorhinostomy and group B included the rest of the 20 patients who underwent endoscopic endonasal Dacryocystorhinostomy. **RESULTS:** In group A patients, 9 cases had bleeding during surgery, tearing of the anterior nasal flap was seen in 5 cases and punctal laceration in 4 cases. In group B patients 3 cases had bleeding, 5 cases had Trauma to the middle turbinate while accidental entry into anterior ethmoidal cells was in 4 cases. In 8 cases there was difficulty in making a bone window. In group A patients, duration of surgery is comparatively more than in group B. In post-operative period group A patients, had epistaxis, rhinostomy site closure, hypertrophied external scar and medial canthi damage as its complication while group B epistaxis, nasal Synechia, intra nasal granulation at the ostium are major complication. After a period of 3months by syringing the lacrimal sac of the patients in group A patients, 18 patients had a patent sac (success rate is 90%). In group B patients, 16 patients had a patent sac (success rate being 80%). **CONCLUSION:** DCR either by external or endonasal route can be considered for treatment of nasolacrimal duct obstruction. The external route has an easy and short learning curve with reduced cost of equipment. Whereas endoscopic DCR is time saving, avoids a facial scar and injury to the neighboring structures like the medial palpebral ligament and the angular facial vessels. In our study, the success rate of Endonasal DCR and External DCR are almost equal and comparable. This indicates that these two different DCR techniques are acceptable alternatives. However it's the preference of the patient, resource available and the surgeon himself to decide the right surgical option to axe the disease.

KEYWORDS: Dacryocystitis, Endonasal DCR, External Dacryocystorhinostomy

INTRODUCTION: Dacryocystitis is the inflammation of the lacrimal sac due to nasolacrimal duct obstruction. Obstruction leads to stagnation of tears and resultant accumulation of debris in the lacrimal sac which act as the potential nidus for the organisms to propagate within the sac causing inflammation, hyperemia, edema and hypertrophy of the mucosal epithelium. Untreated chronic dacryocystitis never undergoes spontaneous resolution. It tends to progress and walls of the sac ultimately become atonic.¹ Chronic dacryocystitis is a constant threat to cornea and orbital soft tissue. Chronic dacryocystitis is a surgical disease and almost always dictates surgery for correction

ORIGINAL ARTICLE

of symptomatology. The gold standard procedure of choice for the treatment of epiphora is Dacryocystorhinostomy [DCR]. It was Toti in 1904 who first illustrated the procedure setting up of external DCR via the transcutaneous route. But it was Caldwell in 1893 who first described endonasal approach by fiberoptic endoscope in order to alleviate the facial scarring and unnecessary dissection of both orbicularis oculi and orbital periosteum. In 1989 Mc Donogh and Meiring did first endoscopic transnasal DCR.² This study proposes to evaluate and compare the surgical outcome of external DCR and endoscopic endonasal DCR.

MATERIALS AND METHODS: A Retrospective, comparative, randomized interventional study was conducted in the Department of Ophthalmology, in a tertiary care centre of Tripura in collaboration with Department of Otorhinolaryngology and head neck surgery from January 2012 to December 2013. The patients attending the ophthalmology and the ENT outpatient departments, fulfilling the inclusion and exclusion criteria were taken up as case.

The study included 40 cases that were diagnosed with primary acquired nasolacrimal duct obstruction or chronic dacryocystitis. The observations of the patients are shown in table I, II, III. They were randomized into two groups. Group A included 20 patients who underwent external Dacryocystorhinostomy and group B included the rest of the 20 patients who underwent endoscopic endonasal Dacryocystorhinostomy.

All symptomatic cases of epiphora which were diagnosed for primary acquired nasolacrimal duct obstruction or chronic dacryocystitis and willing to undergo surgery are taken up as cases. Patients were excluded if tearing was due to canalicular and punctal obstruction or lower eyelid laxity or with Ectropion or entropion. Surgery, external or endoscopically performed, was based on surgeon preference. Surgery, externally or endoscopically was done by a single surgeon.

Each patient was subjected to detailed history taking followed by ocular and adnexal exam as per a predesigned Performa. The Ocular examination was done by an ophthalmologist. The eyelids were examined for Ectropion, entropion and lid laxity. Examination of the puncti for their normal location and size were evaluated. Any medial canthal swelling was noted. Nasolacrimal duct obstruction was diagnosed by the regurgitation of fluid into the conjunctival sac by applying pressure over the lacrimal sac area (Regurgitation test). Lacrimal sac syringing was done to confirm the diagnosis. An ENT surgeon conducted a thorough anterior rhinoscopy and any abnormalities like atrophic rhinitis, deviated nasal septum, polyposis, and hypertrophied turbinates were noted.

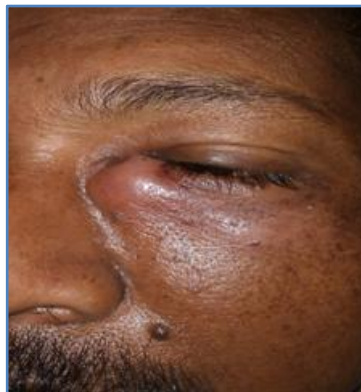

Fig. 1: Patient presenting with mucocele

ORIGINAL ARTICLE

Preoperative investigations included a complete haemogram, blood sugar, bleeding and clotting time, X Ray Para nasal sinus – water's view etc. All patients had preoperative counseling and both the procedures were explained in detail with their advantages and disadvantages.

Age in years (5 to 50 years)	No. of cases Ex DCR	No. of cases En DCR
1-10	-	-
11-20	3	6
21-30	7	8
31-40	6	4
41-50	4	2
Total	20	20

Table I: Showing age distribution

Group	Male	Female	Total
ExDCR	3	17	20
EnDCR	2	18	20
Total	5	35	40

Table II: Showing sex distribution

SL. No.	Clinical picture	No. of cases
1	Persistent watering	18
2	Mucopurulent regurgitation	15
3	Swelling in sac area (mucocele)	6
4	Lacrimal fistula	1

Table III: Showing clinical picture of chronic dacryocystitis

THE TECHNIQUE OF EXTERNAL DACRYOCYSTORHINOSTOMY: All the surgical steps of external Dacryocystorhinostomy operations were performed under local anesthesia with 2% xylocaine with adrenaline 1:2, 00,000. Strict aseptic measures were maintained while carrying out all the procedures. The nasal mucosa was anaesthetized with a 10% xylocaine spray and packed with roller gauze which was soaked in 4% xylocaine with adrenaline 1:10, 000. A curvilinear incision, 1.5 to 2cms in length, was made medial to the angular vein, 8 mm from the medial canthus. The orbicularis muscle fibres were separated.

The lacrimal fascia was incised 1mm lateral to the anterior lacrimal crest and the bony attachment of the medial canthal ligament was divided. The lacrimal sac was separated from the lacrimal fossa. The lamina papyracea was fractured and the nasal mucosa was stripped from the lacrimal bone to avoid damage to it.

A bony ostium, approximately 10mm in diameter, was created. The lower punctum was dilated and a Bowman's probe was passed through it to tent the medial sac wall. With an 11 No. Bard Parker blade, the lacrimal sac and then the nasal mucosa were opened in an "H" shaped fashion to

ORIGINAL ARTICLE

form larger anterior and smaller posterior flaps. The anterior flaps of the nasal mucosa and the lacrimal sac were sutured by using interrupted sutures with 6.0 Vicryl.

The incision was closed in layers and a dressing was applied. The duration of surgery was measured from the making of the incision on the skin to the end of the closure of the skin incision by suturing.

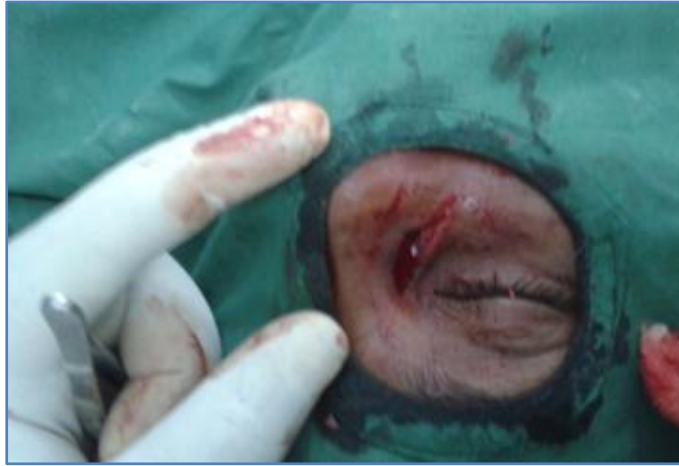

Fig. 2: Intra operative picture of a patient in group A

THE TECHNIQUE OF ENDOSCOPIC ENDONASAL DACRYOCYSTORHINOSTOMY: All the surgical steps of endonasal Dacryocystorhinostomy operations were performed under local anesthesia with 2% Xylocaine with adrenaline 1:2, 00,000. Strict aseptic measures were maintained while carrying out all the procedures. The nasal mucosa is anaesthetized with a 10% xylocaine spray and packed with roller gauze which was soaked in 4% xylocaine with adrenaline 1:10, 000.

The mucosa of the lateral nasal wall was infiltrated with 2% xylocaine with 1:2, 00, 000 adrenaline, just anterior to the attachment of the middle turbinate.

A 1x1cm piece of mucus membrane which was anterior to the uncinata process was incised and excised with a 15 No. Bard Parker blade. The lacrimal bone overlying the lacrimal sac area was removed by using punch forceps. The lacrimal sac was visualized after the removal of the lacrimal bone. More bone was removed to expose the medial wall of the sac. The lacrimal part of the fossa was removed up to the base of the uncinata process. Thus, about 1x1cm of bone was removed to expose the medial wall of the sac completely.

The lacrimal sac was confirmed endoscopically by applying pressure on the outside over the medial canthus and the bulging of the sac was noticed intra nasally. Externally, the eye was anaesthetized with 4% xylocaine drops, the lower punctum was dilated and a Bowman's probe was inserted in order to tent the medial wall of the sac intra nasally.

The tented mucosa of the sac was incised by a sickle knife and the medial wall of the sac was excised. Lacrimal sac syringing was done with normal saline and a free flow of the fluid was observed endoscopically. The nose was packed with Neosporin ointment smeared ribbon gauze on the operated side.

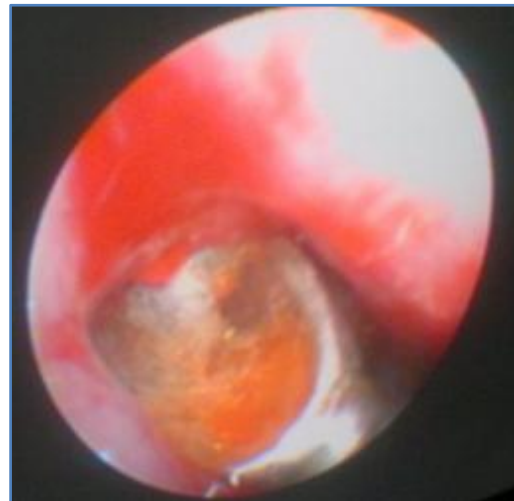
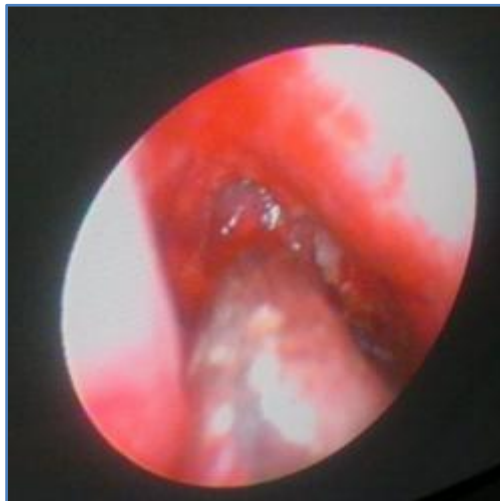
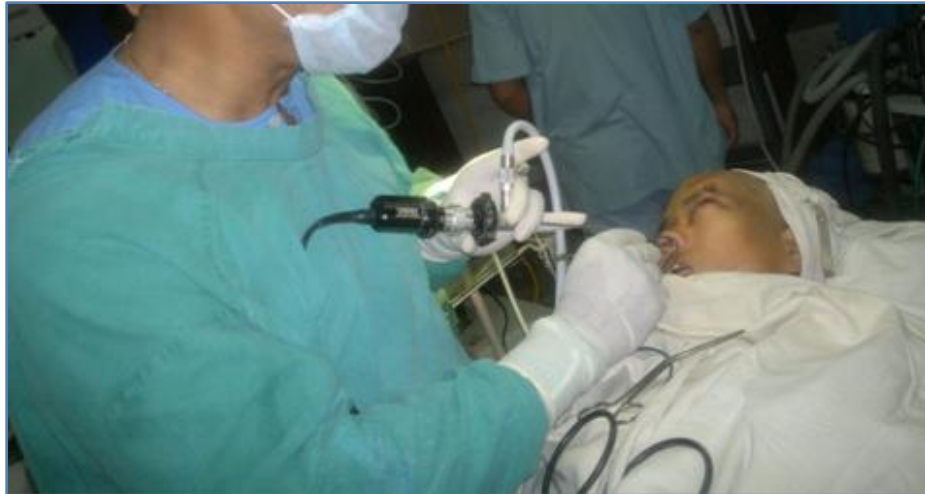
Fig. 3: Intraoperative picture of Endonasal endoscopic Dacryocystorhinostomy

Postoperatively, patients were examined at 1 week, 1 month, 3 month and 6 months thereafter the patency of the lacrimal passage was investigated by sac syringing.

Failure was defined as any of the following: (1) no improvement in tearing symptoms or any episode of postoperative dacryocystitis, (2) inability to irrigate the lacrimal system postoperatively.

Success was defined as marked improvement in watering—that is, patients did not report additional episodes of watering postoperatively.

RESULTS AND OBSERVATION: The present study involved 40 cases. They were divided into two groups of 20 each. Group A underwent external DCR and Group B underwent endoscopic endonasal DCR.

In group A patients, those underwent external DCR, 3(15%) cases had severe bleeding that required blood transfusion in post-operative period while 6(30%) cases had moderate bleeding. Tearing of the anterior nasal flap was seen in 5 cases while in 4 cases there was laceration of the

ORIGINAL ARTICLE

punctum. All the complications were managed intra operatively by a single surgeon .Complications encountered in those patients are shown in table IV.

COMPLICATIONS ENCOUNTERED DURING SURGERY	NO. OF CASES	PERCENTAGE
Severe bleeding	3	15%
Moderate bleeding	6	30%
Tearing of anterior nasal flap	5	25%
Laceration of punctum	4	20%
Accidental entry into anterior ethmoidal air cells	2	10%

Table IV: Complications encountered in Group A patients

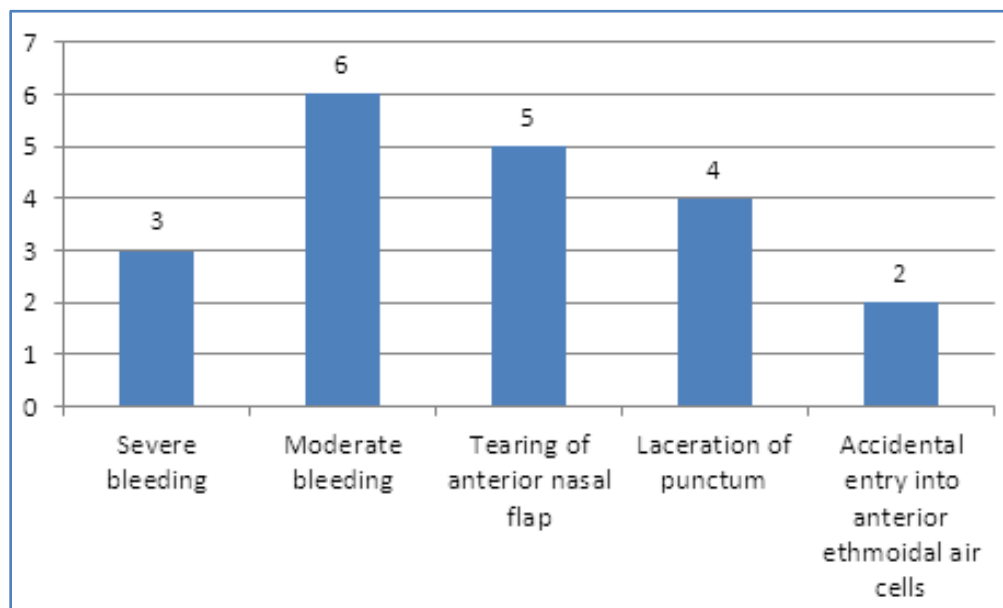


Figure 4

In group B those underwent endoscopic endonasal DCR patients 1 (05%) cases had severe bleeding required blood transfusion in post-operative period while 2(10%) cases had moderate bleeding. Trauma to the middle turbinate was seen in 5 cases while in 4 cases there was accidental entry into anterior ethmoidal cells. In 8 cases there was difficulty in making a bone window. Complications encountered in those patients are shown in table V.

ORIGINAL ARTICLE

COMPLICATIONS ENCOUNTERED DURING SURGERY	NO. OF CASES	PERCENTAGE
Severe bleeding	1	05%
Moderate bleeding	2	10%
Trauma to the middle turbinate	5	25%
Difficulty in making a bone window	8	40%
Accidental entry into anterior ethmoidal air cells	4	20%

Table V: Complications encountered in Group B patients

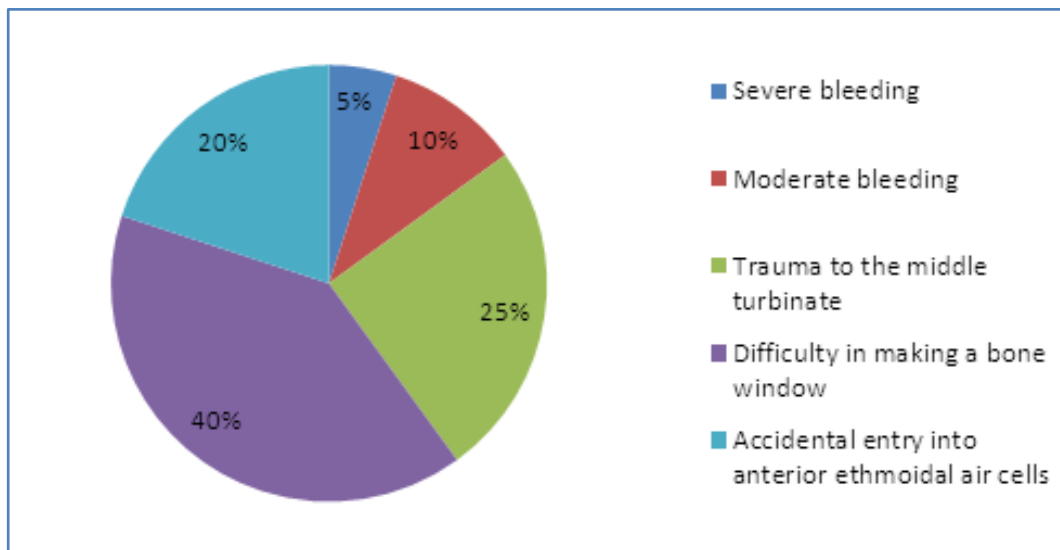


Figure 5

In group A patients, those underwent external DCR duration of surgery is comparatively more than in group B those underwent endoscopic endonasal DCR patients.

DURATION OF SURGERY	GROUP A PATIENTS		GROUP B PATIENTS	
	No.s.	%	No.S.	%
< 30 MIN	02	10%	05	25%
30-60 MIN	10	50%	14	70%
60-90 MIN	08	40%	01	05%

Table VI: Time consumed in both groups of patients

ORIGINAL ARTICLE

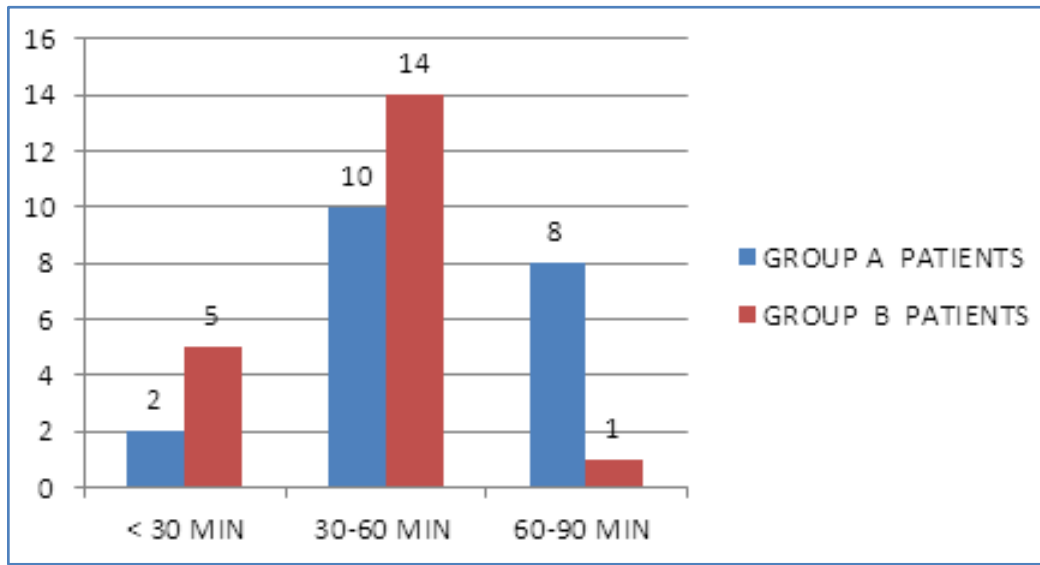


Figure 6

In group A patients, those underwent external DCR it has been seen that epistaxis was found in 1 case. The rhinostomy site was closed in 1 case. 8 out of 20 patient had hypertrophied external scar while 4 cases had damage to the medial canthi.

COMPLICATIONS	NO OF CASES	PERCENTAGE
Epistaxis	01	05%
Wound infection/ gaping	00	00%
Hypertrophied external scar	08	40%
Closure of osteum	01	05%
Damage to medial canthi	04	20%

Table VII: Post-operative complications encountered in Group A patients

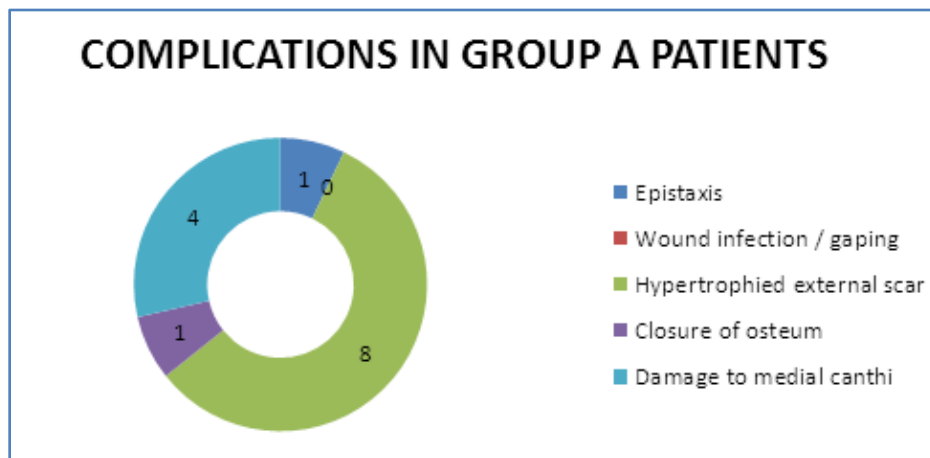


Figure 7

ORIGINAL ARTICLE

In group B those underwent endoscopic endonasal DCR it has been seen that 1 case had epistaxis, 5 cases developed nasal Synechea, and 1 case developed intra nasal granulation at the ostium which obstructed the rhinostomy site.

COMPLICATIONS	NO OF CASES	PERCENTAGE
Epistaxis	01	05%
Nasal Synechea	05	25%
Granulation	01	05%
Obstruction at rhinostomy site	01	05%

Table VIII: Post-operative complications encountered in Group B patients

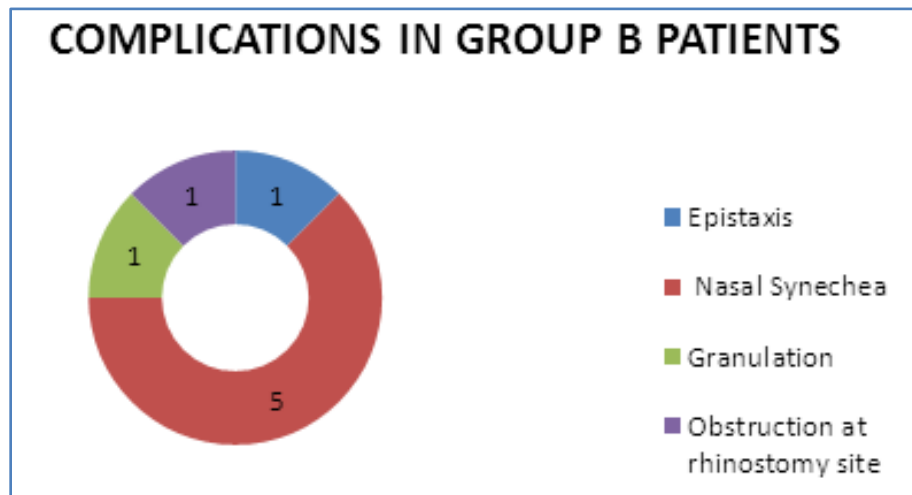


Figure 8

Both the study groups were evaluated after a period of 3 months by syringing the lacrimal sac of the patients. In group A patients, those underwent external DCR, 18 patients had a patent sac and the patients were found to be symptom free. Here the success rate is 90%. On the same side in group B patients, those underwent endoscopic endonasal DCR, 16 patients had a patent sac, success rate being 80%. In each group 1 case had a partial blockage and mucoid fluid regurgitated out. In group A 1 case and 3 cases in group B had complete blockage and was advised for further intervention.

GRADING	SYRINGING	EXT DCR	ENDO DCR
1	PATENT	18(90%)	16(80%)
2	PARTIAL BLOCK WITH FLUID REGURGITATION	01(05%)	01(05%)
3	COMPLETE BLOCK	01(05%)	03(15%)

Table IX: Comparison of outcome in both Group of patients

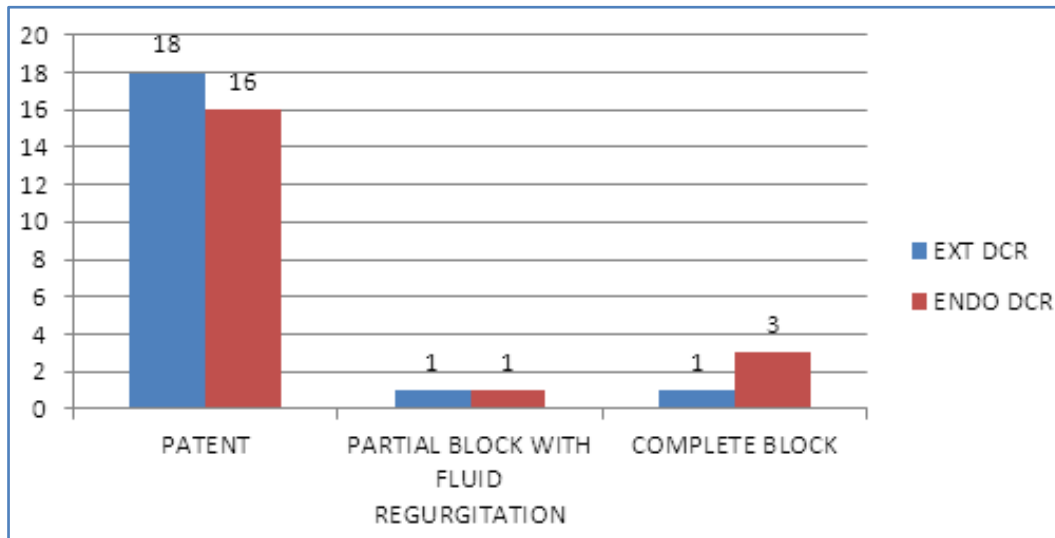


Figure 9

DISCUSSION: Nasolacrimal duct obstruction can be approached either externally by transcutaneous route or by endonasal approach by fiberoptic endoscope. A lot of Comparative study was conducted in relation to the two approaches.

In our study it has been seen that the majority of the patients were female. The male -female ratio being 1:7 that were grouped into two groups. The female preponderance is in accordance to the literature.³ In our study most of the patients were young aged and belonged to the 3rd decades of life followed by 4th decade. The patients presented with persistent watering, Mucopurulent regurgitation, Swelling in sac area (mucocele), Lacrimal fistula which are usually the classical presentation of patients with dacryocystitis as described in the literature.⁴

In group A patients, those underwent external DCR, bleeding was the most common complication encountered during surgery. Adequate hemostasis was achieved intra operatively but those 3 cases required blood transfusion in post-operative period. Tearing of the anterior nasal flap and laceration of the punctum during surgery was also reported during operation. All the complications were managed intra operatively by a single surgeon.

Bruising, Wound infection, Cerebrospinal fluid leaking, Punctal eversion, Inadvertent incision of periorbital which are known complications of external DCR mentioned in various studies has not been reported in our study.⁵

In group B those underwent endoscopic endonasal DCR, bleeding was the most common complication encountered during surgery like that seen in group A. Adequate hemostasis' was achieved intraoperatively by anterior nasal package. Trauma to the middle turbinate, accidental entry into anterior ethmoidal cells and difficulty in making a bone window are the complications encountered and managed intra operatively by a single surgeon.

In group A patients, those underwent external DCR duration of surgery is comparatively more than in group B those underwent endoscopic endonasal DCR patients. 14 cases of endoscopic endonasal DCR patients need an average time of 35 min while 10 cases of external DCR required average time of 50 min for each surgery.

ORIGINAL ARTICLE

In group A patients, in post-operative period epistaxis was found in 1 case. The rhinostomy site was closed in 1 case. These were reported in the first postoperative day in our study. 8 out of 20 patient had hypertrophied external scar while 4 cases had damage to the medial canthi. These complications are noted after 1 month of operation when patient reviewed. While in group B those underwent endoscopic endonasal DCR it has been seen that 1 case had epistaxis in the 2nd postoperative day that was managed by anterior nasal package, 5 cases developed nasal Synechia, 1 case developed intra nasal granulation at the ostium which obstructed the rhinostomy site which were noted after 1 month of operation when patient reviewed.

Complications during endonasal DCR like sump syndrome, transient damage to the medial rectus muscle with diplopia, damage to the nasal mucosa with scar formation, orbital fat prolapse, secondary canalicular stenosis, recurrence of lacrimal mucocele, and adhesions between the ostium and the septum are reported in many studies. No such complications were found in our study.^{6,7}

Hartikainen et al in their comparative study found that the success rate of External DCR has been 80% to 99%.⁸ In our study the success rate of endonasal DCR was 80% after a single procedure which was slightly lesser than External DCR where success rate was 90%. A thorough knowledge of the intranasal anatomy, experience of surgeon and careful operative techniques is always the key of success of an endonasal DCR. A wide osteotomy and preservation of mucosa around the lacrimal window decreases postoperative scarring and stenosis thereby increasing the success rate.⁹ However the success rate of both the procedure in our study is comparable.

Endoscopic endonasal DCR proved to be a landmark in nasolacrimal surgeries providing a paradigm of advantages. The most important being the preservation of the physiological pump system. The medial canthi ligament remains intact thereby it maintains the contour of the inner aspect of the eye. A Minimal blood loss during surgery alleviates the unnecessary hazards of blood transfusion in the post-operative period. The young patient was exempted of any ugly facial scar in the post-operative periods. It is easy and less painful. A comparatively lesser operative time is required than for the conventional external DCR. Patient gets early ambulation thereby reducing the hospital stay. If there is blockage or narrowing of ostium that has been detected in the post-operative check-up, it can be dealt with as OPD procedure. It allows some common intranasal causes of ExDCR failure to deal with concomitantly like DNS, nasal polyp, hypertrophied middle turbinate etc.^{10,11,12}

On the either side Endoscopic endonasal DCR needs sophisticated instruments to deal with. A thorough knowledge of the intranasal anatomy is must for an Ophthalmologist to start with this procedure which usually requires a longer learning curve^{13,14}. In this regard studies have suggested that external DCR helps in good anatomic identification of the sac and mucosal lining, whereas the inside of the sac is not always visible in endoscopic surgery thus making external DCR a much successful surgery than endonasal approach.¹⁵

CONCLUSION: DCR either by external or endonasal route can be considered for treatment of nasolacrimal duct obstruction. The external route has an easy and short learning curve with reduced cost of equipment. Whereas endoscopic DCR is time saving, avoids a facial scar and injury to the neighboring structures like the medial palpebral ligament and the angular facial vessels. In our study, the success rate of Endonasal DCR and External DCR are almost equal and comparable. This indicates that these two different DCR techniques are acceptable alternatives. However it's the preference of

the patient, resource available and the surgeon himself to decide the right surgical option to axe the disease.

REFERENCES:

1. Sihota R, Tandon R. Parsons' Diseases of the Eye. 21st ed. New Delhi: Elsevier; 2011. Chapter 29, Diseases of the Lacrimal Apparatus; p.464
2. Susan MH. The history of lacrimal surgery. *Adv Ophthal Plastic Reconstruct Surg.* 1986; 139 – 168.
3. Kanski J J, Bowling B. *Clinical Ophthalmology A Systemic Approach.* 7th ed. Mumbai: Current Technical Literature; 2011. Chapter 2, Lacrimal Drainage System; p.77
4. Khurana A K. *Comprehensive Ophthalmology.* 5th ed. New Delhi: New age international limited, 2012. Chapter 15, Diseases of lacrimal apparatus; p.387-402.
5. Dolman PJ. Comparison of external Dacryocystorhinostomy with nonlaser endonasal dacryocystorhinostomy. *Ophthalmology.* 2003; 110:78-84.
6. Moore WMH, Bentley CR, Olver JM. Functional and anatomic results after two types of endoscopic endonasal dacryocystorhinostomy: surgical and holmium laser. *Ophthalmology.* 2002; 109:1575- 82.
7. Fayet B, Racy E, Assouline M. Complications of standardized endonasal dacryocystorhinostomy with unciformectomy. *Ophthalmology.* 2004; 111:837-45.
8. Hartikainen J, Antila J, Vaipula M, Puukka P, Seppa H, Grenman R. Prospective randomized comparison of endonasal endoscopic dacryocystorhinostomy and external dacryocystorhinostomy. *Laryngoscope.* 1998;108(12): 1861 -1866.
9. Yung MW, Hardman-Lea S. Analysis of the results of surgical endoscopic dacryocystorhinostomy: effect of the level of obstruction. *Br J Ophthalmol.* 2002; 86:792-794.
10. Nussbaumer M, Schreiber S, Yung MW. Concomitant nasal procedures in endoscopic dacryocystorhinostomy. *J Laryngol Oto.,* 2004; 118:267-9.
11. Kamel R, El-Deen HG, El-Deen YS, et al. Manometric measurement of lacrimal sac pressure after endoscopic and external dacryocystorhinostomy. *Acta Otolaryngol.* 2003 Jan; 1 23(2):325-9.
12. Nalgirkar AR, Sulache AA. Comparative evaluation of results of endoscopic DCR and external DCR. *Indian journal of Otolaryngology and Head & Neck Surgery.* 2005; II: 363-365.
13. McDonogh M, Meiring JH. Endoscopic transnasal dacrocystorhinostomy. *J Laryngol Otol.* 1989 Jun; 103(6):585-7.
14. Woog JJ, Kennedy RH, Custer PL, Kaltreider SA, Meyer DR, Camara JG. Endonasal dacryocystorhinostomy: a report by the American Academy of Ophthalmology. *Ophthalmology.* 2001 Dec; 108 (12):2369-77.
15. Delaney YM, Khooshabeh R. External Dacryocystorhinostomy for the treatment of acquired partial nasolacrimal obstruction in adults. *Br J Ophthalmol* 2002; 86:533-5.

AUTHORS:

1. Phani Kumar Sarkar
2. Biplab Nath
3. Umakanta Acharjee
4. Sandip Sarkar
5. Ciranjit Noatia

PARTICULARS OF CONTRIBUTORS:

1. Associate Professor, Department of Ophthalmology, AGMC.
2. Associate Professor, Department of Otorhinolaryngology and Head Neck Surgery, AGMC.
3. Post Graduate Trainee, Department of Ophthalmology, AGMC.
4. Medical Officer, Department of Ophthalmology, AGMC.

5. Medical Officer, Department of Ophthalmology, AGMC.

NAME ADDRESS EMAIL ID OF THE CORRESPONDING AUTHOR:

Dr. Phani Kumar Sarkar,
Associate Professor,
Department of Ophthalmology,
Agartala Government Medical College,
Kunjaban, Agartala – 799006.
E-mail: drphainkumar.sarkar@gmail.com

Date of Submission: 27/03/2014.

Date of Peer Review: 28/03/2014.

Date of Acceptance: 14/03/2014.

Date of Publishing: 26/03/2014.