

LICHENSTEIN TENSION FREE MESH HERNIOPLASTY: A PROSPECTIVE STUDY

Rakesh K. Gupta¹, Bhuvan², K. S. Shahi³, Geeta Bhandari⁴, Prashant Pandey⁵, Malvika Sawai⁶

HOW TO CITE THIS ARTICLE:

Rakesh K. Gupta, Bhuvan, K. S. Shahi, Geeta Bhandari, Prashant Pandey, Malvika Sawai. "Lichenstein Tension Free Mesh Hernioplasty: A Prospective Study". Journal of Evolution of Medical and Dental Sciences 2014; Vol. 3, Issue 67, December 04; Page: 14424-14429, DOI: 10.14260/jemds/2014/3935

ABSTRACT: INTRODUCTION: Mesh inguinal hernioplasty is one of the most commonly performed surgery by general surgeons. One of the significant problems following hernia repair is recurrence. Prosthetic materials like polypropylene mesh has been used for inguinal hernia repair and has many advantages like low recurrence rates, less postoperative pain, decreased hospital stay and fewer complications. **MATERIALS AND METHODS:** In this prospective study, 432 open Lichenstein tension-free inguinal mesh hernioplasty was performed between June 2004 and May 2014. Various parameters regarding postoperative complications were studied. **RESULTS:** In 432 cases, inguinal hernia was indirect in 59.03% of cases (255 cases), direct in 36.57% (158 cases) and of the pantaloon (mixed) type in 4.39% (18 cases). Mean age of patients was 50.8 years (range 19–92). The median follow-up period was 2.1 years (range 1 month–5 years). Seroma and hematoma formation requiring drainage was observed in 9 and 11 patients, respectively, while transient testicular swelling occurred in 28 patients. We have not observed acute infection or abscess formation related to the presence of the foreign body (mesh). There was one recurrence of the hernia. Residual neuralgia was observed in 3 patients. **CONCLUSION:** Lichtenstein Tension-free mesh hernioplasty has many advantages of being simple, effective, low recurrence rate, early return to daily activities and good patient compliance and satisfaction. This technique is preferable for hernia repair in our setting.

KEYWORDS: inguinal hernia, prolene mesh, Lichenstein, tension free repair

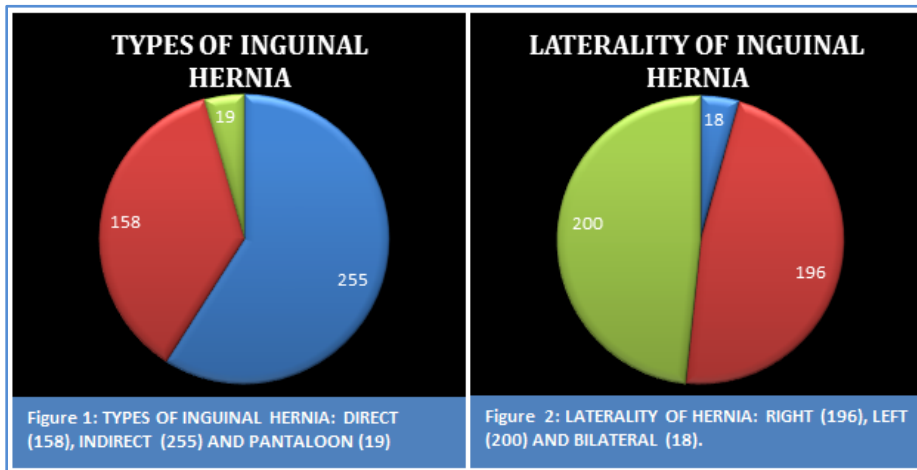
INTRODUCTION: Mesh inguinal hernioplasty is one of the most commonly performed surgery by general surgeons. One of the significant problems following hernia repair is recurrence. Prosthetic materials like polypropylene mesh has been used for inguinal hernia repair and has many advantages like low recurrence rates, less postoperative pain, decreased hospital stay and less complication. Defect in the metabolism of collagen causing weakening of transversalis fascia is involved in the pathogenesis of inguinal hernia in adults.^[1] Various techniques including autologous tissue techniques and a variety of biomaterials have been used to reduce the recurrences, complications and plastic reconstruction.^[2,3] Stoppa et al, Lichtenstein, as well as the innovation of laparoscopic hernia repair, where the use of prosthetic material was associated with many advantages, greatly contributed to this change in our surgical philosophy.^[4,5,6] Present study was undertaken to evaluate the effectiveness of Lichenstein mesh hernioplasty.

MATERIALS AND METHODS: This prospective study was carried out in 414 patients of inguinal hernia. Lichenstein tension free mesh hernioplasty with prolene mesh was performed in all cases. A total of 432 hernioplasties were performed. Inclusion criteria was age >18 years, reducible hernia and symptoms and signs of hernia for >2 months. Exclusion criteria were age <18 years, irreducible hernia, obstructed hernia, strangulated hernia, recurrent hernia, patients who could not afford the mesh and patients with uncontrolled diabetes mellitus. After admission a detailed history and

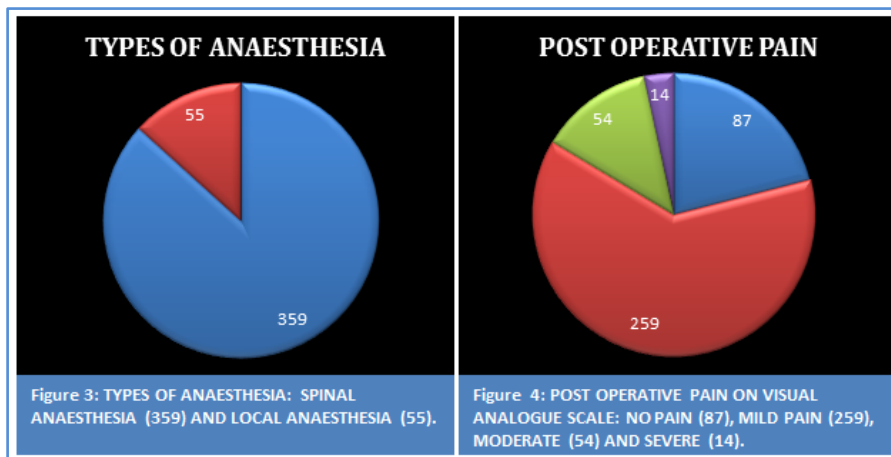
ORIGINAL ARTICLE

examination was performed. All patients were investigated for complete hemogram, liver and renal function test, coagulation profile, blood glucose and chest x-ray. Electrocardiogram was done in all patients. Permission to carry out the study was obtained from Institutional Ethical Committee. All cases were operated in single surgical unit of institute.

RESULTS: Inguinal hernia was indirect in 59.03% of cases (255 cases), direct in 36.57% (158 cases) and of the pantaloon (mixed) type in 4.39% (19 cases) (Figure: 1). Mean patient age was 50.8 years (Range, 19-92). There were 4.34% cases (18 patients) with bilateral hernia, 47.34% cases (196 patients) had right inguinal hernia and 48.31% cases (200 patients) had left inguinal hernia (Figure: 2). 86.71% cases (359 patients) were operated under spinal anesthesia and 13.29% cases (55 patients) were operated under local anaesthesia. (Figure: 3).



Postoperative pain was recorded on visual analogue scale as no pain, mild, moderate and severe. The pain was easily relieved by the use of single analgesics. 87 patients (21.01%) had no pain in postoperative period, while 259 patients (62.56%) had mild pain, 54 patients (13.04%) had moderate pain and 14 patients (3.38%) complaint of severe pain (Figure: 4). Postoperative pyrexia not more than 102^oF was seen in 67 patients (16.18%). Mean operating time was 36 minutes (range was 27 min to 63 min). Mean postoperative stay was 54 hours (range from 42 hours to 76 hours). Acute urinary retention was seen in 97 patients (23.42%).



ORIGINAL ARTICLE

Seroma formation was seen in 9 patients (2.17%) and hematoma was seen in 11 patients (2.66%) and was relieved by aspiration by disposable needle of 18G. Superficial surgical site infection was seen in 12 patients (2.89%) and 2 patients (.48%) had deep surgical site infection but not associated with mesh infection. Residual neuralgia was seen in 3 patients (.72%) and was relieved by use of analgesics and methylcobalamin in 1 month in all 3 patients. Transient testicular swelling was noticed in 28 patients (6.76%) who were relieved by use of scrotal bandage and scrotal support. Abdominal distension was present in 3 patients (.72%) which was relieved by Ryle's tube insertion and digital rectal stimulation. (Table: 1).

N=414	
MEAN AGE	50.8 YEARS (RANGE 19-92 YEARS)
MEAN OPERATING TIME	36 MINUTES (RANGE 27-63 MINUTE)
MEAN POSTOPERATIVE STAY	54 HOURS (RANGE 42-76 HOURS)
MEAN FOLLOW-UP PERIOD	2.1 YEARS (RANGE 1 MONTHS-5 YEARS)
FEVER <102°F	67 (16.18%)
ACUTE RETENTION OF URINE	97 (23.42%)
SEROMA FORMATION	9 (2.17%)
HEMATOMA	11 (2.66%)
SUPERFICIAL SURGICAL SITE INFECTION	12 (2.89%)
DEEP SURGICAL SITE INFECTION	2 (.48%)
RESIDUAL NEURALGIA	3 (.72%)
TRANSIENT TESTICULAR SWELLING	28 (6.76%)
ABDOMINAL DISTENSION	3 (.72%)
ISCHEMIC ORCHITIS	0
TESTICULAR ATROPHY	0
MESH REJECTION	0
MORTALITY	0
DEEP VENOUS THROMBOSIS	1 (.24%)
RECURRENCE	1(.24%)

TABLE 1: PATIENTS CHARACTERISTICS AND POST OPERATIVE COMPLICATION

In follow up none of the patients had ischemic orchitis, testicular atrophy, mesh rejection and mortality. Deep venous thrombosis was noticed in 1 patient (.24%) and was managed by low molecular weight heparin. Recurrence was seen in one patient (.24%) in mean follow-up period of 2.1 years (range 1 months-5 years).

DISCUSSION: A hernia is a protrusion of a viscus or part of a viscus through an abnormal opening in the walls of its containing cavity. The patient usually presents with bulge or swelling in groin region and can leads to complications like necrosis/gangrene of the content of hernia sac.

Inguinal hernias have been witnessed, since the time of the Egyptian Pharaohs. The mummy of Ramses 5th shows a hernial sac in the groin.^[7] Hippocrates referred hernia as “etrurhexis”, which means” rupture of abdominal wall”. In 1559, Stromayer distinguished the direct and the indirect inguinal hernia. After description of the “processus vaginalis” by John Hunter in 1790, and the “fascia

ORIGINAL ARTICLE

transversalis” and the “Cooper's ligament” by Sir Astley Cooper in 1804 the anatomy of hernia became more clear.^[8] In 1887 Bassini described the three layered technique for hernia repair was a major achievement. Earl Shouldice in 1953 modified Bassini's repair and popularized a 4-layer closure through a special continuous suturing technique and doubling the fascia transversalis.^[9] The recurrence rate was 0.8% in his series of 8317 hernias over a 10 year period. Nyhus described the posterior iliopubic tract technique in which the arch of the transverses abdominis aponeurosis was sutured to the iliopubic tract.^[10] Mersilene was first nonmetallic fabric mesh made from Dacron in 1939. Polypropylene mesh was introduced by Usher in 1950.^[11] Irving Lichtenstein popularized tension free techniques for hernia repair and performed it as outpatient procedure under local anaesthesia. Stoppa introduced a technique to repair large inguinal hernias by using a mesh posteriorly through a midline incision.^[12] Gilbert-Rutkow introduced a plug and mesh and Gilbert introduced a polypropylene device Prolene Hernia System (PHS).^[13] Laparoscopic inguinal hernia repair was started in 1990 such as TAPP (transabdominal preperitoneal approach and TEP (total extra peritoneal approach).^[14] The principle of the laparoscopic repair is to cover all the three potential sites of inguinal hernia by using a large piece of mesh.^[15] Laparoscopic hernia repairs are less painful, less hospital stay, early resume of activities but have higher cost.^[16]

Lichtenstein Tension-free mesh hernioplasty was described by Irving Lichtenstein about 31 years ago, was a start of new era in the repair of inguinal hernia.^[5] The tension free technique has benefit of being simple, effective, postoperative pain is minimal, very low chance of recurrence and can be performed under local or regional anaesthesia.^[17,18,19] Elective inguinal hernia repair under local anesthetic has a good outcome also in the elderly even if there are significant comorbidities.^[20] Currently, Lichtenstein Tension-free mesh hernioplasty is the preferred method for the plastic reconstruction of inguinal hernias for the majority of surgeons around the world.

The ideal properties of mesh are inertness, resistance to infection, molecular permeability, pliability, transparency, mechanical integrity, and biocompatibility. Polypropylene monofilament mesh is the most popular presently in use.^[19] The monofilament, porous polypropylene mesh allows a large surface area for in-growth of vascularized connective tissue leading to permanent fixation of the prosthesis within the abdominal wall. The recurrence rate can be minimized by extending the size of mesh 2-4 cm beyond the boundary of Hesselbach's triangle.^[18]

The mesh is laid beneath the external oblique aponeurosis and it keeps the mesh in position when the intraabdominal pressure rises. The mesh is sutured or stapled to prevent wrinkling, folding or displacement of mesh. Inguinal mesh hernioplasty is simple technique of hernia repair. Very low recurrence rate from 0-0.7% has been reported in various studies.^[17,21,22,23]

CONCLUSION: We have observed that Lichtenstein Tension-free mesh hernioplasty is simple, safe, effective and economical and has good patient satisfaction. Recurrence rate is acceptable. In our opinion this procedure is acceptable for hernia surgery.

REFERENCES:

1. Sakorafas G H, Halikias I, Nissotakis C, Kotsifopoulos N, Stavrou A, Antonopoulos C, Kassaras G A. Open tension free repair of inguinal hernias; the Lichtenstein technique BMC Surgery 2001, 1:3. Available from URL:<http://www.biomedcentral.com/1471-2482/1/3>.
2. Bassini E: Sulla cura radicale dell'ernia inguinale. Arch Soc Ital Chir 1887, 4: 380-388.

ORIGINAL ARTICLE

3. De Bord JR: The Historical development of prosthetics in hernia surgery. *Surg Clin North Am* 1998, 78: 973-1006.
4. Stoppa RE, Petit J, Henry X: Unstitched Dacron prosthesis in groin hernias. *Int Surg* 1975, 60: 411-419.
5. Lichtenstein IL, Shulman AG, Amid PK, et al: The tension free hernioplasty. *Am J Surg* 1989, 157: 188-193.
6. Ramshaw BJ, Tucker JG, Duncan TD: Laparoscopic herniorrhaphy: A review of 900 cases. *Surg Endosc* 1996, 10: 255-232.
7. Dorairajan N. Inguinal Hernia-yesterday, today and tomorrow. *Indian J Surg* 2004; 66: 137-139.
8. Lichtenstein IL. *Hernia Repair without Disability*. St. Louis: The C.V. Mosby Company; 1970. p. 1-8.
9. Shouldice EE. The treatment of the Hernia. *Ontario Med Rev* 1953; 1: 1-14.
10. Nyhus LM. The posterior (preperitoneal) approach and iliopubic tract repair of Inguinal and Femoral Hernias: An update. *Hernia* 2003; 7: 63-67.
11. DeBord JR. Prostheses in Hernia surgery: A century of evolution. In: Ben David R, Abrahamson J, Arregui MF, eds. *Abdominal wall Hernias*. New York: Springer; 2001. p. 16-32.
12. Stoppa RE. The midline preperitoneal approach and prosthetic repair of groin Hernias. In: Fitzgibbons RJ, Greenburg AG, eds. *Nyhus and Condon's Hernia*, 5th ed. Philadelphia: Lippincott, Williams & Wilkins; 2002. p. 199-214.
13. Gilbert AI. Improved sutureless technique: Advice to experts. *Prob Gen Surg* 1995; 12: 117-9.
14. Felix EL, Michas CA, McKnight RL. Laparoscopic herniorrhaphy transabdominal preperitoneal floor repair. *Surg Endosc* 1994; 8: 103-4.
15. Heithold DL, Ramshaw BJ, Mason EM, et al. 500 Total extraperitoneal approach Laparoscopic Herniorrhaphies: A single institution review. *Am Surg* 1997; 63: 299-301.
16. Sylopoulos N, Gazelle GS, Rattner DW. A cost utility analysis of treatment options for Inguinal Hernias in 1,513,000 adult patients: Randomized controlled studies. *Surg Endosc* 2003; 17: 180-9.
17. Kurzer M, Belsham PA, Kark AE: The Lichtenstein repair. *Surg Clin North Am* 1998, 78: 1025-1046.
18. Amid PK, Shulman AG, Lichtenstein IL: Open "Tension-Free" repair of inguinal hernias; The Lichtenstein technique. *Eur J Surg* 1996, 162: 447-453.
19. Goldstein HS: Selecting the right mesh. *Hernia* 1999, 3: 23-26.
20. Shahi K. S, Bhandari G, Bhuvan, Prashant, Sanjeev, Rakesh, Malvika."Inguinal Hernioplasty in Elderly Patients under Local Anesthesia". *Journal of Evolution of Medical and Dental Sciences* May 05 2014; 3(18):4824-4827.
21. Amid PK, Shulman AG, Lichtenstein IL: Simultaneous repair of bilateral inguinal hernias under local anesthesia. *Ann Surg* 1996, 223: 249-252.
22. Capozzi JA, Berkenfield JA, Cheaty JK: Repair of inguinal hernia in the adult with prolene mesh. *Surg Gynecol Obstet* 1988, 167: 124-128.
23. Shulman AG, Amid PK, Lichtenstein IL: A survey of non-expert surgeons using the open tension-free mesh repair for primary inguinal hernias. *Int Surg* 1995, 80: 35-36.

AUTHORS:

1. Rakesh K. Gupta
2. Bhuvan
3. K. S. Shahi
4. Geeta Bhandari
5. Prashant Pandey
6. Malvika Sawai

PARTICULARS OF CONTRIBUTORS:

1. 3rd Year Junior Resident, Department of Surgery, Government Medical College, Haldwani, Nainital, Uttarakhand.
2. Assistant Professor, Department of Surgery, Government Medical College, Haldwani, Nainital, Uttarakhand.
3. Professor, Department of Surgery, Government Medical College, Haldwani, Nainital, Uttarakhand.
4. HOD & Professor, Department of Anaesthesia, Government Medical College, Haldwani, Nainital, Uttarakhand.

5. Assistant Professor, Department of Surgery, Government Medical College, Haldwani, Nainital, Uttarakhand.
6. 2nd Year Junior Resident, Government Medical College, Haldwani, Nainital, Uttarakhand.

NAME ADDRESS EMAIL ID OF THE CORRESPONDING AUTHOR:

Dr. Kedar S. Shahi,
Professor, Department of Surgery,
Government Medical College,
Haldwani, Nainital,
Uttarakhand-263139.
Email: kedar_shahi@rediffmail.com

Date of Submission: 14/10/2014.
Date of Peer Review: 15/10/2014.
Date of Acceptance: 28/11/2014.
Date of Publishing: 02/12/2014.