

## MORPHOLOGICAL EFFECTS OF PESTICIDE - CHLORPYRIFOS ON KIDNEY IN ALBINO RATS

Rekha<sup>1</sup>, Sunanda Raina<sup>2</sup>, Sajad Hamid<sup>3</sup>

### HOW TO CITE THIS ARTICLE:

Rekha, Sunanda Raina, Sajad Hamid. "Morphological effects of pesticide - chlorpyrifos on kidney in albino rats". Journal of Evolution of Medical and Dental Sciences 2013; Vol2, Issue 36, September 9; Page: 6835-6848.

**ABSTRACT: AIM:** Pathological lesions have been widely used as biomarkers for health evaluation of organism exposed to pollutants and can be used as warning symptoms for organism health. There are few reports regarding morphological changes in kidney following pesticide Chlorpyrifos exposure which has prompted us to undertake this study. **MATERIALS AND METHODOLOGY:** The present study was conducted on 45 inbred adult Wistar albino rats of either sex, weighting 145 – 165 gms. These animals were randomly divided into 3 groups A, B, C. Oral Chlorpyrifos was given to the experimental groups B and C in dose of 5 mg/kg body weight and 10 mg/kg body weight respectively. Group A served as control and was left as such. The animals were observed for clinical signs of toxicity and behavioral changes throughout the experimental period. Body weight was recorded at zero day and then at 2 weekly interval for 8 weeks. 3 animals from each group were sacrificed after 1 week, 2<sup>nd</sup> week, 4<sup>th</sup> week, 6<sup>th</sup> week and 8<sup>th</sup> week of initiation of experiment to see the morphological changes in the kidney architecture. **RESULTS:** Gross The animals in group A were active, quick to respond and food intake was normal throughout the experimental period where as the animals of groups B & C showed decreased physical activity, dullness, depression, Piloerection, shivering salivation and lacrimation with more severity in Group C. Body Weight Decrease in weight gain was observed in both experimental groups (B & C) as compared to control group A. A statistically significant decrease in weight gain was observed in Group C after 6<sup>th</sup> and 8<sup>th</sup> week of Chlorpyrifos treatment. Macroscopic Changes Grossly the kidneys of rats in control group showed no significant changes. The kidneys of rats in Group B showed no change in colour and consistency after 1<sup>st</sup>, 2<sup>nd</sup>, and 4<sup>th</sup> weeks of treatment with Chlorpyrifos. However after 6<sup>th</sup> week there was congestion, thickening and adherence of capsule at some places. With increasing dose and duration of treatment with Chlorpyrifos i. e after 8<sup>th</sup> week the kidneys were small in size, shrunken and had irregular contour. In Group C upto 1<sup>st</sup> week of treatment with Chlorpyrifos the kidneys were normal in gross appearance but after 2<sup>nd</sup>, 4<sup>th</sup> and 6<sup>th</sup> weeks the kidneys were grossly congested and friable to touch and the capsule was thickened. After 8 weeks of exposure the kidneys were small in size, shrunken and had irregular contour with thickened outer capsule. Naked eye observations of coronal section of kidney Group A showed clear demarcation of outer cortex and inner medulla. Group B showed no visible change after 1<sup>st</sup> and 2<sup>nd</sup> weeks of treatment. After 4<sup>th</sup> and 6<sup>th</sup> week there was visible haemorrhage at corticomedullary junction ranging from focal to completely obscuring of corticomedullary junction. After 8<sup>th</sup> week there was no demarcation between cortex and medulla and whole of medulla was congested. Group C (10 mg/kg b wt) upto 1<sup>st</sup> week there was no significant visible change in coronal section of kidneys. After 2<sup>nd</sup> and 4<sup>th</sup> weeks there was visible haemorrhage at corticomedullary junction. After 6 weeks of treatment whole of the medulla was congested and after 8 weeks there was no demarcation between cortex and medulla, whole of the coronal section of the kidneys showed dark reddish brown colour due to haemorrhage.

# ORIGINAL ARTICLE

---

**CONCLUSION:** The present study showed that significant morphological changes were caused in the kidneys of rats administered with Chlorpyrifos. These changes were markedly different from the control rats. Hence this study brought into light the renal toxicity induced by Chlorpyrifos which was found to be significant at high dose level.

**KEY WORDS:** Pesticide, kidney, capsule, corticomedullary junction

**INTRODUCTION:** Environmental Pollution, when considered in its broadest context, is a by-product of human activities and its significance is in what ways it affects directly or indirectly the living population. One of the ways of environmental pollution is by chemical pesticides.

The term pesticide covers a wide range of compounds including insecticides, fungicide, Herbicide, rodenticide, plant growth regulators and others(Cope et al., 2004)(1)

Food and agricultural organization (FAO) has defined the term pesticide as : “Any substance or mixture of substances intended for preventing, destroying or controlling any pest including vectors of humans or animal disease, unwanted species of plants or animals causing harm during or otherwise interfering with production, processing storage, transport or marketing of food, agricultural commodities, wood and wood products or animal feed stuffs or substances which may be administered to animals for control of insects, arachnids or other pests in or their bodies. “ (Food and Agricultural organization of United Nations, 2002)(2).

Pesticides have played vital role in controlling agricultural, industrial, home and public health pest worldwide ( Bjarling-Poulsen et al., 2008)(3). However, their use poses animal and human health concerns because of their toxicity, widespread use and release into the environment. According to the World Health Organization, 3 million cases of pesticide poisoning occur every year, resulting in more than 250,000 deaths (Yang and Deng, 2007) (4). Despite this alarming figure, there is currently no global system to track and stem poisoning or diseases associated with pesticide use. The high rate of poisoning may be attributed to a number of reasons, including farmers’ poor knowledge about pesticides and pesticide use, less protection against exposures, little formal education of agricultural workers, minimal understanding of the health risks and, most importantly, inadequate safety warnings on the packages by the manufacturers Gbaruko et al. , 2009(5)

If the credits of pesticides include enhanced economic potential in terms of increased production of food, fiber and amelioration of vector borne diseases, then their debits have resulted in serious health implications to man and his environment.

In spite of undesirable and unwanted effects of pesticides on man, there is sequential rise in production and consumption of pesticides in India during last three decades. Many chemical formulations were synthesized, introduced and widely used in pest control programs. These synthetic chemical pesticides can be structurally classified into the following groups:-

- a. Organochlorine pesticides.
- b. Organophosphate pesticides.
- c. Carbamates.
- d. Synthetic pyrethroids.

(Abdel and Saleh, 1999)(6)

The organophosphate insecticides have superseded the organochlorines owing to their rapid biodegradability and shorter persistence in the environment. The organophosphorus pesticides are among the most widely use insecticides globally and they are readily available commercially for

domestic and industrial purposes. They account for 50% of all insecticides applied worldwide. But as a consequence of their widespread use in agriculture and public health, these insecticides ultimately reach the environment and affect the life there in. Organophosphorus compounds exist in liquid and solid forms and are – Phosphorothioates, Phorodithioates and Phosphates (Tripathi and Srivastava, 2010) (7)

Chlorpyrifos [0, 0-diethyl-o (3, 5, 6-trichloro-2-pyridil) phosphor-thioate] is a member of organophosphate class of pesticides that elicits broad spectrum insecticidal activity against a number of important arthropod pests (Racke, 1993) (8). Chlorpyrifos kills insects upon contact by affecting normal function of nervous system.

Chlorpyrifos is a non-systemic insecticide designed to be effective by direct contact, ingestion and inhalation. Poisoning occurs as a result of agricultural use, accidental exposure, suicide and rarely homicide (Yurumez et al., 2007) (9).

Chlorpyrifos is firstly activated to its active metabolite Chlorpyrifos – oxon by oxidative desulfuration which in turn is responsible for mammalian toxicity through inhibition of cholinesterase (Timchalk et al. ,2002; Betancourt and Carr,2004;Tongbai and Damrongphol, 2011)(10,11,12). Once Cholinesterase has been inactivated, acetylcholine accumulates throughout the nervous system (Latuszynska et al., 1999) (13) Toxicity of pesticide cause adverse effect on many organs like Kidney, Liver, Brain and Blood cell (Bebe and Panemanogalore, 2003) (14). Chlorpyrifos is readily absorbed from gastrointestinal tract. In single dose oral study conducted on Human volunteers Chlorpyrifos was 70% absorbed from gastrointestinal tract (Nolan et al., 1984) (15) and in rats absorption of Chlorpyrifos through Gastrointestinal tract after single dose gavage study ranged from 84-90%. After entering the body of organism Chlorpyrifos is eliminated primarily through kidneys in urine. In rats, following oral intake of Chlorpyrifos, about 90% is removed in urine and 10% is excreted in faeces. Barr et. al. in 2005 (16) reported detectable 3,5,6 trichloropyridil (TCP) a metabolite of Chlorpyrifos in urine of 90% of the approximately 2000 samples collected from US residents (aged 2-59 yrs). The elimination half life for this metabolite (TCP) in humans following oral or dermal exposure was approximately 27 hrs (Nolan et al., 1984) (15).

The mortality rate of organophosphorus poisoning is high and the fatal issue is often related to delay in diagnosis or improper management. Acute treatment includes rapid administration of Atropine, which blocks the muscarinic effects and that of Pralidoxime which reactivates acetylcholine inhibited by organophosphates (Yurumez et al., 2007) (9).

The toxicity of organophosphate (CPF) in mammalian animals has received much attention in the recent years. Kidney, the major detoxification organ for many xenobiotics is frequently susceptible to nephrotoxic effects. Nephrotoxicity is one of the toxic manifestations of Chlorpyrifos after its long term as well as acute exposure.

The structure of the kidney of human beings and that of rats is very similar. So in the present study Albino rat were taken as experimental animal to study the effect of Chlorpyrifos in kidney. Also the unilobar kidney of the rat resembles each lobe of multilobar kidney of human beings. And unit of gross structure of kidney is 'lobe'. Moreover general microscopic structure of Nephron and its disposition within tubules is similar in both humans and rats (Ham and Cormach, 1979) (17).

As a consequence of renal heterogeneity, mechanism of chemically induced injury cannot be explored easily, but can be evaluated by studying morphological changes in different parts

# ORIGINAL ARTICLE

---

constituting renal tissue. Pathological lesions have been widely used as biomarkers for health evaluation of organism exposed to pollutants and can be used as warning symptoms for organism health.

There are few reports regarding morphological changes in kidney following pesticide Chlorpyrifos exposure which has prompted us to undertake this study.

Keeping in view the above facts, present study is designed to evaluate the effect of orally administered Chlorpyrifos at different doses for 2 months on kidney architecture of Albino Rat.

**MATERIALS AND METHODOLOGY:** In the present study, Albino rats served as experimental animals:

**COLLECTION OF ANIMALS:** Healthy Wistar Albino rats, forty five in number of either sex weighing between 145 – 165 mg were taken for the study. The rats were procured from the Central Animal House of Government Medical College, Jammu. The investigation was conducted upon getting clearance from Institutional Animal Ethics Committee (IAEC).

Grouping of Animals

After two weeks of acclimatization, the rats were randomly divided into following groups. Identification number was given to rats of each group.

Groups	Number of Animals	Identification Number
Group A :	Control – 15 Animals	A <sub>1</sub> – A <sub>15</sub>
Group B :	Experimental(15 Animals) Group I	B <sub>1</sub> – B <sub>15</sub>
Group C :	Experimental(15 Animals) Group II	C <sub>1</sub> – C <sub>15</sub>

The animals were group housed (12 hours light / dark cycle) in labeled cages in a room where temperature was maintained at 25<sup>o</sup> ± 2<sup>o</sup>C. The cages were made of solid plastic sides and base and stainless steel grid top. Rice husk was used as bedding material. The animals were fed with standard laboratory feed and water ad-libitum throughout the experimental period. The animals were observed for abnormal physical or behavioral change throughout the experimental period. The study was done from December 2011 to February 2012.

**PESTICIDE DETAILS:** Chemical used for the study was Chlorpyrifos, an Organophosphorus pesticide. It was purchased from the market with Molecular formula C<sub>9</sub> H<sub>11</sub> Cl<sub>3</sub> – NO<sub>3</sub> PS

**EXPERIMENT PROTOCOL:** Experimental animals were given oral Chlorpyrifos using a cannula Group A rats served as control and were left as such. Drug regime in Group A and Group B were as follows:-

Experimental group	Date of Adm. of 1 <sup>st</sup> Dose	Route of Adm.	Duration	Dose
B <sub>1</sub> – B <sub>3</sub>	7/12/2011	Oral	1 Week	5mg/kg

# ORIGINAL ARTICLE

B <sub>4</sub> – B <sub>6</sub>	7/12/2011	Oral	2 Weeks	5mg/kg
B <sub>7</sub> – B <sub>9</sub>	7/12/2011	Oral	4 Weeks	5mg/kg
B <sub>10</sub> – B <sub>12</sub>	7/12/2011	Oral	6 Weeks	5mg/kg
B <sub>13</sub> – B <sub>15</sub>	7/12/2011	Oral	8 Weeks	5mg/kg

**GROUP B (Table 1)**

Experimental group	Date of Adm. of 1 <sup>st</sup> Dose	Route of Adm.	Duration	Dose
C <sub>1</sub> – C <sub>3</sub>	7/12/2011	Oral	1 Week	10mg/kg
C <sub>4</sub> – C <sub>6</sub>	7/12/2011	Oral	2 Weeks	10mg/kg
C <sub>7</sub> – C <sub>9</sub>	7/12/2011	Oral	4 Weeks	10mg/kg
C <sub>10</sub> – C <sub>12</sub>	7/12/2011	Oral	6 Weeks	10mg/kg
C <sub>13</sub> – C <sub>15</sub>	7/12/2011	Oral	8 Weeks	10mg/kg

**GROUP C (Table 2)**

Chlorpyrifos was diluted in distilled water to obtain desired concentration. Fresh dosing solution was made every time.

## Parameters Studied:

**Clinical signs and behavioral activities:** All animals were observed daily for physical or behavioral change throughout the experimental period.

**Body weight:** Live body weight of animals was recorded using electronic weighing machine. 3 animals from each group were weighed at zero day and after every 2 weeks till 8 weeks. Body weight gain was calculated as compared to the zero day weight of the same group. Body weight gain in Chlorpyrifos treated rats were compared for statistical analysis [analysis of variance (ANOVA) and Bonferroni test was applied for comparing two groups- i. e. Control and Chlorpyrifos treated, by using body weight of control rats of respective week]. Animal were anaesthetized by using Diethyl ether. A piece of cotton soaked in ether was placed in desiccators' jar and then the animals to be sacrificed were placed in the jar and lid was closed. 3rats from each of 3 groups were sacrificed after last dose at the end of 1<sup>st</sup> week (14<sup>th</sup> of December 2011), 2<sup>nd</sup> week (21<sup>st</sup> of December 2011), 4<sup>th</sup> week (4<sup>th</sup> of January 2012), 6<sup>th</sup> week (18<sup>th</sup> of January 2012) and 8<sup>th</sup> week (1<sup>st</sup> of February 2012) from the date of initiation of experiment. Sacrificing of animals was followed by dissection a mid-line incision through the skin extending from xiphisternum to pubic symphysis was given with a knife and was extended laterally at its lower end to achieve maximum exposure of abdominal cavity and the kidneys were exposed by displacing intestines. Later each kidney was removed in total and then washed with distilled water. After dissection and removal of kidney following parameters were studied

**Macroscopic Changes:** Kidneys were examined first grossly and later on section of kidney was made in coronal plane.

## RESULTS AND OBSERVATION:

# ORIGINAL ARTICLE

---

## I. Clinical signs and Behavioral activities

### Group A (Control) – 15 rats

The animals of this group served as control and were left as such. The animals in this group were active, quick to respond and the food intake was normal throughout the experimental period i. e. 8 weeks.

### Group B (5 mg/kg body weight Chlorpyrifos) – 15 rats.

This group was given 5 mg/kg body weight Chlorpyrifos orally. The clinical signs observed in this group were characterized by decreased physical activity and dullness as compared to control group in which the animals were seen moving around actively. In group B, the activity decreased with passage of time and the rats grouped together in corner of the cages with dull activity and moved initially on sound and later by being teased by hand. Besides this there was lacrimation, salivation, shivering and Piloerection which was observed as puffing of fur. These signs were observed within half-an hour of giving the oral dose. There was reduced intake of food gradually with passage of time with Chlorpyrifos treatment.

### Group C (10 mg/kg body weight Chlorpyrifos) – 15 rats

This group was given 10 mg/kg body wt of Chlorpyrifos orally. The animals of this group also showed decreased physical activity, dullness, depression, Piloerection, shivering, salivation and lacrimation. The animals in this group were slow to respond even on touch and had reduced intake of food because of decreased appetite. In few experimental animals, brownish yellow staining of hair near anal region was seen which was suggestive of diarrhoea.

## II. Body Weight Analysis.

The daily oral administration of Chlorpyrifos was continued for 2 months and their live body weights were recorded. 3 animals from each group were weighed at zero day and after every 2 weeks till 8 weeks. Mean body weights were calculated as shown in Table-1 Body weight gain was calculated as compared to the zero day weight of the same group. Body weight gain in Chlorpyrifos treated rats was compared for statistical analysis. [Analysis of variance (ANOVA) and Bonferroni test was applied for comparing two groups –control and Chlorpyrifos treated, by using body weight of control rats of respective week.

Groups	Zero day	2 Weeks	4 Weeks	6 Weeks	8 Weeks
A	152.33	166.0	174.33	185.33	198.66
B	155.33	168.0	177.33	182.0	190.0
C	148.33	160.0	166.33	170.0	173.0

(Table-3) Mean Body Weight

Results of body weight gain in Group B

# ORIGINAL ARTICLE

Rats treated with Chlorpyrifos 5 mg/kg have shown a decrease in body weight gain. There was decrease in mean bodyweight gain and percent weight gain after 6<sup>th</sup> and 8<sup>th</sup> weeks of treatment, however it was not statistically significant ( $p > 0.05$ ).

### Results of Body Weight gain in Group C

Rats treated with Chlorpyrifos (10 mg/kg/day) have shown a decrease in mean body weight gain and percent weight gain. A significant decrease in body weight gain recorded after 6<sup>th</sup> ( $P < 0.03$ ) and 8 weeks ( $P < 0.004$ ) Chlorpyrifos treatment.

Group	Zero day	2 Week	4 Weeks	6 Weeks	8 Weeks
Group A(control) Percentage- gain/significance	152.33±1.85 -/-	166±1.52 8.9/-	174.33±0.88 14.4/-	185.3±2.02 21.6/-	198.6±1.76 30.4/-
Group B(5 mg/kg b wt) Percentage - gain/significance	155.33±2.40 -/-	168.0±2.30 8.1/NS	177.33±4.37 14.1/NS	182.0±4.61 17.1/NS	190.0±5.29 22.3/NS
<b>Group C(10mg/kg b wt)</b> Percentage- Gain/significance	148.33±2.20 -/-	160.0±2.64 7.8/NS	166.33±1.45 12.1/NS	170.0±1.145 14.6/ $p < 0.03$	173.0±1.15 16.6/ $p < 0.004$

**Table 4. Body weight (gm) and percent gain of rats orally administered Chlorpyrifos for 8 weeks.**

NS, NOT SIGNIFICANT.

Each value represents mean  $\pm$  s. E. Of three rats; percent gain was calculated comparing with the zero day value of respective group; anova  $-p < 0.05$  was considered as significant; bonferroni test was used for comparing significance between two groups- control and chlorpyrifos (by using body weight of control rats of respective week).

### Group A (Control)

Macroscopic Observations: No gross changes observed

### Group B (5 mg /kg body weight Chlorpyrifos)

Macroscopic Observations: Grossly, the kidney in group B showed no change in shape, colour and consistency after 1<sup>st</sup>, 2<sup>nd</sup> and 4<sup>th</sup> weeks of treatment with Chlorpyrifos. However after 6<sup>th</sup> week of treatment with Chlorpyrifos, the kidney showed congestion and there was thickness of capsule and adhesions at places. 8weeks after treatment with Chlorpyrifos, the kidney was small in size, shrunken and had irregular contour and the outer capsule was thickened.

Coronal section of kidney when viewed with naked eye in Group B, showed clearly visible cortex and medulla after 1<sup>st</sup> week and 2<sup>nd</sup> week of treatment with Chlorpyrifos and respectively.

After 4 weeks, cortex and medullary zones were clearly demarcated but there was focal haemorrhage at corticomedullary junction.

# ORIGINAL ARTICLE

---

Following 6 weeks of treatment with Chlorpyrifos, there was observed congestion at corticomedullary junction and even the base of the medulla was affected by the congestion.

After 8 weeks of treatment whole of the medulla was seen to be congested due to which corticomedullary junction was obscured. Cortex was congested especially along the upper poles.

Group C (10 mg/kg body weight)

Macroscopic Observations: Grossly the kidney in group C was normal in shape, colour and texture after 1<sup>st</sup> week of treatment with Chlorpyrifos however after 2<sup>nd</sup>, 4<sup>th</sup> and 6<sup>th</sup> weeks of Chlorpyrifos exposure the kidneys showed no change in shape, but there was congestion and friability. The outer capsule was thickened and adherent to the Kidney at some places. 8 weeks after Chlorpyrifos treatment the kidneys of the exposed rats were small in size, shrunken and had irregular contour with thickened outer capsule.

Coronal section of kidney when viewed with naked eye was normal after 1<sup>st</sup> week.

After 2<sup>nd</sup> week of treatment with Chlorpyrifos cut section showed a focal band of haemorrhage at corticomedullary junction. Rest of the cortex and medulla were normal in appearance.

After 4 weeks, the cut section of kidney showed dark red-brown granular cortex and pale looking medulla with apex fitting into the minor calyx of the pelvis. But a thick band of haemorrhage was seen to obscure corticomedullary junction.

After 6 weeks of treatment with Chlorpyrifos, red-brown coloured outer cortex was seen and visible haemorrhage was seen in whole of the medulla.

8 weeks after treatment with Chlorpyrifos the cut section of the kidney showed no demarcation between cortex and medulla and whole of it was congested.

These features were suggestive of acute renal failure leading to chronic renal failure.

**DISCUSSION:** Pesticides have been one of the most effective weapons discovered by man to protect agricultural products from the attack of Pests. Among these Chlorpyrifos is an extensively used organophosphate pesticide. Due to its wide-spread use it poses potential harm to non target organisms including humans. Chlorpyrifos exposure leads to extensive structural damage to the kidney. The unusual susceptibility of mammalian kidney to the toxic effects of noxious chemical can be attributed in part to the unique anatomic and physiologic features of this organ. Although the kidneys constitute only 0.5% of total body mass they receive about 20-25% of the resting cardiac output. Consequently any drug or chemical in the systemic circulation will be delivered to these organs in relatively high amounts. The process involved in forming concentrated urine also serves to concentrate potential toxicants into tubular cells. Therefore, a non-toxic concentration of chemical in the plasma may reach toxic concentration in the kidney. Progressive concentration of toxicants along the nephron may result in intraluminal precipitation of relatively insoluble compounds, causing acute renal failure secondary to tubular obstruction. Finally, renal transport, accumulation and metabolism of xenobiotics contribute significantly to the susceptibility of the kidney to toxic injury.

Several studies have supported the fact that major route of excretion of Chlorpyrifos is through kidneys in urine (Nolan R. J et al., 1984, Griffin et al., 1999) (15, 19)

Clinical Signs and Behavioral activities



In the present study, some clinical signs characterized by decreased physical activity, dullness, depression, piloerection, lacrimation, salivation, shivering, diarrhea and loss of appetite were observed with doses of 5mg/kg b wt and 10 mg/kg b wt. Similar results were observed by Lotti et al (1986), Akhtar N et al. (2009) , Kammon et al. (2010), Ambali et al. (2011<sub>a</sub>), Ambali et al. (2011<sub>b</sub>), Issa AM et al (2011), Bhandaniya et al. (2012), Galakatu et al. (2012), Heikal et al. (2012)(20-28). These clinical signs were attributed to cholinergic crisis due to accumulation of acetylcholine (neurotransmitter).

**Body Weight Gain:** In the present study, a decrease in weight gain was observed after 6<sup>th</sup> and 8<sup>th</sup> week, of treatment with Chlorpyrifos in doses of 5 mg/kg b wt and 10 mg/kg b wt for 8 weeks. This decrease in weight gain was statistically significant after 6<sup>th</sup> and 8<sup>th</sup> weeks in Group C (10 mg/kg b wt). This observation is in conformity with observations of Malik et al. (2004) Akhtar et al. (2009) Tripathi and Srivastava (2010) Ambali et al. (2011<sub>a</sub>) Mansour and Mossa (2011) Heikal et al. (2012) Bhandaniya et al. (2012) Galakatu et al. (2012), Mossa & Abbassy (2012)(29,21,7,23,30,28,26,27,31)

### Macroscopic Changes

- (a) Grossly, the kidneys in Chlorpyrifos treated rats in the present work were seen to be congested with increasing dose and duration of treatment. Also there was thickening and adherence of capsule at some places after 6<sup>th</sup> week 8 weeks after treatment with Chlorpyrifos the kidneys were small in size, shrunken and with irregular contour similar facts have been reported by Kumar et al. (2012), Kammon et al. (2010), Bhandaniya et al. (2012) (32, 22, 26)
- (b) Coronal section of kidney, when observed with naked eye revealed clearly distinct 2 zones – outer red-brown cortex and inner lighter medulla after 1<sup>st</sup> and 2<sup>nd</sup> weeks of treatment with Chlorpyrifos (5 mg/kg body weight) in Group-B and after 1<sup>st</sup> week of treatment with Chlorpyrifos in Group-C. As the duration of treatment advanced variable degrees of corticomedullary haemorrhage was observed ranging from focal to complete obscuration of corticomedullary junction. In Group-C, after 8 weeks of treatment with Chlorpyrifos there was no demarcation between cortex and medulla and whole of the section was congested (giving dark red-brown appearance). Similar facts have been given by Kumar et al. (2012) (32). The present study showed variable intensities of changes, depending upon dose and duration of treatment and these changes were significantly different from those of control rats.

**SUMMARY AND CONCLUSION:** The present study is based upon the observations made on 45 albino Wistar rats weighing 145-165 gms to determine the effect of Chlorpyrifos on histomorphology of kidneys of these animals. The animals were group housed (12 hr light/dark cycle) with ad-libitum access to food and water. They were divided into 3 groups A, B and C with 15 animals each. Group A served as control group, Group B were daily administered Chlorpyrifos at a dose of 5 mg/kg b wt and animals in Group C received daily an oral dose of 10 mg/kg b wt Chlorpyrifos. All the animals were observed for ½ an hour after giving the dose and also throughout the experimental period. 3 animals from each group were weighed at 2 weekly intervals for 8 weeks and weight gain was evaluated in each group. Rats were sacrificed on 1<sup>st</sup>, 2<sup>nd</sup>, 4<sup>th</sup>, 6<sup>th</sup> and 8<sup>th</sup> week after initiation of the experiment. Kidneys were removed after dissection, examined grossly and also after making coronal section.

## Gross Observations

Clinical signs and Behavioral activities –

Group A (Control)

The animals in this group were active, quick to respond and food intake was normal throughout the experimental period.

Group B & C

The animals of these groups showed decreased physical activity, dullness, depression, piloerection, shivering, salivation and lacrimation. Though severity of these signs were more in Group C. Both groups showed decreased food intake with passage of time. Few of the animals in Group C also had diarrhoea.

Body Weight: Decrease in weight gain was observed in both experimental groups (Group – B & C) as compared to control group A. A statistically significant decrease in weight gain was observed in Group C after 6<sup>th</sup> and 8<sup>th</sup> week of Chlorpyrifos treatment.

## Macroscopic Changes

Grossly the kidneys of rats in control group showed no significant changes.

The kidneys of rats in Group B showed no change in colour and consistency after 1<sup>st</sup>, 2<sup>nd</sup>, and 4<sup>th</sup> weeks of treatment with Chlorpyrifos. However after 6<sup>th</sup> week there was congestion, thickening and adherence of capsule at some places. With increasing dose and duration of treatment with Chlorpyrifos i. e after 8<sup>th</sup> week the kidneys were small in size, shrunken and had irregular contour.

In Group C upto 1<sup>st</sup> week of treatment with Chlorpyrifos the kidneys of exposed rats were normal in gross appearance but after 2<sup>nd</sup>, 4<sup>th</sup> and 6<sup>th</sup> weeks the kidneys were grossly congested and friable to touch and the capsule was thickened. After 8 weeks of exposure the kidneys were small in size, shrunken and had irregular contour with thickened outer capsule.

## Naked eye observations of coronal section of kidney

Group A (control) showed clear demarcation of outer cortex and inner medulla.

Group B (5 mg/kg b wt Chlorpyrifos) showed no visible change after 1<sup>st</sup> and 2<sup>nd</sup> weeks of treatment. After 4<sup>th</sup> and 6<sup>th</sup> week there was visible haemorrhage at corticomedullary junction ranging from focal to completely obscuring of corticomedullary junction. After 8<sup>th</sup> week there was no demarcation between cortex and medulla and whole of medulla was congested.

Group C (10 mg/kg b wt) upto 1<sup>st</sup> week there was no significant visible change in coronal section of kidneys. After 2<sup>nd</sup> and 4<sup>th</sup> weeks there was visible haemorrhage at corticomedullary junction which was obscuring it. After 6 weeks of treatment whole of the medulla was congested and after 8 weeks there was no demarcation between cortex and medulla, whole of the coronal section of the kidneys showed dark reddish brown colour due to haemorrhage.

These changes were markedly different from the control rats. All these changes leading to acute renal failure progressing to chronic renal failure with increasing duration. Hence this study brought into light the renal toxicity induced by Chlorpyrifos which was found to be significant at high dose level.

# ORIGINAL ARTICLE

---

## REFERENCES:

1. Cope WG, Leidy RB and Hodgson E (2004): Classes of toxicants: use classes. In: "Textbook of Modern Toxicology." 3rd Edition, John Wiley and Sons, Inc., New Jersey: 58-70.
2. Food and Agricultural Organization of United Nations: International Code of Conduct on distribution and use of pesticide (2002). Retrieved on 2007-10-25.
3. Bjorling- Poulsen M, Andersen HR and Grandjean P (2008): Potential developmental neurotoxicity of pesticides used in Europe. *Env. Health*; 7(50): 1-23.
4. Yang C and Deng J (2007): Intermediate syndrome following organophosphate insecticide poisoning. *J. Chi. Med. Ass.* ; 70(11):467-472.
5. Gbaruko BC, Ogwo EI, Igwe JC and Yu H (2009): Organophosphate induced chronic neurotoxicity: Health, environmental and risk exposure issues in developing nations of the world. *Afr. J. Biotech.* ; 8(20): 5137-5141
6. Abdel-Mageed and T. Saleh (1999): Effect of the organophosphate insecticide, Sumithion (fenitrothion) on albino rats. *Saudi J. Bio. Sci.* ; 6(2):179-186
7. Tripathi S and Srivastav AK (2010): Nephrotoxicity induced by long-term oral administration of different doses of Chlorpyrifos. *Toxicol Ind Health*; 26 (7): 439-47.
8. Racke KD (1993): Environmental fate of Chlorpyrifos. *Reviews of Environmental Contamination and Toxicology*; 131: 1-150.
9. Yurumez Y, Ikekeizceli I, Sozuer CM, Soyuer I and Yavuz Y (2007): Effect of interleukin-10 on Tissue Damage caused by organophosphate poisoning. *Basic and clinical pharmacology and toxicology*; 100: 323-327.
10. Timchalk C, Nolan RJ, Mendrala AL, Dittenber DA, Brzak KA and Mattson JL (2002): A physiologically based pharmacokinetic and pharmacodynamic (PBPK/PD) model for the organophosphate insecticide Chlorpyrifos in rats and humans. *Tox. Sci.*; 66: 34-53.
11. Betancourt AM and Carr R (2004): The effect of Chlorpyrifos and Chlorpyrifos-oxon on brain cholinesterase, muscarinic receptor binding, and neurotrophin levels in rats following early postnatal exposure. *Toxicological Sciences*; 77(1): 63-71.
12. Tongbai W and Damrongphol P (2011): Bioactivation of Chlorpyrifos in the Rice land and Prawn, *Macrobrachium lanchesteri*. *Journal of Biological Sciences*; 11(3): 275-278.
13. Latuszynska J, Luty S, Halliop J, Przylepa E, Tochman A, Obuchowska D and Korezak E (1999): Studies of Toxicity of Dermally-absorbed Nurelle-D550 EC preparations. *Ann Agric environ Med*; 6:151-159.
14. Bebe FN and Panemanogalore M (2003): Exposure of low doses of endosulfan and Chlorpyrifos modifies endogenous antioxidants in tissues of rats. *J. Environ. Sci. Health.* ; 38(3): 349-363.
15. Nolan RJ, Rick DL, Freshour NL and Saunders JH (1984): Chlorpyrifos: Pharmacokinetics in Human Volunteers. *Toxicol. Appl. Pharmacol.* ; 73: 8-15.
16. Barr D, Allen R, Olsson AO, Bravo R, Caltabiano RM and Montesano A (2005): Concentrations of selective metabolites of organophosphorus pesticides in the United States population. *Environmental Research*;99(3): 314-326
17. Ham AW and Cormach DH (1979): "Text book of histology". JB Lippincott Company. 8<sup>th</sup> edition: 755-773.

18. Drury RAB and Wallington EA (1967): "Carleton's histological techniques". Oxford University Press, 4<sup>th</sup> edition -129
19. Griffin P, Mason H, Heywood K and Cocker J (1999): Oral and dermal absorption of Chlorpyrifos: A human volunteer study. *Occup. Environ. Med.* ; 56 (1), 10-13
20. Lotti M, Moretto A, Zoppellari R, Dainese R, Rizzuto N and Barusco G (1986): Inhibition of lymphocytic neuropathy target esterase predicts the development of organophosphate-induced delayed polyneuropathy. *Arch. Toxicol.* ; 59 (3): 176-9.
21. Akhtar N, Srivastava MK and Raizada RB (2009): Assessment of Chlorpyrifos toxicity on certain organs in rat, *Rattus norvegicus*. *Journal of Environmental Biology*; 30(6): 1047-1053.
22. Kammon AM, Brar R S, Banga H S and Sodhi S (2010): Patho-biochemical studies on hepatotoxicity and nephrotoxicity on exposure to Chlorpyrifos and Imidacloprid in layer chickens. *Veterinarski Archiv*; 80(5): 663-672.
23. Ambali SF, Angani M, Adole AO, Kawu MU, Shittu M, Akande MG and Oladipo OO (2011<sub>b</sub>) : Protective effect of vitamin C on biochemical alterations induced by subchronic co-administration of Chlorpyrifos and lead in Wistar rats. *Journal Environment Analytic Toxicol.* ;1(3):108
24. Ambali SF, Akanbi DO, Oladipo OO, Yaqub LS and Kawu MU (2011<sub>a</sub>): Subchronic Chlorpyrifos-Induced Clinical, Hematological and Biochemical changes in Swiss albino Mice: Protective effect of Vitamin E. *Int. J Bio Medical Res.* ; 2(2): 497-503
25. Issa AM, Gawish AM and Esmail GM (2011): Histological Hazards of Chlorpyrifos usage on gills and kidneys of Nile tilapia and the role of Vitamin E supplement in Egypt. *Life Science Journal*; 8(4): 113-123.
26. Bhandaniya AR, Joshi DV, Patel BJVA, Padodara RJ and Savasani HH (2012): Toxicopathological studies on experimentally induced Acephate toxicity in Wistar rats (*Rattus norvegicus*). *Wayamba Journal of Animal Science*; ISSN: 2012-578X; 2012
27. Galakatu SS, Joshi DV, Patel BJ, Balani JK, Mohammad N and Kher AC (2012): Toxicopathological Studies on induced Chlorpyrifos toxicity in Wistar rats (*Rattus norvegicus*). *An international e Journal*; 1(2). [www.arkgroup.co.in](http://www.arkgroup.co.in)
28. Heikal TM, Mossa ATH, Marci GI and Rasoul MA (2012): Cyromazine and Chlorpyrifos induced Renal Toxicity in Rats: The Ameliorating affects of Green tea Extract. *Environmental Analytical Toxicology*; 2(5): 146.
29. Malik G, Dahiya JP and Gera S (2004): Biochemical studies on Chlorpyrifos toxicity in broiler chicken. *Indian Journal of Animal Sciences*; 74(5): 473-476.
30. Mansour SA and Mossa AH (2011): Adverse effects of exposure to low doses of Chlorpyrifos in lactating rats. *Toxicol Ind Health*; 27 (3): p 213-214.
31. Mossa and Abbassy (2012): Adverse hematological and Biochemical effects of certain Formulated insecticide in male rats. *Research Journal of Environment Toxicol*; 6: 160-168.
32. Kumar V, Abbas AK, Fauston N, Mithchell RN (2012): "Text book of Robbins basic pathology", 8<sup>th</sup> edition. Published by Elsevier, a division of Reed and Elsevier India private ltd: 559-567

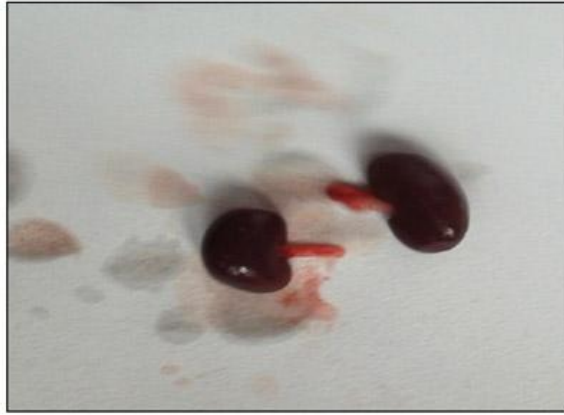

Fig-1: Gross structure of the kidney seen in control group

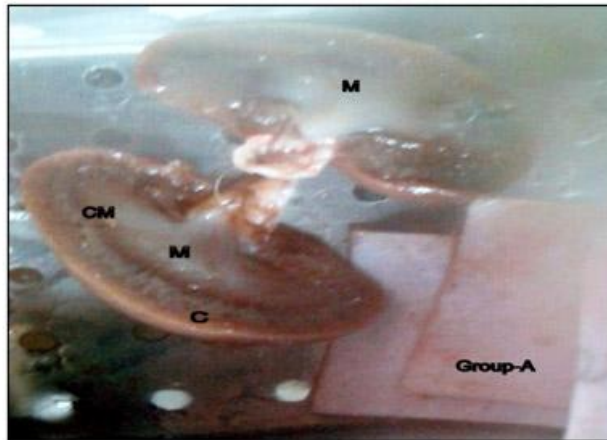


Fig-2: Coronal section group A (control) showing outer cortex (C) and inner medulla (M)

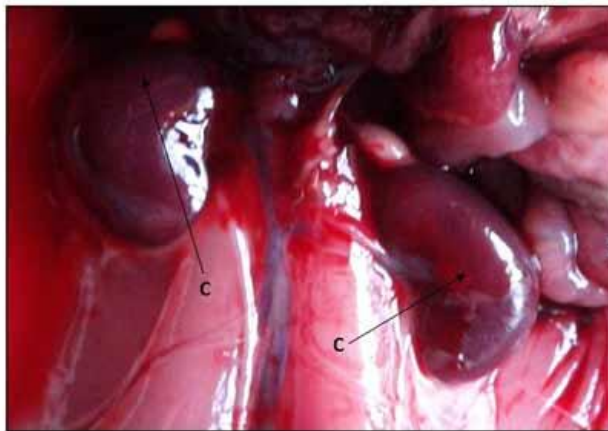


Fig-3: Grossly congested Kidney with thickened capsule (C) in Group-C

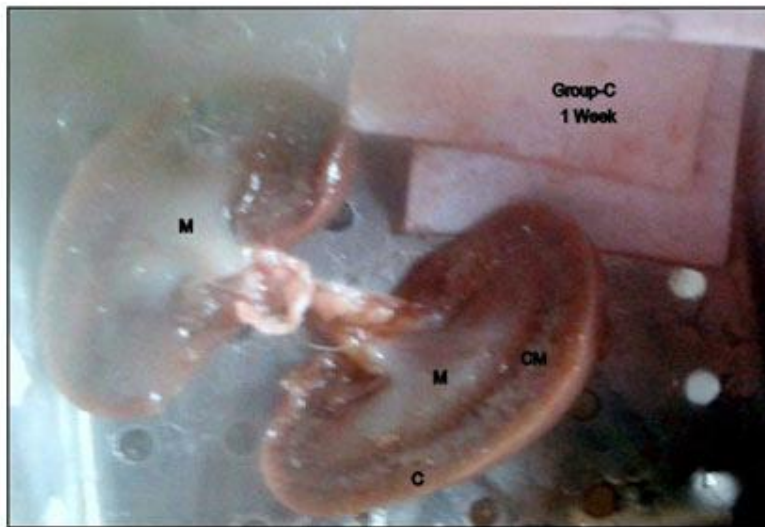


Fig-4: Coronal section group C (1 week) showing outer cortex (C) and inner medulla (M)

#### **AUTHORS:**

1. Rekha
2. Sunanda Raina
3. Sajad Hamid

#### **PARTICULARS OF CONTRIBUTORS:**

1. PG Scholar, Department of Anatomy, Government Medical College, Jammu.
2. Professor and Head, Department of Anatomy, Government Medical College, Jammu.
3. Lecturer, Department of Anatomy, SKIMS Medical College, Bemina, Srinagar

#### **NAME ADDRESS EMAIL ID OF THE CORRESPONDING AUTHOR:**

Dr. Sajad Hamid,  
Dept. of Anatomy,  
SKIMS Medical College, BEMINA.  
Email – drsajadk@rediffmail.com

Date of Submission: 22/08/2013.  
Date of Peer Review: 23/08/2013.  
Date of Acceptance: 30/08/2013.  
Date of Publishing: 03/09/2013