A DESCRIPTIVE STUDY ON OVARIAN MASSES IN ADOLESCENTS IN MCH, KOTTAYAM

Ranimol V. V[1], Deepa Mathews[2], M. A. Kunjamma[3]

[1]Junior Resident, Department of Obstetrics and Gynaecology, Government Medical College, Kottayam.
[2]Associate Professor, Department of Obstetrics and Gynaecology, Government Medical College, Kottayam.
[3]Professor and HOD, Department of Obstetrics and Gynaecology, Government Medical College, Kottayam.

ABSTRACT

BACKGROUND

It is recommended that greater use of imaging of the pelvis and tumour markers preoperatively is essential for evaluation of adolescent ovarian masses. There should be greater use of conservative expectant management or ovarian-sparing surgery in view of the low risk of malignancy in adolescent age group. The practice of removing ovaries for benign cysts may be overcome by appointing more gynaecologists with advanced training skills training in paediatric and adolescent gynaecology.

The objectives of the study are-

1. To study the age related proportion, clinical and sonographic morphology of various ovarian masses in adolescence.
2. To correlate clinical, sonographic with Doppler velocimetry, tumour marker status, operative findings and the histopathology.
3. To identify the role of preoperative sonographic evaluation in deciding on the management.
4. To study the role of sonography in morphologic characterisation of benign versus malignant tumours of ovary and the extent to which it has influenced the management.

MATERIALS AND METHODS

The study which is an observational case series study was conducted in the Department of Obstetrics and Gynaecology, Government Medical College, Kottayam, during the period from January 2011 - June 2014. The age, sex and IP no. of adolescents of age 10 - 19 yrs. presenting at OPD and casualty with sonological evidence of ovarian masses are noted. If found with suspicious features, then only tumour markers and Doppler velocimetry are mentioned. The conservative or surgical managements done for them are recorded. If surgically managed, HPR are collected and analysed.

RESULTS

A total of 46 patients were included in the study. More number of cases fall in the age group of 17 - 19 yrs. and the most common presenting complaint was pain abdomen. 50% of the study group has a mass abdomen. Majority are benign masses and the commonest type was serous cystadenoma, which appear as simple cystic in USG. 87% of the solid and cystic masses in sonography came out as malignancy. Multiloculated cyst in USG turned out to be teratoma (60%) and mucinous type (30%). Only 50% of dermoid cyst correlated with ultrasound. Doppler was done in 33.3% of malignancies and was abnormal. Only 66.7% of abnormal results of tumour markers depicted malignancies. The intraoperative and pathological report correlate most in endometriotic cyst and yolk sac tumour (50%) and least with serous tumours (20%). 54.3% of them were benign epithelial tumours. All malignant tumours were germ cell tumours. Yolk sac tumours and mucinous tumours were distributed in early adolescence and teratoma and serous in late period.

CONCLUSION

Sonography is a simple, quick and non-invasive investigation found to be most accurate among the other tests for accounting the type of tumours. Most common histologic type in my study is serous cystadenoma. Clinical examination can clinch the diagnosis only to some extent in this age group.

KEYWORDS

Adolescence, Ovarian Tumours, Sonography, Tumour Markers, Doppler, Histopathology.

HOW TO CITE THIS ARTICLE: Ranimol VV, Mathews D, Kunjamma MA. A descriptive study on ovarian masses in adolescents in MCH, Kottayam. J. Evolution Med. Dent. Sci. 2017;6(93):6777-6784, DOI: 10. 14260/jemds/2017/1467

BACKGROUND

Adolescence is the period of development between the onset of puberty and adulthood. It is marked by the appearance of secondary sex characteristics, ends with the completion of physical growth and emotional maturity and usually spans from 10 to 19 years of age.

The ovaries can harbour an incredibly wide variety of enlargements and neoplasms, which are extremely heterogeneous in morphology and histology. Malignant ovarian masses are uncommon in this age group with only 6.5% being them. The objective of this study was to assess the surgical management of adolescent ovarian masses at Government Medical College, Kottayam from 2011 to 2014, to assess if practice could be improved.

One way to reduce the number of surgical interventions could be by using ultrasonography. When we use ultrasound to exclude malignancy, it is important to determine the correlation of sonographic appearance with macroscopic and microscopic findings. This helps in deciding on conservative or other interventional methods.

'Financial or Other Competing Interest': None.
Submission 28-01-2017, Peer Review 19-11-2017,
Acceptance 27-11-2017, Published 11-12-2017.
Corresponding Author:
Dr. Ranimol V. V,
Vijayabhavanam, Clappana P. O.,
Vallickavu, Kollam-690525.
E-mail: ranimolvv@gmail.com
DOI: 10. 14260/jemds/2017/1467

Transvaginal sonography offers a better resolution with high frequency, 90% of all ovarian tumours are benign. Functional cysts are common in young age group indicating normal ovarian activity. They are mostly unilocular. 80% of ovarian neoplasms arise from primitive epithelium of the mesothelial lining of the peritoneal cavity. 80% of tumours are cystic, especially serous and mucinous cystadenomas, usually thin walled and uni or multilocular. Benign teratomas show a complex appearance by scan. Malignant tumours show definite solid areas like papillary projections and areas of necrosis. Also, depending upon the percentage of echogenic structures in the tumour, ultrasound can characterise them into benign and malignant tumours, but not 100% specific.

One way of tumour characterisation is using the scoring system, correlating preoperative endovaginal ultrasound image with surgical or histopathologic findings.

They include-

1. Inner wall structure.
2. Wall thickness.
3. Septal thickness.
4. Echogenicity.

Another way is to classify malignant tumours based on macroscopic characterisation by pathologist and comparing this with ultrasound image to classify them into unilocular including borderline malignant, unilocular solid, multilocular and multilocular solid and solid tumours.

Knowledge from this data was applied prospectively with TVS results and surgical and histologic study. It was found sensitivity to identify benign and malignant tumours was 90% sensitive and 87% specific. Endovaginal sonographic characterisation of ovarian tumours correctly correlated with macroscopic examination in 96% of cases.

Various diagnostic methods employed are clinical examination, sonography, laparoscopy, cul-de-sac aspiration, immunologic methods, CT and MRI. Compared with laparotomy, laparoscopy is associated with less bleeding, adhesions and postoperative pain, faster recovery and a better cosmetic result. These benefits are even more valuable in an adolescent population. Faster recovery allows patients to return to their schooling, while less adhesions formation may reduce future fertility issues.

The study of adolescents aged 10 - 19 years admitted with ovarian tumours during a 3-year period revealed that 6.5% had malignant ovarian tumours with germ cell tumours being most frequent. The high incidence of malignancy was due to our hospital being a referral centre. Tumour markers were found useful in diagnosing germ cell tumour. Amongst the malignant ovarian tumours, the best prognosis was noted with dysgerminomas. Optimal surgery at initial laparotomy followed by adjuvant chemotherapy or radiotherapy were found to offer the best chance of cure. Another serious long-term side effect of radiation or chemotherapy treatment that affects the quality of life is depletion of the follicular pool in the ovaries causing loss of ovarian steroid secretion, absent menarche and/or premature ovarian failure (POF) and infertility. In consideration of these various aspects on diagnosis of early ovarian cancers, I discussed the current strategy of evaluation and prognostication of ovarian enlargements and this study form the basis of my thesis.

Objectives

1. To study the age related proportion, clinical and sonographic morphology of various ovarian masses in adolescence.
2. To correlate clinical, sonographic with Doppler velocimetry, tumour marker status, operative findings and the histopathology.
3. To identify the role of preoperative sonographic evaluation in deciding on the management.
4. To study the role of sonography in morphologic characterisation of benign versus malignant tumours of ovary and the extent to which it has influenced the management.

MATERIALS AND METHODS

Design

Observational case series (Retrospective study).

Setting

Department of Obstetrics and Gynaecology, MCH, Kottayam.

Period

3 years (Jan 2011 - June 2014).

Population

Adolescents of 10 - 19 years presented at my study setting.

Statistical Analysis

Data will be analysed by Excel and SPSS 16. The proportion of types of ovarian tumour can be assessed.

Inclusion Criteria

Adolescent females of age 10 - 19 years with adnexal masses.

Exclusion Criteria

Polycystic ovarian syndrome.

Limitations of Study

1. As the study population includes only adolescents admitted in our hospital, the prevalence of type in general population cannot be assessed.
2. The data of those who are discharged against medical advice cannot be ascertained.
3. Data of OP cases under follow-up are not included in this study.

RESULTS

This is a retrospective study carried out in the Department of Obstetrics and Gynaecology, Government Medical College, Kottayam, during the period from January 2011 to June 2014 on adolescent girls of 10 - 19 years presenting at OPD or casualty with sonologic evidence of ovarian masses.

Age	No.	Percent
11-13	9	19. 6
14-16	14	30. 4
17-19	20	43. 5
20	3	6. 5
Total	**46**	**100. 0**

Table 1. Age Distribution

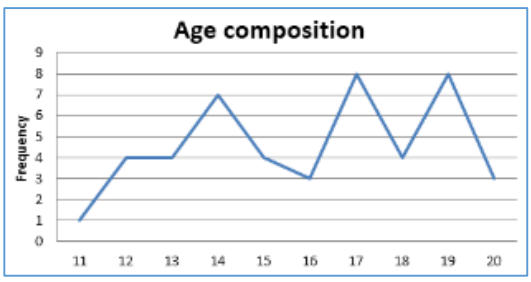

Figure 1. Age Distribution

In this study, it has been found that the ovarian tumours occur most commonly in the age group > 17 yrs.

Menarche	No.	Percent
No	1	2. 2
Yes	45	97. 8
Total	**46**	**100. 0**

Table 2. Menarchal Status

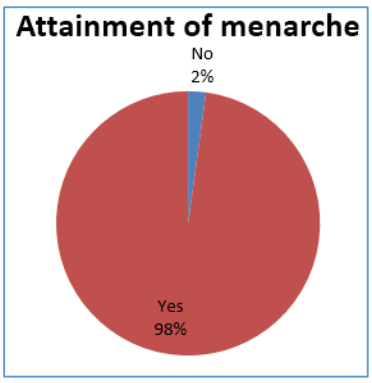

Figure 2. Menarchal Status

Crosstab						
Presenting Complaints	**Abdominal Examination**				**Total**	
	Mass Abdomen		**NAD**			
	No.	**%**	**No.**	**%**	**No.**	**%**
Abdominal distension	7	30. 4	1	4. 3	8	17. 4
Acute abdomen	4	17. 4	4	17. 4	8	17. 4
Incidental finding	0	0. 0	1	4. 3	1	2. 2
Menstrual symptoms	1	4. 3	0	0. 0	1	2. 2
Pain abdomen	11	47. 8	17	73. 9	28	60. 9
Total	**23**	**100. 0**	**23**	**100. 0**	**46**	**100. 0**

Table 3. Abdominal Finding

Chi-square= 7.8, p= .100 (NS)

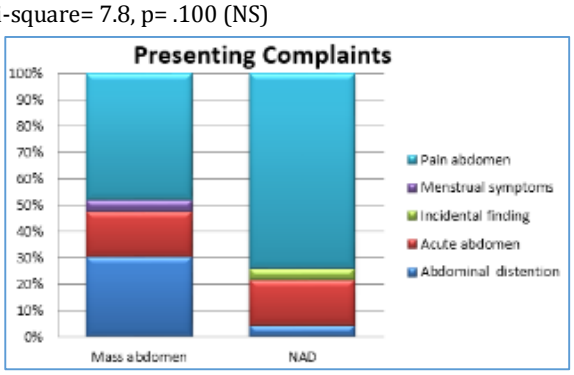

Figure 3. Abdominal Finding

Crosstab						
Presenting Complaint	**Vaginal/ Rectal Exam**				**Total**	
	Adnexal Mass		**NAD**			
	No.	**%**	**No.**	**%**	**No.**	**%**
Abdominal distension	8	22. 9	0	0. 0	8	17. 4
Acute abdomen	8	22. 9	0	0. 0	8	17. 4
Incidental finding	0	0. 0	1	9. 1	1	2. 2
Menstrual symptoms	1	2. 9	0	0. 0	1	2. 2
Pain abdomen	18	51. 4	10	90. 9	28	60. 9
Total	**35**	**100. 0**	**11**	**100. 0**	**46**	**100. 0**

Table 4. Examination Finding

Chi-square= 10.7, p= .031

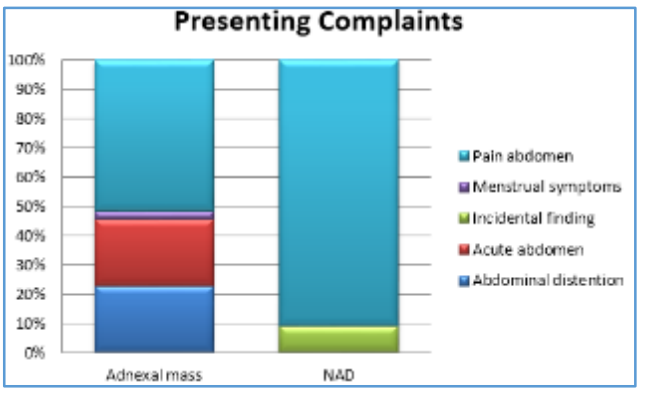

Figure 4. Examination Finding

Most common presenting complaint was abdominal pain. But only 11% of them had a clinically palpable mass.

Doppler	No.	Percent
Normal	15	32. 6
Abnormal	1	2. 2
Not done	30	65. 2
Total	**46**	**100. 0**

Table 5. Doppler Study

Tumour Marker	No.	Percent
Normal	24	52. 2
Abnormal	5	10. 9
Not done	17	37. 0
Total	**46**	**100. 0**

Table 6. Tumour Marker Status

HPR	No.	Percent
Endometriotic cyst	3	6. 5
Functional cyst	2	4. 3
Mature cystic teratoma	6	13. 0
Mucinous cystadenoma	10	21. 7
Not applicable	7	15. 2
Serous cystadenoma	15	32. 6
Yolk sac tumour	3	6. 5
Total	**46**	**100. 0**

Table 7. HPR

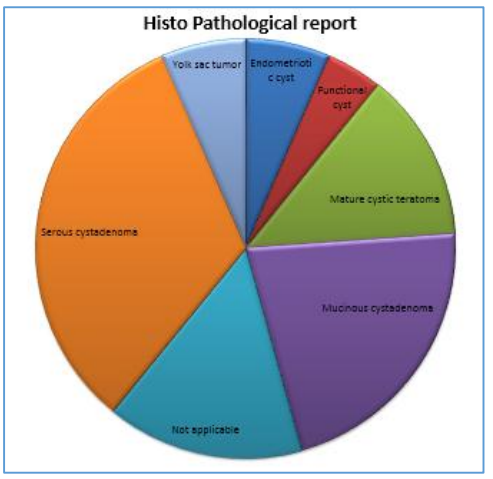

Figure 5. HPR

Majority of tumours encountered in this age group were epithelial tumours (54.3%). This has found that 93.4% of the total cases obtained a benign histopathological report and 6.5% cases had the malignancies. Among the malignancies all were primary ovarian and were germ cell tumours, out of which two-third were stage-IC (5-year survival rate 54% - 90%).

Among the total cases, Serous cystadenoma constitute 32.6% and Mucinous cystadenoma 21.7% respectively.

HPR	Doppler						Total	
	Normal		Abnormal		Not Done			
	No.	%	No.	%	No.	%	No.	%
Endometriotic cyst	0	0. 0	0	0. 0	3	100. 0	3	100. 0
Functional cyst	0	0. 0	0	0. 0	2	100. 0	2	100. 0
Mature cystic teratoma	4	66. 7	0	0. 0	2	33. 3	6	100. 0
Mucinous cystadenoma	3	30. 0	0	0. 0	7	70. 0	10	100. 0
Not applicable	3	42. 9	0	0. 0	4	57. 1	7	100. 0
Serous cystadenoma	5	33. 3	0	0. 0	10	66. 7	15	100. 0
Yolk sac tumour	0	0. 0	1	33. 3	2	66. 7	3	100. 0
Total	15	32. 6	1	2. 2	30	65. 2	46	100. 0

Table 8. HPR and Doppler

Chi-square= 21.3, p= .046

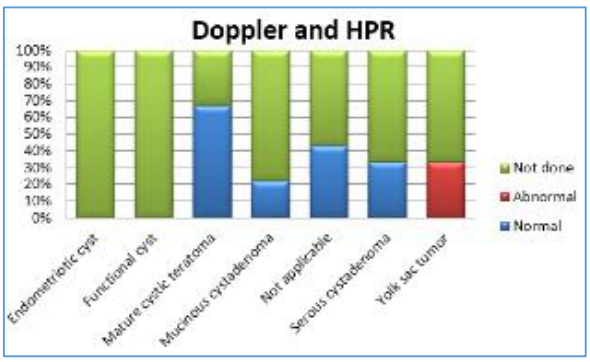

Figure 6. HPR and Doppler

Doppler study was done only in 34.8% of total cases and in 33.3% of proven malignancies. Doppler velocimetry was evidently significant, as it turned to be abnormal in 100% of malignancies.

Among the 63.1% of the Total Cases, in which tumour marker study was done, only 66% of abnormal values turned out to be malignancies (Yolk Sac Tumour)	Sonography																Total	
	Cyst with Internal Echoes		Dermoid Cyst		Haemorrhagic Cyst		Mucinous Cyst		Multiloculated Cyst		Unilocular Mucinous Cyst		Simple Cyst		Solid and Cystic Mass			
	No.	%	No.	%	No.	%	No.	%	No.	%	No.	%	No.	%	No.	%	No.	%
Endometriotic cyst	1	33. 3	0	0. 0	0	0. 0	0	0. 0	0	0. 0	0	0. 0	2	66. 7	0	0. 0	3	100. 0
Functional cyst	0	0. 0	0	0. 0	0	0. 0	0	0. 0	0	0. 0	0	0. 0	2	100. 0	0	0. 0	2	100. 0
Mature cystic teratoma	0	0. 0	3	50. 0	0	0. 0	0	0. 0	3	50. 0	0	0. 0	0	0. 0	0	0. 0	6	100. 0
Mucinous cystadenoma	1	10. 0	0	0. 0	0	0. 0	0	0. 0	3	30. 0	1	10. 0	5	50. 0	0	0. 0	10	100. 0
Not applicable	0	0. 0	0	0. 0	1	14. 3	0	0. 0	0	0. 0	0	0. 0	6	85. 7	0	0. 0	7	100. 0
Serous cystadenoma	2	13. 3	0	0. 0	0	0. 0	1	6. 7	2	13. 3	0	0. 0	8	53. 3	2	13. 3	15	100. 0
Yolk sac tumour	0	0. 0	0	0. 0	0	0. 0	0	0. 0	0	0. 0	0	0. 0	0	0. 0	3	100. 0	3	100. 0
Total	**4**	**8. 7**	**3**	**6. 5**	**1**	**2. 2**	**1**	**2. 2**	**8**	**17. 4**	**1**	**2. 2**	**23**	**50. 0**	**5**	**10. 9**	**46**	**100. 0**

Table 9. HPR and Sonology

Chi-square=75.2, p= .001

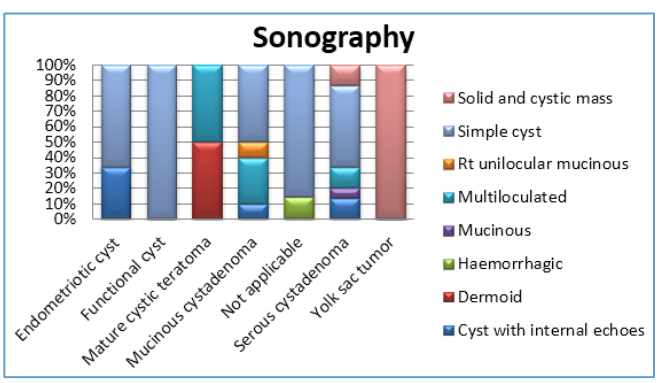

Figure 7. Sonography

Sonographically, 100% of functional cysts and 66.7% of endometriotic cyst appeared as simple cysts. By imaging, only 50% of the teratomas correlated with the pathological report. 50% of the mucinous tumours and 53.3% of the serous tumours showed the features of simple cyst on ultrasound scanning. However, 100% of malignancies showed suspicious features with solid areas on ultrasound and are diagnostic.

HPR	Intraop Finding																		Total	
	Dermoid Cyst		Endo-metriotic Cyst		Haemo-rrhagic Cyst		Mucinous Cyst		Not Applicable		Ovarian Cyst Torsion		Ovarian Torsion		Serous Cyst		Solid and Cystic Tumour			
	No.	%	No.	%	No.	%	No.	%	No.	%	No.	%	No.	%	No.	%	No.	%	No.	%
Endometriotic cyst	0	0.0	3	100.0	0	0.0	0	0.0	0	0.0	0	0.0	0	0.0	0	0.0	0	0.0	3	100.0
Functional cyst	0	0.0	0	0.0	1	50.0	0	0.0	0	0.0	0	0.0	0	0.0	1	50.0	0	0.0	2	100.0
Mature cystic teratoma	6	100.0	0	0.0	0	0.0	0	0.0	0	0.0	0	0.0	0	0.0	0	0.0	0	0.0	6	100.0
Mucinous cystadenoma	0	0.0	0	0.0	1	10.0	7	70.0	0	0.0	1	10.0	0	0.0	0	0.0	1	10.0	10	100.0
Not applicable	0	0.0	0	0.0	0	0.0	0	0.0	7	100.0	0	0.0	0	0.0	0	0.0	0	0.0	7	100.0
Serous cystadenoma	0	0.0	0	0.0	0	0.0	1	6.7	0	0.0	5	33.3	2	13.3	6	40.0	1	6.7	15	100.0
Yolk sac tumour	0	0.0	0	0.0	0	0.0	0	0.0	0	0.0	0	0.0	0	0.0	0	0.0	3	100.0	3	100.0
Total	**6**	**13.0**	**3**	**6.5**	**2**	**4.3**	**8**	**17.4**	**7**	**15.2**	**6**	**13.0**	**2**	**4.3**	**7**	**15.2**	**5**	**10.9**	**46**	**100.0**

Table 10. HPR and Intraop Finding

Chi-square= 202.2, p= .000

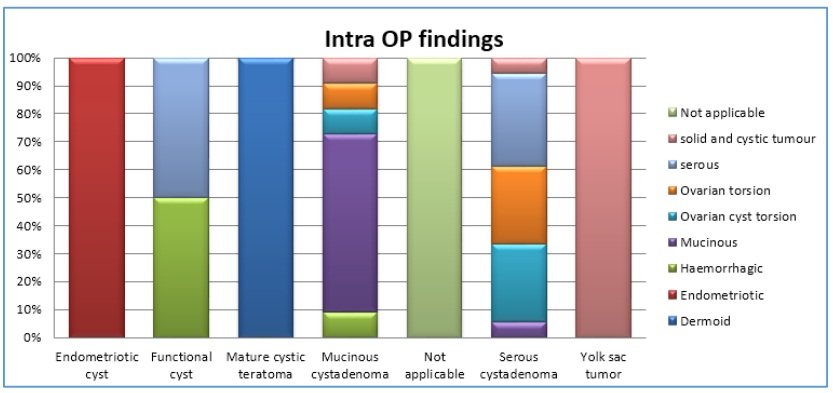

Figure 8. Intraop Finding

Intraoperatively, 50% of the endometriotic cyst, 40% of teratoma and mucinous tumours, 50% of yolk sac tumours and 20% of serous tumours correlated with pathological report.

HPR *Age (Years) Cross Tabulation										
HPR	Age (Years)								Total	
	11-13		14-16		17-19		20			
	No.	%	No.	%	No.	%	No.	%	No.	%
Endometriotic cyst	0	0.0	0	0.0	3	15.0	0	0.0	3	6.5
Functional cyst	0	0.0	1	7.1	0	0.0	1	33.3	2	4.3
Mature cystic teratoma	1	11.1	1	7.1	3	15.0	1	33.3	6	13.0
Mucinous cystadenoma	4	44.4	3	21.4	3	15.0	0	0.0	10	21.7
Not applicable	2	22.2	2	14.3	3	15.0	0	0.0	7	15.2
Serous cystadenoma	1	11.1	6	42.9	7	35.0	1	33.3	15	32.6
Yolk sac tumour	1	11.1	1	7.1	1	5.0	0	0.0	3	6.5
Total	**9**	**100.0**	**14**	**100.0**	**20**	**100.0**	**3**	**100.0**	**46**	**100.0**

Table 11. Age and HPR

Chi-square= 18.9, p= .398

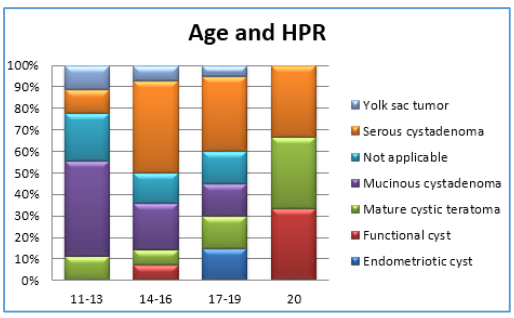

Figure 9. Age and HPR

Serous cystadenoma (32.6% of total cases) is most commonly found in the age group of 14 - 19 years, Mucinous cystadenoma in 11 - 19 years, Teratoma in 17 - 19 years, Yolk sac tumour in 11-19 years and endometriotic cyst in 17 - 19 years.

DISCUSSION

In my study, the ovarian masses included are a complex wide spectrum of neoplasms involving a variety of histological tissues ranging from epithelial tissues, connective tissue, specialised hormone secreting to germinal and embryonal

cells. The most common are the epithelial tumours forming 54.3% of all tumours. 93.4% are benign tumours and 6.5% are malignant. All the malignant tumours are germ cell tumours and all are primary from ovary.

In the case of ovarian malignancy, about two-thirds are already in stage IC and the prognosis in such cases is favourable with 5-year survival rate of 54% - 90%.

An ovarian mass in adolescence is more often benign than malignant. This study proves that most of the malignancies in the studied population were germ cell tumours.

In an attempt to standardise the nomenclature used in describing the diverse varieties of tumours, WHO classification is used to denote the histological finding. Epithelial tumours constitute about 54.3% of all ovarian tumours. The most common histological type is the serous cystadenomas accounting for 32.6% of all epithelial tumours. Mucinous cysts account for 21.7%, endometriotic cysts about 6.5%, functional cysts 4.3%, mature cystic teratomas 13% and the yolk sac tumours 6.5% of cases.

It is clear from the study that clinical examination can predict only to some extent in the identification of specific ovarian enlargements. The age related incidence of ovarian tumours show that most 80.4% tumours occurred commonly after the age of 14 years and only 19.6% occurred below 14 years. Majority of these tumours (93.5%) were cystic and cystic tumours in general are benign.

Endometrioma or chocolate cyst is a cause of 6.9% of cystic tumours. On vaginal/ rectal examination, the classic sign was adnexal mass with restricted mobility and tenderness in all of them. 33.3% of cysts were bilateral. The ultrasound is characteristic with low level internal echoes and posterior acoustic enhancement.

93.4% of all ovarian tumours in these age group are benign. Physiological cysts are seen in 4.3% of these age group and must be considered as a possibility.

Serous cystadenoma is the commonest of the benign epithelial tumours (32.6%). 82% of them were unilocular cyst usually with papillary processes on the inner and sometimes on the outer surface. In our study, the sonographic accuracy of detecting ovarian tumours is 89.1% with an average sensitivity of 86.6% and specificity of 91.1%.

Another observation in this study is that at TVS (Transvaginal scan), cystic masses constitute 89.1% and solid tumours 10.8%. It is found that malignant potential of the tumour is linked with the consistency of the tumours.

Unilocular unilateral tumours detected with a malignant potential of 8.2%, whereas bilateral unilocular tumours had 31.1% chance of malignancy. Chance of malignancy is 11.3% in multilocular tumours. Majority of solid tumours were bilateral (72.4%) with 66.6% of incidence of malignancy. Unilateral solid tumours got a malignant potential of 12.5%. This knowledge in detecting the consistency of the tumour can be made use of in evaluating the malignant potential of a tumour preoperatively.

There can be various causes for presence of an abdominal lump in a patient presenting to the gynaecological OPD. In this study, 50% of the patients had abdominal lump. Ovarian cystic masses are encountered in 93.4% of these adolescents. 73.9% were neoplastic and 10.8% of non-neoplastic masses. Of the ovarian neoplasms, 8.8% were malignant and 91.9% benign. 93.4% of the total ovarian tumours were benign and occur mostly in 17 - 19 age group (43.4%).

Non-neoplastic cysts of ovary are seen in 10.8% and occur mostly in 17 - 19 ages (60%). These cysts are also known as functional cysts and include follicular cysts, corpus luteal cysts and theca lutein cysts. Rapidity of growth being a feature of malignancy cannot be assessed in the study as it is a retrospective study and 84.8% of the cases are managed by surgery on diagnosis and 15.2% were managed conservatively.

The survival rate in stage I is around 90% and around 30% in stage III and IV. In this study, the malignant ovarian masses are detected in the limited stage diseases, that is stage I and IIA (Advanced stage is from IIA).

There were 46 cases of ovarian enlargements in this study. Of these 73.9% were neoplasms and 10.8% were endometriotic and functional cysts. Among the 41 neoplasms, 78% were cystic tumours and 7.3% were solid tumours and 14.6% were dermoid tumours.

93.4% were benign tumours and 6.5% were malignant tumours. Malignancy was detected with sonographic evaluation and Doppler flow velocimetry studies. Doppler diagnosed 33.3% of malignancies preoperatively.

We were using Doppler for ovarian mass to discriminate between benign and malignant lesions and to identify torsion in ovarian mass. There were 13.04% benign dermoid cysts.

It is found that unilocular tumours in this age group did not have any malignant potential. Multilocular tumours had 11.3% malignant risk. So after proper preoperative evaluation on the nature of tumour, benign tumours are posted for operative laparotomy or laparoscopy and malignant tumours for staging laparotomy. To confirm the diagnosis, histopathology is studied.

Sonography detected 89.2% of cystic tumours, as unilocular or multilocular which was cystic itself at surgery. Malignant chance in unilocular unilateral tumours were absent, whereas it is 66.6% in bilateral tumours. Multilocular bilateral tumours have 70% malignant chance.

Most common complication encountered was torsion (15.2%). It is found that torsion occurs more commonly in benign ovarian tumours (serous cystadenoma- 85.8%) in (10-19) age group. Intraoperatively, 11.3% of them were detected to be gangrenous.

Surgical management was employed for 93% of total cases, out of which 24% underwent cystectomy, 11% ovariotomy and 4% staging laparotomy.

The present study noted that epithelial ovarian tumours are the most common ovarian mass in adolescent age group (10 - 19) in the study location. Clinical findings are not that relevant in this age group (10 - 19) due to limitations in physical examination.

Currently, we are using laparotomy to get a histological diagnosis of ovarian mass and to stage the ovarian malignancy. A preoperative evaluation of the mass as benign or malignant or functional is very crucial. A non-invasive grading of the tumour is also important. B-mode ultrasound, Doppler studies and serum tumour markers help us in this preoperative evaluation of various pathologies. They can be employed for screening of ovarian malignancies as well as providing an optimal treatment during surgery.

In general, this study aims at giving an idea about the nature and occurrence of ovarian tumours in this particular age group in our population. With ultrasonography, either transvaginal or transabdominal, we could identify many

specific ovarian conditions. We find that functional ovarian cysts constitute 4.3% of all ovarian enlargements. Another 6.5% of ovarian enlargements were constituted by endometriotic cysts. Benign pathologies like dermoids are best diagnosed by ultrasound, but needs further evaluation.

According to this study sonography proves to be the best pre-operative evaluation in adolescent ovarian tumours, as it correlates well with the pathological type. Thus, it is a simple, quick, non-invasive procedure and found to be the most accurate investigation among the other tests for accounting the type of ovarian tumours.

With the help of sonographic evaluation and characterisation, surgery could be avoided in functional cyst and conservative surgery can be employed in benign cysts.

Epithelial ovarian tumour account for 54.3% of ovarian masses.

In my study, all are diagnosed as stage IC. Hence, there is a need for a screening method to detect early stage disease. If the disease is diagnosed early (confined to ovary), the 5-year survival is good. Five-year survival rate for early stage disease is 90% and for advanced disease it drops to 30%.

Transvaginal sonography combined with colour Doppler can discriminate a functional from organic pathology. Benign cysts can be managed laparoscopically and even in malignant tumours, laparoscopy offers a better visualisation of peritoneal cavity for secondaries and metastasis.

The prognostic variables in ovarian cancer are tumour grade, histological type, capsular penetration, surface excrescences, ascites, peritoneal cytology, adhesions, ploidy, performance status of the patient and size of the tumour after primary cytoreductive surgery.

This study found that 66.7% of the abnormal value of tumour markers were associated with a malignant pathological report. So, a negative marker status rules out malignancy, but a positive status does not confirm malignancy.

Studies have reported that the negative and positive predictive value is 100% and 73% respectively in diagnosing benign or malignant mass by colour Doppler, which increases the reliability of ultrasonographic diagnosis of ovarian tumours.

On analysis, my study found that Doppler velocimetry if done along with sonography is 100% abnormal in malignancies and all the benign cases were associated with normal Doppler parameters.

If flow velocity in Doppler is found normal with a PI >1.0 with diastolic notch detected, we have considered the mass as benign. Malignancy is suspected when PI has fallen below 1.0 with absence of diastolic notch. However, Doppler alone is not specific in detecting malignancy, but it is complimentary to sonographic finding. In cystic tumours if the diastolic flow is absent, it is diagnosed as torsion and it correlated with intraoperative finding.

If sonographic, Doppler velocimetry and tumour marker study are suggestive of malignancy, at laparotomy with the malignant potential in mind we could look meticulously for metastasis and secondary deposits and were able to provide optimum cure so that postoperative chemotherapy was effective with better survival rate. The adolescent's experience and expression of illness and pain should be viewed within the context of her life experiences. Most adolescents have limited life experiences with problems such as pain, discomfort or bleeding. An adolescent may state that she is experiencing the worst pain of her life and yet may appear to be reasonably comfortable.

The ovary typically is anchored to the side wall of the pelvis in the shallow peritoneal fossa of Waldeyer formed between the angle of proximity of the ovary to the ureter.

The ovary is connected to the uterus by the utero-ovarian ligament to the posterior aspect of the broad ligament by the mesovarium ligament, and to the lateral pelvic sidewall by the infundibulopelvic ligament.

Germ cell malignancies represent only 5% of ovarian cancers. Below 21 years, 70% of tumours are germ cell tumours and of these about one-third will be malignant. They account for two-thirds of the ovarian cancers in children and women below 21.[1]

Complication

Most of the tumours were benign cystic teratomas.[2] The risk of malignancy is maximum with serous cystadenoma (about 40%) and least with dermoid cyst (1% - 2%).[3] In this study, 17% presented as acute abdomen. Physiologic ovarian cysts normally are < 6 cm in diameter, smooth, mobile and slightly tender to palpation. They accounted for 4.3% of the total in my study.

Complete bilateral salpingectomy as a risk-reducing strategy in patients with BRCA mutations is an approach worthy of further investigation and it may be reasonable to consider salpingectomy for all patients undergoing hysterectomy for benign reasons, and for general population who seek permanent contraception. For instance, the Gynaecologic Oncology of Canada already recommends bilateral salpingectomy for patients undergoing hysterectomy or requesting permanent contraception.

The study concluded that ovarian mucinous tumour cases in childhood including premenarchal cases may not be as rare as people previously estimated and discovered some unique features of the tumours in this age group that are beneficial for better prognosis prediction and clinical management as well as better understanding of pathogenesis of ovarian epithelial tumours.[4]

When the tumour's molecular characterisation contributes to the choice of treatment, prognostic markers may turn into predictive markers.[5]

This study emphasises the greater use of tumour markers preoperatively, as 66.7% of malignant tumours had an abnormal level.

Ovarian tumours represent about 1.5% of all tumours in childhood and adolescence and about 95% of all gynaecologic tumours. They differ in types from those of adults: Epithelial tumours (carcinomas) do not occur in childhood, germinal and gonadal stromal tumours are typical in this age. Present development of paediatric and adolescent gynaecology is aimed to preserve for patients with tumours all prospects of future pregnancy, either in the natural way or using methods of assisted reproduction with a donated oocyte. Complex treatment of gonadal malignancies in childhood in future will be aimed not only at the lifesaving, but also at the preservation of the highest possible quality of life including the motherhood. Out of the sixty-three patients (15 months to 17 years of age, fifty six patients had germ cell tumours and 7 epithelial tumours, 47 patients had teratomas, 6 germinomas, 1 endodermal sinus tumour and 2 mixed germ cell tumours.

Of the patients with epithelial tumours, six had cystadenomas and one cystadenocarcinoma. Abdominal pain was the most common symptom and an abdominal mass the most common sign.[1] Majority of patients fell in the subgroup 14 - 16 years age. Majority harbouring ovarian malignancy belonged to subgroup 17 - 19 years. Clinical presentation in the majority was mass abdomen and abdominal distension. Approach was transcutaneous in 20%, laparoscopic in 20% and open laparotomy in 60%. Histopathology was benign in 11 cases and malignant in 4. There were 33.3% cases of dermoid cysts. All 4 malignancies were found to be to non-epithelial on histopathology.

This study shows the preponderance of non-epithelial tumours and high percentages of malignant germ cell tumours in adolescents. Early correct diagnosis could be reached by careful physical examination, imaging and tumour markers. Surgery should as much as is safely possible be fertility preserving.[6] The objective of the study was assessment of the adnexal tumour vascularisation with transvaginal colour and pulsed Doppler sonography. Vessel location, its arrangement and pulsed Doppler waveform characteristics were used to distinguish benign from malignant vascularity. Results showed that peripheral and pericystic location with single vessel displayed and resistance index above 0.40 were highly associated with benign ovarian lesions.[4] In conclusion in addition to resistance index analysis of blood flow, vascular arrangement and location are important for accurate discrimination of benign from malignant ovarian lesions.[4]

CONCLUSION

The present study noted that epithelial ovarian tumours are the most common ovarian mass in adolescent age group (10 - 19) in the study location. Clinical findings are not that relevant in this age group (10 - 19) due to limitations in physical examination.

A preoperative evaluation of the mass as benign or malignant or functional is very crucial. A non-invasive grading of the tumour is also important. B-mode ultrasound, Doppler studies and serum tumour markers help us in this preoperative evaluation of various pathologies. They can be employed for screening of ovarian malignancies as well as providing an optimal treatment during surgery.

In general, this study aims at giving an idea about the nature and occurrence of ovarian tumours in this particular age group in the study population. We find that functional ovarian cysts constitute 4.3% of all ovarian enlargements. Another 6.5% of ovarian enlargements were constituted by endometriotic cysts.

According to this study sonography proves to be the best pre-operative evaluation in adolescent ovarian tumours, as it correlates well with the pathological type. Thus, it is a simple, quick, non-invasive procedure and found to be the most accurate investigation among the other tests for accounting the type of ovarian tumours. Epithelial ovarian tumours comprise of 54.3% of ovarian masses.

In my study, all are diagnosed in stage IC. Hence, there is a need for screening method to detect early stage disease. If the disease is diagnosed early (confined to ovary), the five year survival is good.

Transvaginal sonography combined with colour Doppler can discriminate a functional from ovarian pathology. Benign cysts can be managed laparoscopically and even in malignant tumours laparoscopy offers a better visualisation of peritoneal cavity for secondaries and metastasis. This study found that 66.7% of the abnormal value of tumour markers were associated with a malignant pathological report. So a negative marker status rules out malignancy, but a positive status does not confirm malignancy.

On analysis, my study found that Doppler velocimetry if done along with sonography is 100% abnormal in malignancies and all the benign cases were associated with normal Doppler parameters. If flow velocity in Doppler is found normal with a PI > 1.0 with diastolic notch detected, we have considered the mass as benign.

Malignancy is suspected when PI has fallen below 1.0 with absence of diastolic notch. However, Doppler alone is not specific in detecting malignancy, but it is complimentary to sonographic finding. If sonographic Doppler velocimetry and tumour marker study is suggestive of malignancy, at laparotomy with the malignant potential in mind we could look meticulously for metastasis and secondary deposits and were able to provide optimum cure so that post-operative chemotherapy was effective with better survival rate.

ACKNOWLEDGEMENTS

I am extremely grateful to all my teachers and family.

REFERENCES

[1] Ehren IM, Mahour GH, Isaacs H. Benign and malignant ovarian tumors in children and adolescents. A review of 63 cases. Am J Surg 1984;147(3):339-44.

[2] Theodoridis TD, Zepiridis L, Mikos T, et al. Comparison of diagnostic accuracy of transvaginal ultrasound with laparoscopy in the management of patients with adnexal masses. Arch of Gynec & Obstet 2009;280(5):767-73.

[3] Takebayashi A, Shimizu Y, Takahashi A, et al. Comparison of the outcome of in vitro fertilization after laparoscopic laser ablation surgery versus laparoscopic cystectomy for endometrioma. Gynec Minim Invasive Ther 2013;2:27-9.

[4] Kurjak A, Predanic M, Kupesic-Urek S, et al. Transvaginal color and pulsed Doppler assessment of adnexal tumor vascularity. Gynecol Oncol 1993;50(1):3-9.

[5] Nagai Y, Tanaka N, Horiuchi F, et al. Diagnostic accuracy of intraoperative imprint cytology in ovarian epithelial tumors. Int J Gynec & Obstet 1983;21(2):103-10.

[6] Choudry A, Bangash N, Malik A, et al. Adolescent ovarian tumors: a clinicopathological review of 15 cases. J Ayyub Med Coll Abbottabad 2008;2(4):18-21.