

CLINICOPATHOLOGICAL STUDY OF MALIGNANT SOFT TISSUE TUMORSVenkatraman J¹, Rathna S², Dhananjay S. Kotasthane³, Govindaraj T⁴**HOW TO CITE THIS ARTICLE:**

Venkatraman J, Rathna S, Dhananjay S. Kotasthane, Govindaraj T. "Clinicopathological Study of Malignant Soft Tissue Tumors". Journal of Evolution of Medical and Dental Sciences 2014; Vol. 3, Issue 71, December 18; Page: 14483-14489, DOI: 10.14260/jemds/2014/4029

ABSTRACT: OBJECTIVE: "Soft tissue" is a non-epithelial extra skeletal tissue of the body exclusive of the reticuloendothelial system, glia and supporting tissue of the various parenchymal organs".^[1] Though they can occur anywhere in the body, most commonly they involve upper and lower extremities, trunk, retro-peritoneum and head and neck.^[1] Biological activity of these tumors varies from benign localized tumors, to benign locally aggressive, to malignant metastatic types.^[2] Diagnosis of soft tissue tumors are done by standard methods like Light microscopy, special stains and immunohistochemistry.^[3,4,5] This study was conducted with the aim of studying gross and microscopic features of various malignant soft tissue tumors and also to correlate them clinically. **MATERIALS AND METHODS:** The incisional and excisional specimens of various soft tissue tumors were fixed in 10% neutral formalin for 24 hrs and they were subjected for routine processing and reporting. Both gross and light microscopy of the tumors was studied that included the clinicopathological features of 109 cases of soft tissue tumors between the period of May 2008 to May 2012. **RESULTS:** A total number of 109 cases of soft tissue tumors were studied. Malignant soft tissue tumors constituted 14.6% of all soft tissue tumors with a peak age occurrence in the sixth decade and the most common malignant soft tissue tumor was malignant fibrous histiocytoma. **CONCLUSION:** Malignant soft tissue tumors occur less frequently and it is very important to make accurate diagnosis since it has a variable prognosis.

KEYWORDS: Malignant tumors, microscopy, soft tissue, malignant fibrous histiocytoma.

INTRODUCTION: "Soft tissue" is a non-epithelial extra skeletal tissue of the body exclusive of the reticuloendothelial system, glia and supporting tissue of the various parenchymal organs".^[1] Though, they can occur anywhere in the body, most commonly they involve upper and lower extremities, trunk, retro-peritoneum and head and neck.^[1] The incidence of benign soft tissue tumors are more when compared to the frequency of malignant ones. Malignant Soft tissue tumors occur more commonly in males than females. Biological activity of these tumors varies from benign localized tumors, to benign locally aggressive, to malignant metastatic types. The criteria used for grading soft tissue tumors include cellularity, mitotic count, tumor differentiation and necrosis. Prognosis of soft tissue tumors mainly depend on tumor size, microscopic grade, location, margins, clinical staging, DNA ploidy and genetic alterations.^[2] Diagnosis of soft tissue tumors are done by standard methods like Light microscopy of Hematoxylin and Eosin tissue sections, special stains like Masson's trichrome, PAS and if necessary immunohistochemistry.^[3,4,5]

MATERIALS AND METHODS: This study was carried out during May 2008 to May 2012 in a tertiary care hospital in Pondicherry, India. A detailed clinical data of the patient including clinical history and histo-pathological examination of the specimen was carried out. The parameters included were the age, sex, anatomical location, clinical diagnosis and the histo-pathological features. The material included incisional and excisional biopsies of various malignant soft tissue tumors.

ORIGINAL ARTICLE

The specimens were received in the Department of Pathology and gross findings like size, shape, colour and consistency were recorded. In selected cases, photographs of the specimen were also taken. The specimens were fixed in 10% neutral formalin for 24 hrs and then 4 mm thick sections were cut from representative areas and submitted for routine processing. Sections were studied by light microscopy after H and E staining. Special stains such as periodic acid schiff, Masson's trichrome and reticulin are done, wherever necessary. Immunohistochemical studies and the electron microscopical studies were advised in some of the soft tissue malignant tumors to support the diagnosis. The data was analyzed and compiled with help of tables, pie chart and bar diagrams. Histological subtypes were classified according to WHO classification of soft tissue tumors.

RESULTS: A total of 16 malignant soft tissue tumors out of a total of 562 malignant tumors of all types were included in the present study for final analysis.

INCIDENCE: Soft tissue tumors constituted 10.7% of all tumors. Malignant soft tissue tumors constituted 2.8 % of all malignant tumors. The tumor of fibrous tissue accounted for the majority of malignant soft tissue tumors (5.5%) followed by fibro-histiocytic tumors (3.6%).

AGE AND SEX: Malignant soft tissue tumors showed a striking female predilection with a male to female ratio of 1:1.6(Table 1). Majority of the malignant tumors occurred in the fourth, fifth, sixth and seventh decade with a peak occurrence in sixth decade (Figure 1).

SITE AND LOCATION: The malignant soft tissue tumors showed marked predilection for lower extremity followed by trunk (Table 2). 81.3% of the malignant soft tissue tumors measured more than 5 cms.

MALIGNANT FIBROUS TUMORS: Adult fibrosarcoma (figure 3) were the most common malignant fibrous soft tissue tumors (3 cases, 18.75%) followed by fibromyxoid sarcoma(2 cases,12.5%) and myxofibrosarcoma(1 case,6.25%) (Figure 2). All malignant fibrous tumors occurred in lower extremities and showed female predilection with a male to female ratio of 1: 5.

MALIGNANT FIBROHISTIOCYTIC TUMORS: Malignant fibrohistiocytic tumors were the most common malignant fibrohistiocytic soft tissue tumors (4 cases, 25%) of which 3 were of pleomorphic type and one was of giant cell type. Malignant fibrohistiocytic tumors showed predilection for lower extremities with male female ratio of 1:1.

MALIGNANT ADIPOSE TUMORS: Liposarcoma (2 cases, 12.50%) was the only malignant adipose tissue tumors of which one was myxoid variant that occurred in shoulder and the other one was de-differentiated, occurred in Retro peritoneum.

MALIGNANT VASCULAR TUMORS: Only two cases of angiosarcoma were encountered in the present study one in the lower extremity and one on the forehead.

OTHER SARCOMAS: There was one case of leiomyosarcoma(figure 4), which occurred in the vaginal wall and one case of sarcoma of uncertain Differentiation occurring in the sixth decade over the chest.

ORIGINAL ARTICLE

DISCUSSION: OCCURRENCE: A total of 109 soft tissue tumors were studied in the present study. Malignant tumors were 16 constituting 14.6%. The percentage of malignant tumors was less when compared to the study of Kransdorf⁵ because most of the patient's case material was referred to highly specialized centers.

The commonest malignant tumor was malignant fibrous histiocytoma, which constituted 25% of all malignant soft tissue tumors in the present study which was comparable to the studies of Fang^[6] and Tsujimoto.^[7] The second most common malignant tumor was fibrosarcoma which was in contrast to the studies of Fang and Tsujimoto where liposarcoma was found to be the second commonest malignant tumor.(Table 3)

SEX AND AGE: In case of malignant tumors there were 6 males and 10 females with a male to female ratio of 1:1.6, which was in contrast to the study of Tsujimoto.^[7] In the present study the average age in the case of malignant tumor was 55yrss, which is comparable to the studies of M. Jensen.^[8] And Tsujimoto.^[7] The age range in the case of malignant tumors varied from 20 years to 74 years with a peak occurrence in the sixth decade.

SITE: The malignant soft tissue tumors were observed to have a strong predilection for extremities forming 75%. This predilection is confirmed by the studies of Tsujimoto et al.^[7]

GROSS PATHOLOGY: 81.3% of malignant soft tissue tumors measured more than 5 cms, which has been noted by Myhre Jensen^[8] where the comparative figures was 75%.

FIBROUS TUMORS: The malignant fibrous tumors included 3 cases of adult fibrosarcoma, 2 cases of fibromyxoid sarcoma and one case of Myxofibrosarcoma and all were seen occurring over lower extremity in comparison with kransdorf study.

FIBROHISTIOCYTIC TUMORS: There were 3 cases of pleomorphic MFH and one case of giant cell type MFH. Pleomorphic MFH was the most common variant in the studies of Kransdorf.^[9]

ADIPOSE TISSUE TUMORS: There were two liposarcomas encountered in the present study which showed predilection over shoulder and retro peritoneum which was in contrast to the studies of Kransdorf.⁵

VASCULAR TUMORS: Two cases of angiosarcoma were encountered in our study and that were seen occurring in males in fourth and seventh decade with predilection for forehead and thigh. Interestingly, study of Morgan et al^[10] also showed that most of the patients were men (76%), with an average age of 75.1 years (range: 59-92 years) and the most common location was the head and neck region (96%)

OTHER MALIGNANT TUMORS: There was one case of leiomyosarcoma, which occurred, in the vaginal wall, one case of sarcoma of uncertain Differentiation occurring in the sixth decade over the chest.

ORIGINAL ARTICLE

CONCLUSION: The present study is a clinicopathological study of 109 cases of soft tissue tumors recorded at the department of pathology, Mahatma Gandhi Medical College, Pondicherry over a period of 4 years (May 2008 - May 2012). Based on the results and the methodology employed, we have concluded that: Soft tissue tumor accounted for 10.7 % of all tumors (1010 tumors diagnosed during the study period) and malignant soft tissue tumor accounted for 2.8% of all malignant tumors diagnosed during the study period. While malignant soft tissue tumors constituted 14.6 % of all soft tissue tumors with a benign to malignant ratio of 5.4:1. Malignant soft tissue tumors showed a peak age occurrence in the sixth decade. The male to female ratio among malignant soft tissue tumors were 1: 1.6. The malignant soft tissue tumors showed a marked site predilection for the lower extremities while 81.3 % of malignant tumors measured more than 5 cms.

ACKNOWLEDGEMENT: Authors sincerely thank Dr Soumya S, Head, Dept of Pathology, Sri Manakulavinayagar medical college, Puducherry for their constant support. Authors also acknowledge the immense help received from the scholars who articles are cited and included in references of this manuscript. The authors are also grateful to authors/editors/ publishers of all those articles, journals and books from where the literature for this article has been reviewed and discussed.

REFERENCES:

1. Enzinger FM and Weiss SW. Soft tissue tumors. 3rd edn. Missouri: Mosby Company; 1995.
2. Dreinhofer KE, Baldetorp B, Akerman M, Ferno M, Rydholm A, Gustafson P. DNA ploidy in soft tissue sarcoma: comparison of flow and image cytometry with clinical follow up in 93 patients. *Cytometry* 2002; 50: 19-24.
3. Fletcher CDM, Unni KK, Mertens F edn. WHO Classification of tumors of soft tissue and bone. Lyon: IARC Press 2002.
4. Espot NJ, Bilsky M, Lewis JJ, Leung D, Brennan MF. Soft tissue sarcoma brain metastasis-prevalence in a cohort of 3829 patients. *Cancer* 2002; 94: 2706-11.
5. Tsujimoto M, Aozasa K, Ueda T, Morimura Y, Komatsubra Y, Doi T. Multivariate analysis for histologic prognostic factors in soft tissue sarcomas. *Cancer* 1988; 994-998.
6. Fang Z, Chen J, Teng S, Chen Y, Xue R. Analysis of soft tissue sarcomas in 1118 cases. *Chin. Med. J.* 2009 Jan 5; 122 (1): 51-3.
7. Tsujimoto M, Aozasa K, Ueda T, Sakurai M, Ishiguro S, Kurata A, et al. Soft tissue sarcomas in Osaka, Japan (1962-1985): review of 290 cases. *Jpn. J. Clin. Oncol.* 1988 Sep; 18 (3): 231-4.
8. Jensen M, A consecutive 7 year series of 1331 Soft tissue tumors-A clinicopathological data comparison with sarcomas. *Acta orthop scand* 1981; 52: 287-293.
9. Mark J Kransdorf. Malignant soft tissue tumors in a large referral population: Distribution of specific diagnosis by age, sex and location. *AJR* 1995; 164: 129-134.
10. Morgan MB, Swann M, Somach S, Eng W, Smoller B. Cutaneous angiosarcoma: a case series with prognostic correlation. *J. Am. Acad. Dermatol.* 2004 Jun; 50 (6): 867-74.

ORIGINAL ARTICLE

S.NO	TUMORS	MALE	FEMALE
1.	FIBROUS	1	5
2.	FIBROHISTIOCYTIC	2	2
3.	ADIPOSE	1	1
4.	BLOOD VESSEL	2	0
5.	SMOOTH MUSCLE	0	1
6.	UNCERTAIN DIFFERENTIATION	0	1
	TOTAL	6	10

Table 1: Sex distribution of malignant soft tissue tumors

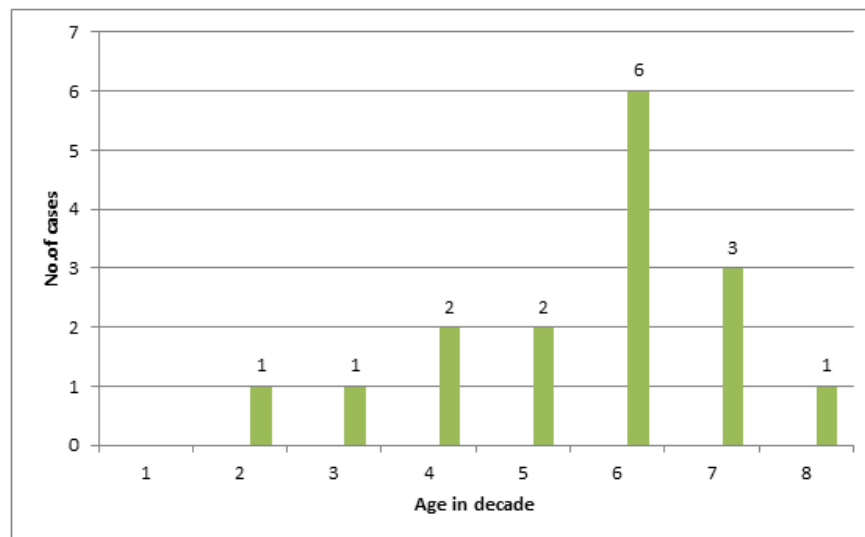


Fig. 1: Age distribution of malignant soft tissue tumors

	Tumors	Upper extremity		Lower extremity		Trunk	Head and neck
		Proximal	Distal	Proximal	Distal		
1.	Fibrous	0	0	1	5	0	0
2.	Fibrohistiocytic	0	0	3	1	0	0
3.	Adipose	1	0	0	0	1	0
4.	Blood vessel	0	0	1	0	0	1
5.	Smooth muscle	0	0	0	0	1	0
6.	Uncertain Differentiation	0	0	0	0	1	0
	TOTAL	1		11		3	1

Table 2: Anatomical site distribution of malignant soft tissue tumors

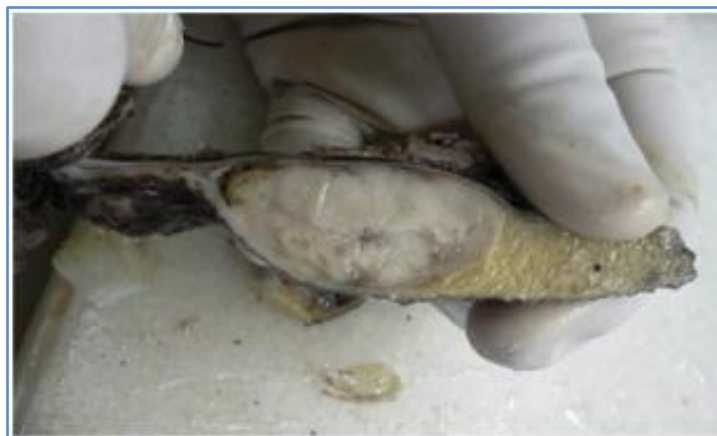

Fig. 2: Gross appearance of myxofibrosarcoma shows well circumscribed grey white area with myxoid changes

Tumor type	Fang (2009) ²⁷	Tsujimoto(1988) ²⁶	Present study
Fibrosarcoma	13.8 %	5.5 %	18.75 %
Malignant fibrous histiocytoma	35.2 %	34.8 %	25 %
Liposarcoma	16.2 %	9.7 %	12.5 %
Rhabdomyosarcoma	12.6%	7.9%	0

Table 3: Comparative analysis of occurrence (%) of various malignant soft tissue tumors

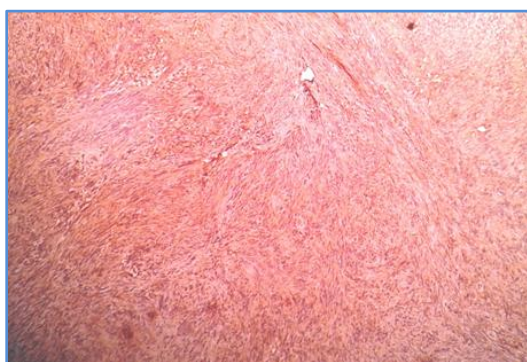


Fig. 3: Fibrosarcoma showing positivity for vimentin -10x

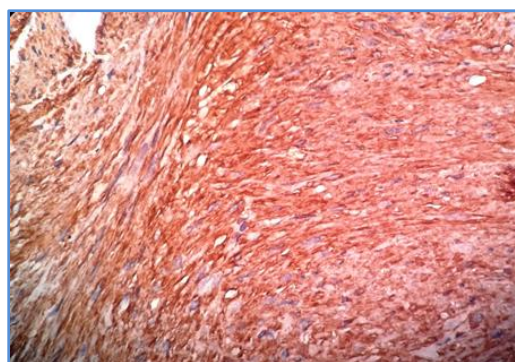


Fig. 4: Leiomyosarcoma showing IHC positivity for Actin(SMA)- 40X

AUTHORS:

1. Venkatraman J.
2. Rathna S.
3. Dhananjay S. Kotasthane
4. Govindaraj T.

PARTICULARS OF CONTRIBUTORS:

1. Assistant Professor, Department of Pathology, Sri Manakula Vinayagar Medical College and Hospital, Pondicherry.
2. Associate Professor, Department of Pathology, Sri Manakula Vinayagar Medical College and Hospital, Pondicherry.
3. Professor, Department of Pathology, Mahatma Gandhi Medical College and Research Institute, Pondicherry.

4. Assistant Professor, Department of Pathology, Sri Manakula Vinayagar Medical College and Hospital, Pondicherry.

NAME ADDRESS EMAIL ID OF THE CORRESPONDING AUTHOR:

Dr. Venkatraman J,
Assistant Professor,
Department of Pathology,
Sri Manakula Vinayagar Medical College and
Hospital, Madagadipet,
Pondicherry-605107.
Email: drvenkatraman1983@gmail.com

Date of Submission: 01/12/2014.
Date of Peer Review: 02/12/2014.
Date of Acceptance: 12/12/2014.
Date of Publishing: 16/12/2014.