

CASE REPORT

LARYNGOCELE: A CASE REPORT

B. Umakanth Goud¹, A. V. S. Hanumantha Rao², D. Satyanarayana³, Manish Kumar Gupta⁴, Juveria Majeed⁵

HOW TO CITE THIS ARTICLE:

B. Umakanth Goud, A. V. S. Hanumantha Rao, D. Satyanarayana, Manish Kumar Gupta, Juveria Majeed. "Laryngocele: A Case Report". Journal of Evolution of Medical and Dental Sciences 2015; Vol. 4, Issue 32, April 20; Page: 5586-5591, DOI: 10.14260/jemds/2015/817

ABSTRACT: Laryngoceles are rare, cystic dilatation of saccule of ventricle of larynx. Three types are recognized –internal, external and mixed types. Many of the laryngoceles are asymptomatic; few require surgical excision via internal/endoscopic or external approach. Contrast CT is the investigation of choice. A 40year old male presented to our OPD with a neck Scar, later diagnosed as laryngocele. Here is the case report about presentation, diagnosis and management of a large mixed layngocele.

KEYWORDS: Layngocele, Neck swelling, Saccule, Ventricle of larynx.

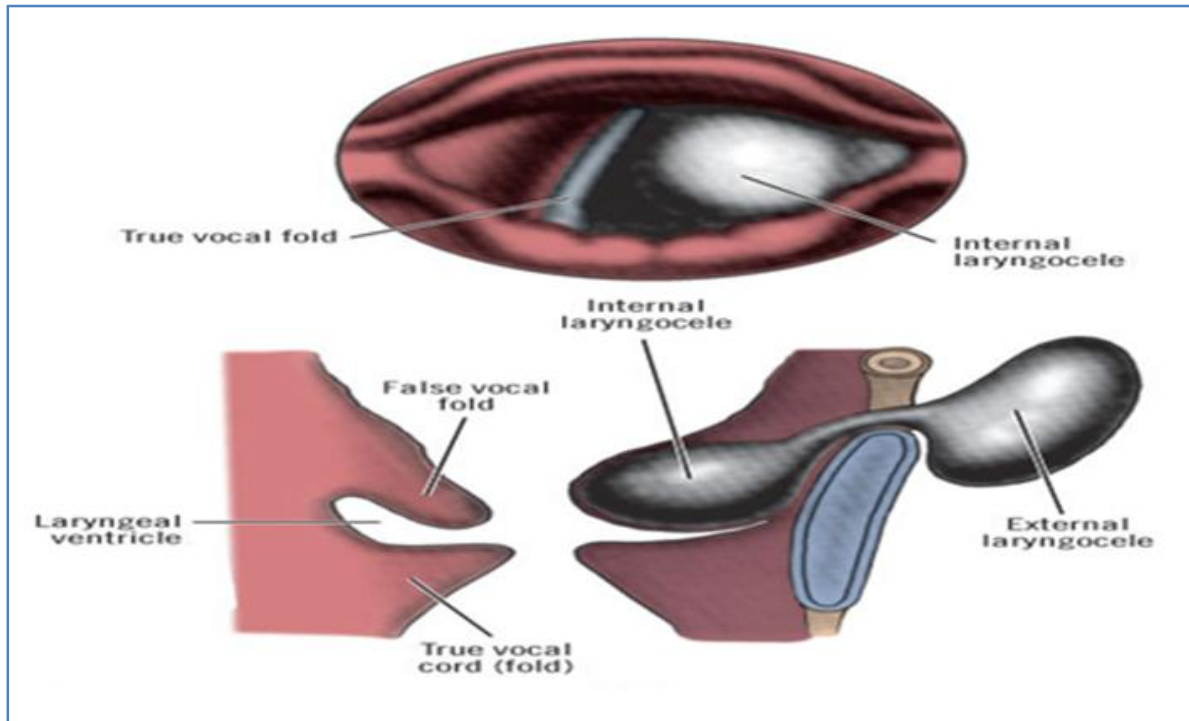
CASE REPORT: 40yrs old Male Agricultural laborer presented with history of swelling on right side of Neck increasing in size associated with cough from last 3yrs. Patient was operated 3 times earlier. On examination a horizontal scar mark of about 4cm size with sinus opening was found. CT Scan Neck was suggestive of air filled sac bulging into the neck through the Thyrohyoid membrane of about 6cm X 3cm X 2cm size. Video Laryngoscopy shows bulge above the right vocal card. Cervical exploration was done by the vertical incision of about 8cm, 1cm lateral to midline in right side extending from hyoid bone to adam's apple. Dissection was carried out air filled saccule was identified the laryngeal opening was closed with 00 proline. Superior Laryngeal nerve, Recurrent Laryngeal nerve, Ansa cervicalis and hypoglossal nerve where identified and preserved. Postoperative period was uneventful. Histopathology report of excised sac is not suggestive of any malignancy. Patient is under follow up after surgery from last one month.

DISCUSSION: A LARYNGOCELE is an abnormal saccular dilatation of the appendix of the laryngeal ventricle of Morgagni forming an air sac lined with pseudo-stratified, ciliated, columnar epithelium, which maintains its communication with the ventricle by means of a narrow stalk.¹ The laryngeal ventricle of Morgagni is normally a small elliptical recess located between the false cords above and the true cords below. The anterosuperior aspect of this recess ends in a blind pouch, which is called the appendix or appendage of the ventricle of Morgagni.^{1,2} According to Burke and Golden³ if the appendage extends above the upper border of the thyroid cartilage, it is abnormally long. Such a long appendage is considered to be congenital in origin and is found in 15 to 30 per cent of adults.³

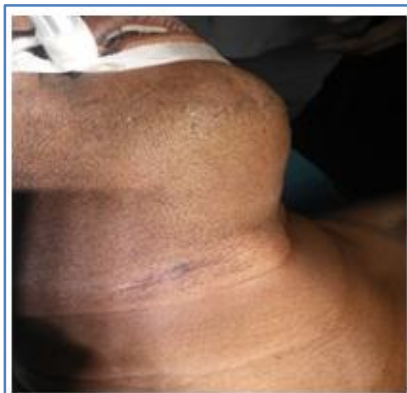It is uncommon lesion which usually occurs in the middle age but may be rarely seen in infancy, when it can produce respiratory distress which typically becomes worse on crying due to increased distension of laryngocele with air.⁴

A laryngocele is classified as internal it is contained entirely with the laryngeal framework, external if it pierces the thyrohyoid membrane and combined, if there are both external and internal components.⁴

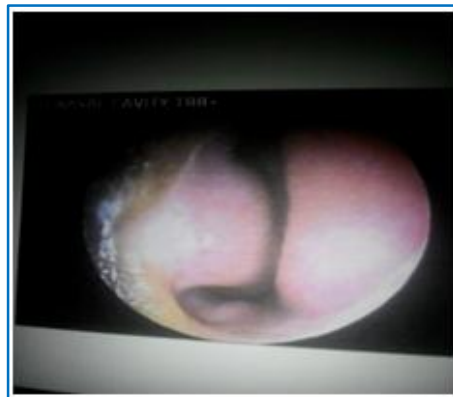CASE REPORT



Many laryngoceles are asymptomatic; sometimes they may cause a cough, hoarseness, stridor, sore throat, globus sensation and may present as a swelling on one or both sides of the neck.⁵ More commonly unilateral^{6,7} and rarely bilateral internal⁸ and bilateral external laryngoceles⁹ also exist. Sometimes a laryngocele may obstruct and becomes filled with mucus or become infected (laryngopyocele), thus becomes indistinguishable from saccular cyst.⁴

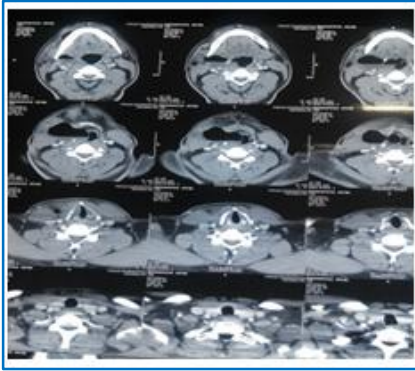


Pre-Operative Photo showing scar mark and Sinus opening

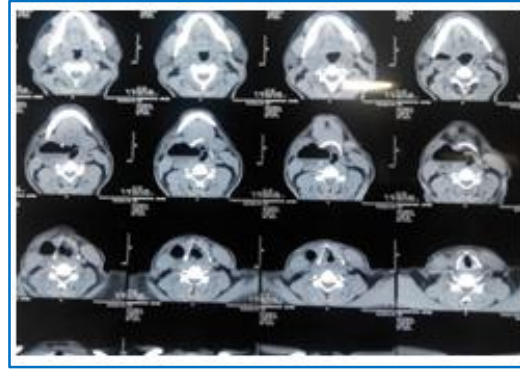


Pre-Operative VLS photo showing bulge

CASE REPORT



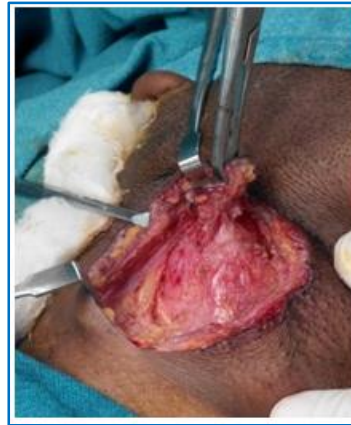
CT Images showing mixed Laryngocele



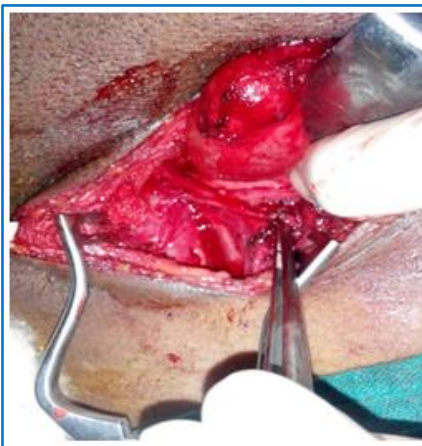
CT Images showing mixed Laryngocele

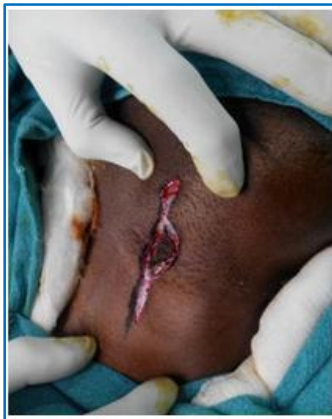

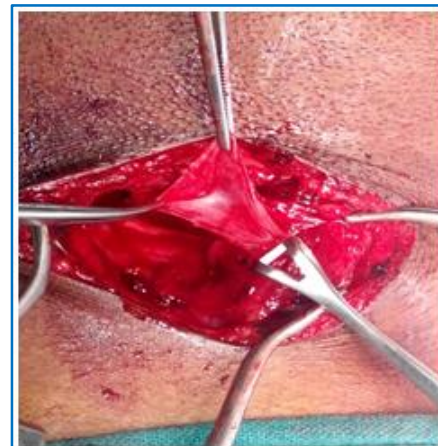Photo Showing the incision mark



Intra operative Photo showing the



Intra operative photo showing external Laryngeal nerve recurrent Laryngeal nerve, Hypoglossal nerve & Ansa cervicalis



Intra operative photo showing the sac

CASE REPORT

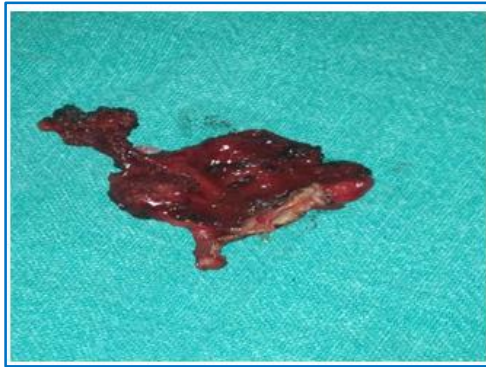

Photo showing excised Laryngocele

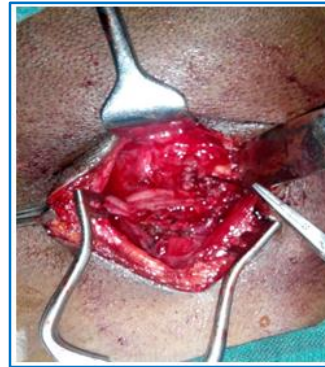
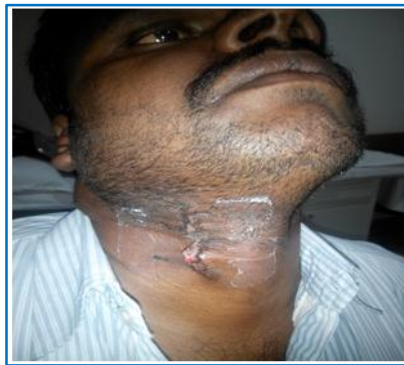

Photo after excision of sac showing different nerves



Post-Operative Photo showing the healing scar

ETIOPATHOGENESIS: For development of a laryngocele, its maintenance and its further enlargement, certain predisposing and concomitant factors are necessary. One prerequisite is a longer than normal ventricular appendage. Since laryngoceles occur in middle age or later, perhaps tissue changes associated with age also predispose to this condition. Functional factors which increase the intralaryngeal pressure, such as coughing, straining, singing and blowing wind instruments also are of importance in the etiopathogenesis of laryngoceles (Acquired type of Laryngocele).

Another mechanism is the appearance of a valve-like closure at the neck of the ventricular appendage, which allows the entrance of air, but prevents its exit. This valve-like action results from narrowing of the neck by inflammatory or neoplastic processes and may even be aggravated by pressure of the distended sac itself on the neck.

It is of interest to note that the reported incidence of laryngocele in cases of laryngeal cancers is between 1 per cent and 10 per cent. Therefore, if a laryngocele is detected clinically or radiologically, a carcinoma must be taken into consideration and appropriate tests be performed.^{10,11}

While the diagnosis of laryngocele is usually made on clinical grounds, it has to be differentiated from all other neck swellings which includes any cystic swelling in the upper part of the neck like branchial cyst, submandibular salivary gland duct cyst, cystic hygroma, saccular cyst,

CASE REPORT

mucous retention cyst, thyroglossal duct cyst and neck swellings which increase in size on valsalva manoeuvre like Jugular vein phlebectasia. A saccular cyst should also be kept in mind when an internal laryngocele is diagnosed. A pharyngocele also presents as a cystic swelling in the upper part of the neck.¹²

Computerised Tomography scan shows a well-defined, smooth, air filled sac in the lateral aspect of the superior paralaryngeal space. The connection between the air sac and the airway helps to establish the diagnosis. Magnetic resonance imaging, because of its multiplanar capability provides high definition of soft tissues, offers detailed information on the boundaries of the air-filled sac and, is useful when laryngomucocoele or laryngopyocele are suspected. MRI is also helpful to distinguish obstructed mucus and inflammation from neoplastic disease.¹³

Management of laryngoceles depends on the size of the laryngocele and patients complaints. Incidentally discovered or very small asymptomatic laryngoceles are observed, no active intervention done. Very small to small laryngocele can be dealt endoscopically or Endoscopic marsupialization with CO₂ laser.¹⁴ Large laryngoceles are excised via external approach or to say precisely only the external or combined laryngoceles has to be accessed via external approach. Two main external approaches: Transthyroid membrane and V shaped thyrotomies. A lateral cervical incision approach extending through the thyrohyoid membrane at the superior margin of the ala of the thyroid cartilage, with subperichondrial resection of a portion of upper part of the ala.^{4,14}

CONCLUSION: For an upper neck swelling, in the middle age group a diagnosis of laryngocele should be kept in mind. Diagnosis is mostly on clinical grounds, which is confirmed by CT neck. The traditional treatment of a laryngocele was excision using an external approach. Advances in endoscopic techniques and laser surgery have modified the treatment strategy. Microlaryngoscopy with use of a CO₂ laser has become the main therapeutic procedure for the treatment of internal laryngoceles. However, an external approach still remains the main therapeutic approach for the treatment of combined laryngoceles.

REFERENCES:

1. Joseph Giovanniello, R. Vincent Grieco and Noel F. Bartone. LARYNGOCELE. APRIL, 1970. www.ajronline.org/doi/pdf/10.2214/ajr.108.4.825.
2. Bateman, G. H. Case of bilateral external laryngocele. *Journal of Laryngology & Otology*, 1957, 71, 769-772.
3. Burke, E. N., and Golden, J. L. External ventricular laryngocele. *AM. J. ROENTGENOL., RAD. THERAPY & NUCLEAR MED.*, 1958, 80, 4953.
4. Brown S. *Benign conditions of larynx*, 7th edition, pg no. 1136-1137.
5. Lancellata A, Abbate G, and Dosdegani R, Mixed Laryngocele- case report *Acta Otorhinolaryngol Ital.* 2007 Oct; 27(5): 255-257.
6. Erdogmus B, Yazici B, Ozturk O, Ataoglu S, Yazici S *Wien Klin Wochenschr.* Laryngocele in association with ankylosing spondylitis. 2005 Oct; 117(19-20): 718-20.
7. The association of laryngoceles with ventricular phonation. Dray TG, Waugh PF, Hillel AD *J Voice.* 2000 Jun; 14(2): 278-81.
8. Luzzago F, Nicolai P, Tomenzoli D, Maroldi R, Antonelli AR. Laryngocele: analysis of 18 cases and review of the literature]. *Acta Otorhinolaryngol Ital.* 1990 Jul-Aug; 10(4): 399-412.

CASE REPORT

9. Meda, P. Symptomatic laryngocele in cancer of larynx. A. M. A. Arch. Otolaryng., 1952, 56, 512-520.
10. Harney M, Patil N, Walsh R, Brennan P, Walsh M. Laryngocele and squamous cell carcinoma of the larynx. J Laryngol Otol 2001; 115: 590-2.
11. Taylor, H. M. Ventricular laryngocele. 'Jr. Am. Laryng. A., 1944, 66, 114-126.
12. Binu R. George, Suhel Hasan, Naveen Kumar G, Salem MS. Tobook, Manjula Dhinakar. A Rare Case of Laryngocele in a Young Omani Male. George BR, et al. OMJ. 25, (2010); doi: 10. 5001/omj. 2010. 45.
13. J Gulia, S Yadav, A Khaowas, S Basur, A Agrawal. Laryngocele: A Case Report and Review of Literature. Indian Journal of otorhinolaryngology, 14(1). <https://ispub.com/IJORL/14/1/13884>.
14. Prasad K C, Vijayalaxmi S, Prasad S C, Laryngoceles- Presentations and management, Indian J. of Otolaryngology Head Neck Surgery, Oct-Dec 2008; 60; 303-306.

AUTHORS:

1. B. Umakanth Goud
2. A.V.S. Hanumantha Rao
3. D. Satyanarayana
4. Manish Kumar Gupta
5. Juveria Majeed

PARTICULARS OF CONTRIBUTORS:

1. Associate Professor, Department of Surgical Oncology, MNJ Cancer Hospital, Hyderabad.
2. Associate Professor, Department of ENT, Kakatiya, Medical College, Warangal.
3. Associate Professor, Department of ENT, Kakatiya, Medical College, Warangal.

FINANCIAL OR OTHER

COMPETING INTERESTS: None

4. Assistant Professor, Department of ENT, Osmania Medical College, Hyderabad.
5. Post Graduate, Department of ENT, Osmania Medical College, Hyderabad.

NAME ADDRESS EMAIL ID OF THE CORRESPONDING AUTHOR:

Dr. Manish Kumar Gupta,
H. No. 564, Road No. 12,
Banjara Hills,
Hyderabad-500034.
E-mail: drmanishgupta003@gmail.com

Date of Submission: 25/03/2015.
Date of Peer Review: 26/03/2015.
Date of Acceptance: 08/04/2015.
Date of Publishing: 20/04/2015.