

## CASE REPORT

### NON-COMPACTION CARDIOMYOPATHY IN AN APPARENTLY HEALTHY PATIENT: A CASE REPORT

Madhumalah R<sup>1</sup>, Antara Banerjee<sup>2</sup>, Sahajananda H<sup>3</sup>, Soumya Rohith<sup>4</sup>

#### HOW TO CITE THIS ARTICLE:

Madhumalah R, Antara Banerjee, Sahajananda H, Soumya Rohith. "Non-Compaction Cardiomyopathy in an Apparently Healthy Patient: A Case Report". *Journal of Evolution of Medical and Dental Sciences* 2015; Vol. 4, Issue 08, January 26; Page: 1381-1388, DOI: 10.14260/jemds/2015/193

**ABSTRACT:** Non-compaction cardiomyopathy is a rare genetic cardiomyopathy caused by a disorder during endocardial morphogenesis and could be accompanied by life-threatening complications on presentation. The major clinical manifestations of Non-compaction cardiomyopathy are heart failure, arrhythmias, embolic events and sudden death. The left ventricle is the most commonly reported affected site, but a few cases of right ventricular involvement have also been reported. We describe the perioperative management of a young patient who was posted for total abdominal hysterectomy, with no co morbid conditions, unremarkable pre anesthetic evaluation and normal investigations, who developed congestive heart failure in the post-operative period. The diagnosis was confirmed after an emergency echocardiogram. Despite an increasing awareness and interest in this anomaly, however, there is still little knowledge regarding diagnostic criteria, symptoms and prognosis of this rare and unique congenital disorder categorized as unclassified cardiomyopathy. The rarity of this condition has limited case reports and perioperative guidelines in the literature. Diagnosing and differentiating this uncommon condition from other forms of cardiomyopathy are important as treatment and prognosis may differ significantly. Our current understanding of isolated left ventricular non-compaction, including diagnostic criteria, management and prognosis, is discussed. The prognosis of the disease is determined by its complications; the death rate and heart transplantation frequency can be as high as 50%.

**KEYWORDS:** Non-compaction cardiomyopathy, heart failure, sudden death, genetic disorder

**INTRODUCTION:** Cardiomyopathy is severe myocardial disease leading to cardiac failure and sudden death. It is broadly classified into dilated, hypertrophic and restrictive cardiomyopathy. Ventricular Non Compaction (VNC) is a recently recognized congenital cardiomyopathy characterized by a distinctive ("Spongy") morphological appearance of the LV myocardium, resulting from an arrest in the normal embryogenesis<sup>1</sup>. VNC is classified by the American Heart Association as a primary genetic cardiomyopathy.<sup>1</sup> It has an incidence of about 0.05%.<sup>2,3</sup>

VNC consists of numerous excessively prominent ventricular trabeculations and deep intertrabecular recesses in the myocardium. The left ventricle is mainly affected, but the right ventricle is involved in 50% of cases<sup>4,5,6</sup>. The disease originates during embryogenesis, in weeks 5–8 of fetal life, when the ventricular myocardium compacts to form the endocardial capillaries and the coronary circulation develops<sup>5</sup>. The process of compaction progresses from epicardium to endocardium and from the base of the heart towards the apex<sup>6</sup>. In VNC the procedure of compaction is altered.

Major morbidity during long-term follow-up includes heart failure, arrhythmias and thromboembolic events. Heart failure was caused by systolic and diastolic dysfunction.<sup>7</sup>

## CASE REPORT

Recent advances in diagnostic imaging techniques have led to an increase in the detection of this previously rare form of cardiomyopathy, known as isolated left ventricular non-compaction (IVNC). It is important that clinicians recognize and differentiate this condition from other forms of cardiomyopathy as treatment and prognosis may differ significantly.

**CASE REPORT:** A 35yrs old, young lady presented with abnormal uterine bleeding (AUB) and was posted for Total abdominal hysterectomy under spinal anesthesia; pre-operative evaluation revealed no systemic abnormalities and all routine investigations were within normal limits, except for anemia. Intraoperatively patient was stable and surgery was uneventful and patient was shifted to post-operative ward. After 5 hours patient complained of chest pain and shortness of breath, was found to be tachycardic (120/min), tachypneic (40/min), hypotensive (90/50mmHg) and was desaturating (SpO<sub>2</sub> – 85%). She was started on O<sub>2</sub> (4L/min) and shifted to ICU immediately. Patient was placed on Non-invasive ventilation and 250 ml of fluid bolus given, but patient continued to be hypotensive, so she was started on Inj.Dopamine infusion at 5 mcg/kg/min. Laboratory tests showed negative cardiac enzymes with troponin levels consistently below 0.01 ng/ml (normal 0.00-0.03 ng/ml).

ECG was normal, Chest x-ray showed cardiomegaly with pulmonary vascular congestion and pulmonary edema. Pulmonary embolism was ruled out by spiral computer tomography (CT) scan. Inj. Frusemide 60 mg IV stat was given, ECHO showed concentric LVH, LV dysfunction and features of Non-compaction cardiomyopathy. Ejection fraction was 30-35% with moderate to severe hypokinesia. Patient was on non-invasive ventilation and inotropic support for 3 days; meanwhile patient was started on ACE inhibitor and was referred to tertiary cardiac center for further care.

**DISCUSSION:** Cardiomyopathies are a heterogeneous group of diseases of the myocardium associated with mechanical and/or electrical dysfunction that usually exhibit inappropriate ventricular hypertrophy or dilatation and are due to a variety of causes that frequently are genetic. Cardiomyopathies either are confined to the heart or are part of generalized systemic disorders, often leading to cardiovascular death or progressive heart failure-related disability. Primary cardiomyopathy (Genetic, non-genetic, acquired) are those solely or predominantly confined to heart muscle and are relatively few in number.

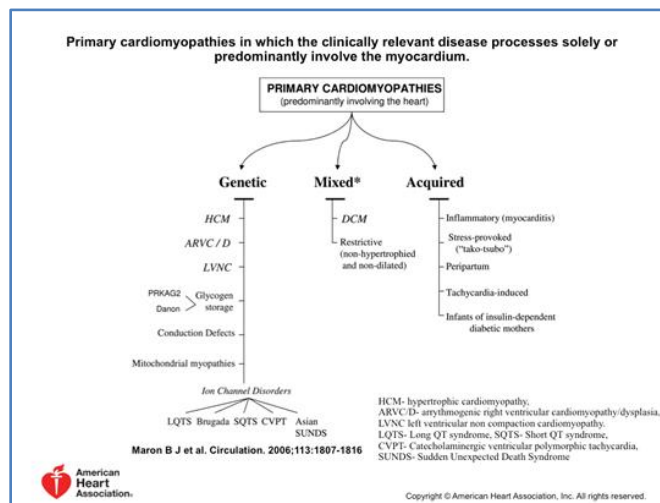


Fig 1

## CASE REPORT

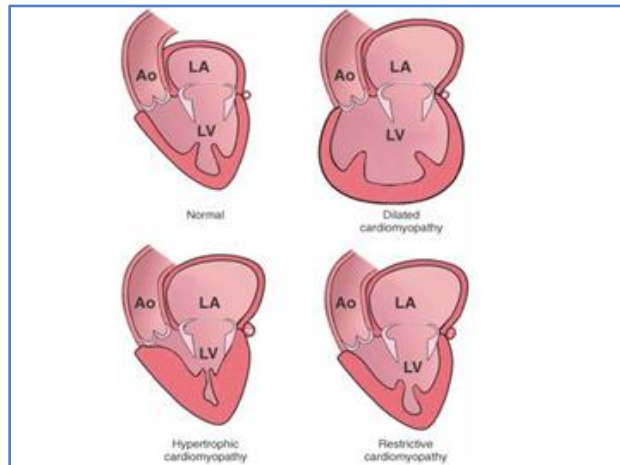
<b>Type of Cardiomyopathy</b>	<b>Features</b>	<b>Causative Factors</b>
Dilated	Dilated left or both ventricle(s), with impaired contraction	Ischemic, idiopathic, familial-genetic, immune, alcoholic, toxic, valvular
Hypertrophic	Left or right ventricular hypertrophy, or both	Familial, with autosomal dominant inheritance
Restrictive	Restrictive filling and reduced diastolic filling of one or both ventricles; normal or near-normal systolic function	Idiopathic, amyloidosis, endomyocardial fibrosis
Arrhythmogenic right ventricular cardiomyopathy	Fibrofatty replacement of right ventricular myocardium, Uhl's anomaly ("parchment heart")	Unknown; familial, usually autosomal dominant inheritance, with incomplete penetrance; possible autosomal recessive inheritance
Unclassified	Not typical for previous four groups	Fibroelastosis, non-compacted myocardium, systolic dysfunction with minimal dilation, mitochondrial disease

**TABLE NO. 1<sup>8</sup>**

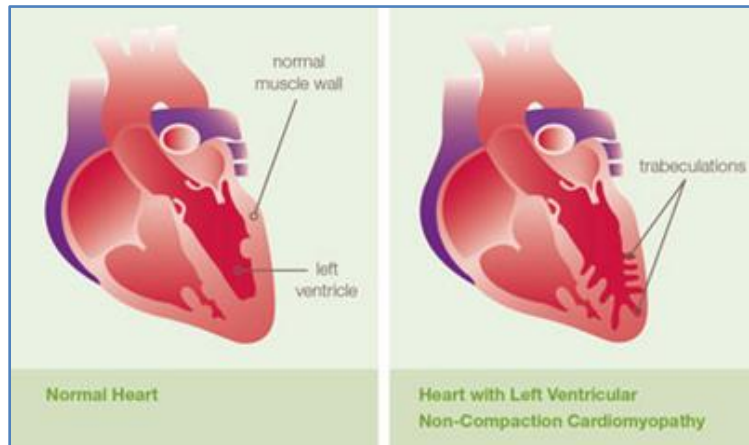
Data from Richardson P, McKenna W, Bristow M, et al: Report of the 1995 World Health Organization/International Society and Federation of Cardiology Task Force on the definition and classification of cardiomyopathies. *Circulation* 1996; 93: 841-842.

Secondary cardiomyopathies show pathological myocardial involvement as part of a large number and variety of generalized systemic (multiorgan) disorders.

## CASE REPORT



**Fig. 2: Kumar: Robbins and Cotran Pathologic Basis of Disease, Professional Edition, 9th ed**



**Fig. 3**

	Oechslin <sup>7</sup> et al.	Sengupta et al.	Murphy et al.	Lofiego et al.	Stöllberger et al.
Number of patients	34	32	45	65	86
Median age at diagnosis	40yrs	49yrs	37yrs	47yrs	52yrs
Percent male	74%	53%	62%	37%	76%
Familial Clustering	18%			15%	
Length of follow up	Up to 11yrs		Upto 15yrs		Upto 8yrs
<b>CLINICAL MANIFESTATIONS</b>					
Heart failure	68%	62.5%	62%	61%	70%
Arterial embolic event	21%		4%		
Pulmonary embolism	9%				
Ventricular thrombus	9%	6%			1%
Dysmorphic facies	0%				

## CASE REPORT

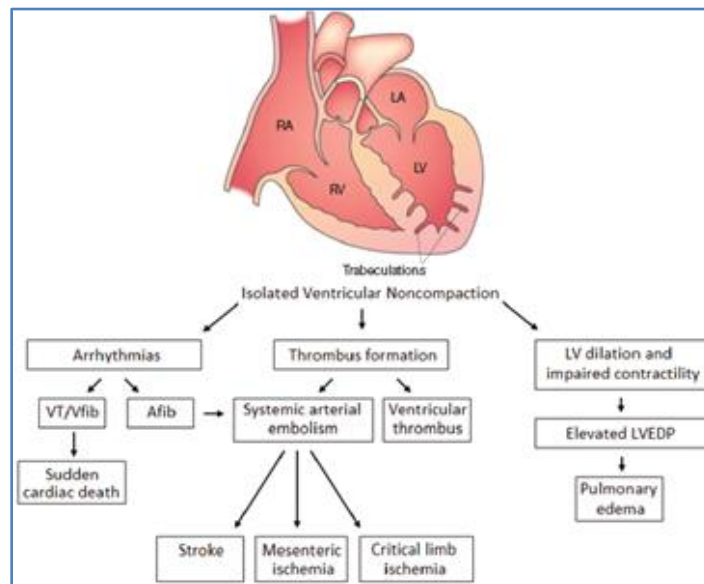
Neuromuscular disorder				9%	38%
Death	35%		2%		22%
Heart Transplantation	12%				1%
<b>ECG</b>					
AV block	56%		29%	32%	26%
Wolf Parkinson White Syndrome	0%				2%
Ventricular Tachycardia	41%		20%		
<b>TABLE NO. 2</b>					

Engberding, Rolf, et al. "Isolated non-compaction cardiomyopathy." *Deutsches Arzteblatt International* 107.12 (2010): 206.

Isolated left ventricular non-compaction is a recently described cardiomyopathy, the true prevalence of which remains unknown. Advances in diagnostic imaging modalities have undoubtedly led to an increase in detection of this rare condition and it is likely that earlier cases have been misdiagnosed as phenotypically similar cardiomyopathies, such as apical hypertrophic cardiomyopathy<sup>9</sup>, where prognosis and treatment may differ significantly.

To date, three genetic forms of the disease have been described<sup>10</sup>. Two forms are related to a mutation in chromosome 18, one of which is associated with other congenital heart defects presenting in childhood. The second is an isolated autosomal dominant form. Sometimes this type is related to facial dysmorphism. The third type of NCVM is linked to a mutation in the X chromosome, occurs in males and may be associated with skeletal myopathies. Adult forms of NCVM show non-specific clinical manifestations<sup>10, 11</sup> such as heart failure, primarily from left ventricular dysfunction, chronic myocardial ischaemia, supraventricular tachyarrhythmia, conduction defects and malignant ventricular tachyarrhythmia.

**FIG. 4:** The clinical manifestation encountered in LVNC and the overlap seen regarding risk of thromboembolism.



**Fig. 4**

## CASE REPORT

---

Shemisa K, Li J, Tam M, Barcena J. Left ventricular noncompaction cardiomyopathy. *Cardiovasc Diagn Ther* 2013;3(3):170-175. doi: 10.3978/j.issn.2223-3652.2013.05.04

Echocardiography remains the reference standard for the diagnosis of IVNC<sup>11</sup>. Jenni and colleagues identified four criteria for the diagnosis of IVNC by echocardiography<sup>11</sup>. A thick, inner layer of non-compacted myocardium is present subtending an outer, thin compacted layer of myocardium with ratio of non-compacted to compacted myocardium during systole being greater than 2:1. When the left ventricle is divided into nine segments, non-compacted myocardium is present predominantly (more than 80%) on the apical and mid-ventricular aspects of the inferior and lateral walls.

Cardiac magnetic resonance imaging may also be of use in the diagnosis of IVNC, in particular in individuals where the image quality at echocardiography is limited.

The knowledge about the pathophysiological changes, clinical presentation and complications in non-compaction cardiomyopathy is essential for planning the anesthetic care.<sup>12</sup>

In our case an apparently asymptomatic patient, previously undiagnosed and with no cardiac problems developed post-operative complications. The rarity of this condition with poor prognosis has limited case reports and perioperative guidelines in the literature.<sup>12</sup> The few available, do mention that the incidence of new post-operative arrhythmias following open cardiac and non-cardiac surgeries in non-compaction is 21% and 3%, respectively.<sup>13</sup> Implying that these patients need to be watched very carefully in the post-operative period for the development of complications. It is known that ventricular arrhythmias are related to sudden death in these patients.<sup>13</sup>

Treatment for patients with IVNC should be directed at the management of left ventricular systolic impairment where present; the detection, treatment and prevention of arrhythmias; and the prevention of systemic embolic events.<sup>13,14</sup> In addition to treatment with angiotensin-converting enzyme inhibitors,  $\beta$ -blockers and, where appropriate, diuretics and/or digoxin.

All patients with IVNC should be screened annually with 24-hour electrocardiogram recordings and considered for long-term prophylactic anticoagulation with warfarin. The high incidence of sudden death reported in patients with IVNC has prompted some authors to advocate a strategy of "early" automated implantable cardio defibrillator implantation.<sup>14</sup> The role of biventricular pacemakers in this population remains unclear. Finally, where pharmacological therapy fails to halt the progression to cardiac failure, heart transplantation should be considered.

Initial data from Europe and America reported a 4- to 6-year combined mortality or transplantation rate of ~50% to 60%<sup>6</sup> although recent UK data indicate the prognosis may be more favourable.<sup>14</sup>

**Conclusion:** Non-compaction Cardiomyopathy is a rare genetic disorder which maybe asymptomatic preoperatively but peri operatively may present as acute pulmonary edema, congestive cardiac failure or even sudden cardiac death. It is prudent to have knowledge of Non-compaction cardiomyopathy as one of the differential diagnoses in case of a cardiovascular mishap post-operatively.

## CASE REPORT

---

### REFERENCES:

1. B. J. Maron, J. A. Towbin, G. Thiene et al., "Contemporary definitions and classification of the cardiomyopathies: an American heart association scientific statement from the council on clinical cardiology, heart failure and transplantation committee; quality of care and outcomes research and functional genomics and translational biology interdisciplinary working groups; and council on epidemiology and prevention," *Circulation*, vol. 113, no. 14, pp. 1807–1816, 2006.
2. Oghenerukevwe Odiete, Ramanna Nagendra, Mark A. Lawson, and Henry Okafor, "Biventricular Non-compaction Cardiomyopathy in a Patient Presenting with New Onset Seizure: Case Report," *Case Rep Cardiol*, vol. 2012, Article ID 924865
3. M. L. Hughes, B. Carstensen, J. L. Wilkinson, and R. G. Weintraub, "Angiographic diagnosis, prevalence and outcomes for left ventricular noncompaction in children with congenital cardiac disease," *Cardiol Young*. vol. 17, no. 1, pp. 56–63, 2007
4. Errando, C. L., et al. "Splenic rupture and haemoperitoneum in a patient with non-compaction of the left ventricular myocardium." *Br J anaesth*. 95.3 (2005): 358-361.
5. Rigopoulos A, Rizos IK, Aggeli C et al. Isolated left ventricular non-compaction: an unclassified cardiomyopathy with severe prognosis in adults. *Cardiol*. 2002; 98: 25–32
6. Agmon, Yoram, et al. "Non-compaction of the ventricular myocardium." *J Am Soc Echocardiogr* 12.10 (1999): 859-863.
7. E. N. Oechslin, C. H. Attenhofer-Jost, J. R. Rojas, P. A. Kaufmann, and R. Jenni, "Long-term follow-up of 34 adults with isolated left ventricular non-compaction: a distinct cardiomyopathy with poor prognosis," *J Am Coll Cardiol*, vol. 36, no. 2, pp. 493–500, 2000.
8. Richardson P, McKenna W, Bristow M, et al: Report of the 1995 World Health Organization/International Society and Federation of Cardiology Task Force on the definition and classification of cardiomyopathies. *Circulation* 1996;93:841-842
9. Cruden NL, Denvir MA. Isolated left ventricular non-compaction as an unusual cause of heart failure: a case report. *J Med Case Rep* 2008; 2: 269. doi: 10.1186/1752-1947-2-269.
10. Sasse-Klaassen S, Gerull B, Oechslin E, Jenni R, Thierfelder L. Isolated non-compaction of the left ventricular myocardium **in adults** is an autosomal dominant disorder in the majority of patients. *Am J Med Genet* 2003; 119a: 162–7
11. Jenni R, Oechslin EN, Loo B: Isolated ventricular non-compaction of the myocardium in adults. *Heart* 2007, 93:11-15.
12. Manickam, Akilandeswari, Aruna Parameswari, and Mahesh Vakamudi. "Anaesthetic management of a patient with Cushing's syndrome and non-compaction cardiomyopathy for adrenal tumour resection." *Indian J anaesth* 56.4 (2012): 401.
13. Sviggum HP, Kopp SL, Rettke SR, Rehfeldt KH. Perioperative complications in left ventricular non-compaction. *Eur J Anaesthesiol*. 2011; 28: 207–12.
14. Murphy RT, Thaman R, Blanes JG et al: Natural history and familial characteristics of isolated left ventricular non-compaction. *Eur Heart J* 2005, 26:187-192.

## CASE REPORT

---

### **AUTHORS:**

1. Madhumalah R.
2. Antara Banerjee
3. Sahajananda H.
4. Soumya Rohith

### **PARTICULARS OF CONTRIBUTORS:**

1. Assistant Professor, Department of Anaesthesia, RRMCH, Bangalore.
2. Post Graduate, Department of Anaesthesia, RRMCH, Bangalore.
3. Professor and HOD, Department of Anaesthesia, RRMCH, Bangalore.

4. Associate Professor, Department of Anaesthesia, RRMCH, Bangalore.

### **NAME ADDRESS EMAIL ID OF THE CORRESPONDING AUTHOR:**

Dr. Sahahajananda H,  
413, 7<sup>th</sup> Main, Vijaya Bank Colony,  
Bannerghatta Road,  
Bangalore-76.  
E-mail: sahaj\_anand@hotmail.com

Date of Submission: 14/12/2014.  
Date of Peer Review: 15/12/2014.  
Date of Acceptance: 17/01/2015.  
Date of Publishing: 24/01/2015.