

## REVIEW ARTICLE

### CLINICAL STUDY OF RETINAL VEIN OCCLUSIONS AND MANAGEMENT

G. Satyavathi<sup>1</sup>, G. Serina<sup>2</sup>, B. Anusha<sup>3</sup>

#### HOW TO CITE THIS ARTICLE:

G. Satyavathi, G. Serina, B. Anusha. "Clinical Study of Retinal Vein Occlusions and Management". Journal of Evolution of Medical and Dental Sciences 2015; Vol. 4, Issue 07, January 22; Page: 1242-1255, DOI: 10.14260/jemds/2015/172

**INTRODUCTION:** Retinal vein occlusion is the most common retinal occlusive disorder encountered by Ophthalmologists and is usually associated with a variable amount of visual loss. This is the second most common retinal vascular disease next to diabetic retinopathy. Liebreich initially described dramatic obstruction of veins as retinal apoplexy. Leber<sup>(1)</sup> (1877) reported the first case of BRVO and called it Hemorrhagic retinitis. RVO most commonly affects the venous blood supply of the entire retina (CRVO) or a quadrant drained by one of the branches (BRVO) or less commonly the superior or inferior half of the retina alone is affected (HCRVO). For discussion and management purpose RVO is broadly classified into six clinical entities includes (1) Non-ischemic CRVO (2) Ischemic CRVO (3) Non ischemic HCRVO (4) Ischemic HCRVO (5) Major BRVO (6) Macular BRVO. So much of confusion still exists regarding its natural history, degree of severity, management and its progression. The clinical study of RVO is taken up mainly with a view to study the importance of systemic risk factors in etiopathogenesis of RVO, to study the clinical features and effectiveness of treatment in modification of the natural course and complications of RVO.

Depending on type of venous occlusion patient may present with long of central vision frequently noticed on waking of in the morning, or field contraction, erythropsia, floaters, black spots. Episodes of amaurosis fugax lasts for minutes to hours may be present. There may be metamorphopsia. Signs of decreased visual acuity, RAPD, visual field defects are observed. Fundus picture shows Retinal hemorrhages distributed based on type of venous occlusion. In ischemic CRVO the picture shows "berries on a twig". Various sequel & complications include macular edema, anterior segment and retinal neovascularisation, vitreous hemorrhage, retinal detachment may be encountered. Various risk factors include Hypertension, Diabetes, Hyperlipidemia, IHD, renal disease.

The first sign proving an ischemic CRVO is neovascular disease of the iris. Untreated rubeosis-iridis may lead to occlusion of the chamber angle with secondary glaucoma and hyphema.

**MATERIALS AND METHODS:** Our study named "CLINICAL STUDY OF RETINAL VEIN OCCLUSIONS AND MANAGEMENT" deals with analysis of various aspects of the three main morphological types of retinal vein occlusions. This study is conducted on 50 eyes of 50 patients who presented to our hospital. Of these 50 eyes 13 cases are CRVO, 2 case of HRVO, 35 case of BRVO. In this series only unilaterally affected cases and patients with age more than 50 years were included.

**Materials:** Patients attending our OPD at Government General Hospital, Guntur who are diagnosed to have RVO. Totally 50 eyes of 50 patients were studied.

**Duration of Study:** 21 months (from January 2013 to September 2014).

## REVIEW ARTICLE

---

**Place of Study:** The study was carried out at Ophthalmic Department, Government General Hospital, Guntur.

**Methods:** Study design: Prospective hospital based cross sectional study. This study was performed on analysis of prevalence, risk factors, clinical presentation, management and complications of these 50 patients.

A detailed case history including age, gender, occupation, economic status and predisposing factors like hypertension, diabetes, IHD, renal disease, H/O smoking were recorded. A detailed interrogation was made to elicit the other signs and symptoms to exclude other ocular conditions like POAG which is a known risk factor. Thorough examination consisting of visual acuity recording, external examination and slit lamp examination of the anterior segment and posterior segment examination with direct, indirect ophthalmoscopy and +90D examination, fundus photographs are taken in fundus camera and IOP was recorded.

Inclusion criteria are flame-shaped, dot or punctate retinal hemorrhages or both in one or four quadrants of the retina, dilation and increased tortuosity of retinal veins and optic disc swelling with or without macular edema. Later Criteria expanded to include cases in whom retinal hemorrhages had resolved and new vessels or collaterals had developed. Investigations related to various risk factors were done in accordance with our proforma. The course of the disease was monitored throughout the study period and appropriate intervention in individual cases was done based on its necessity. Those with associated diabetic retinopathy changed on fundus examination are excluded.

**Risk Factors:** Patients with systolic BP greater than 140mm of Hg or diastolic BP greater than 90mm of Hg or those receiving any antihypertensive medications, Patients with Diabetes having fasting blood sugar more than 120 mg% or post-prandial blood sugar above 200 mg% or those receiving any anti diabetic medications, Fasting serum cholesterol above 200 mg%, fasting triglyceride levels more than 170mg%, LDL level more than 130mg/dl, those having ECG or echocardiographic abnormalities as confirmed by the physician or cardiologist, Patient with blood urea more than 30mg/dl or serum creatinine more than 1.0mg/dl. are taken into consideration regarding risk factors

**Fundus Evaluation:** Fundus photography with 30<sup>o</sup> fundus camera was done. FFA was performed as early as possible after hemorrhages cleared. Areas of capillary drop-outs, leaks at macular area or elsewhere, areas of blocked fluorescense, late phase staining of veins and veno-venous channels were noted.

**Treatment Protocol for RVO:** Treatment of underlying systemic condition like HTN, DM, IHD and Renal disease based on physician opinion. Medical management given to all patients consists of antioxidants and Tab. Vitamin C as supportive therapy. Patients with CVS risk factors were treated with Tab. Trental (Pentoxifylline) 400mg BD for 3 months.

Specific treatment given to the patient's requirement depending on clinical and FFA findings but a broad outline of the course of management is as follows:

1. CRVO with macular edema – intra Vitreal avastin injection with monthly follow up and repeated based on the Visual acuity and response of the macular edema to the injections.

## REVIEW ARTICLE

---

2. CRVO with anterior segment neovascularisation – pan retinal photocoagulation.
3. HRVO with macular edema – patients treated with intra Vitreal Avastin with monthly follow up and repeat injections were given based on the patients VA and response of macular edema to the treatment.
4. BRVO with macular edema patients treated with Intra Vitreal Avastin with monthly follow up and repeat injections are given based on the patients VA and response of macular edema to the treatment. Grid laser is given to the patients with persistent macular edema (more than 3 months).
5. BRVO with evidence of NVD/NVE: Sectoral PRP.
6. BRVO with macular edema and NVE/NVE: Grid laser photocoagulation + sectoral panretinal photocoagulation is given. Ischemic RVO cases were followed with medical treatment until there were any signs of neovascularization.

**Follow-Up:** Patients were follow-up every month for three months and later at three-monthly intervals. During each visit, patients were reassessed completely with VA testing, anterior segment and Posterior segment evaluation, Gonioscopy.

**RESULTS:** This study was conducted on retinal occlusions in 50 eyes of 50 patients who presented to our hospital. Of these 13 cases are CRVO, 2 cases are HRVO, 35 cases are BROV. The following are observations made from the study.

**Prevalence of RVO:** During 1 year 9 months (21 months) period from January 2013 to September, 2014, 21,764 new patients attended the ophthalmic outpatient department, Government General Hospital, Guntur. Out of them 148 cases were RVO. 50 cases were selected for detailed study, satisfying the previously described inclusion criteria of age more than 50 years and unilateral cases of RVO. Prevalence of RVO among the patients attending outpatient ophthalmology department at GGH, Guntur.

$$\text{Prevalence} = (148/21,764) \times 100 = 0.638\%.$$

This prevalence results were consistent with prevalence of Baever Dam eye study conducted by Klein. R where the prevalence was 0.6%.

**DISCUSSION:** Results in this were studied under:

1. Epidemiological characteristics,
2. Clinical features,
3. Treatment.

**Epidemiological Characteristics:** Prevalence of RVO: Prevalence of RVO among the patients attending outpatient ophthalmology department at GGH, Guntur is 0.68%. This prevalence results were consistent with prevalence of Baever Dam eye study conducted by Klein.R where the prevalence was 0.6%.

**Incidence of various Types of RVO:** In this study incidence of BRVO was 70%, HCRVO was 4% and CRVO was 26%. These results are concordant with results of Blue Australian conducted by Michell. P et al.<sup>(2)</sup> (BRVO-69.5%, HCRVO-5.1%, CRVO-25%).

## REVIEW ARTICLE

---

**Age Distribution:** Mean age group for CRVO in this study was 66 years and the mean age group for BRVO was 65 years. The overall mean age group was 67 years.

**Sex Distribution:** In this study we found a slight male preponderance for both CRVO and BRVO with approximately 54% incidence respectively. Explanation for increased incidence of RVO in males is on hormonal basis. Higher haematocrit in males could act as a contributory factor in elevating blood viscosity and producing RVO.

**Laterality:** This study is dealing only with unilateral cases of RVO. Out of the 13 cases of CRVO that was studied, 5(38.46%) involved the right eye and 8(61.53%) involve the left eye. In 35 cases of BRVO, slight majority of involvement of right eyes (19 of 36 cases) was seen. Significant difference is not seen with laterality in this study, a total of 24 cases involve the right eye and 26 cases involve the left eye.

**Branch Involved in HCRVO:** No significant comment can be made here since the number of HCRVO studied was very less.

**Branch Involved in BRVO:** Superotemporal quadrant is the commonest site of occlusion in BRVO, as is already known this was corroborated well in this study, ST-BRVO forming about 57.14% of the total cases followed by IT-BRVO which formed about 28.58%. There was a single case of SN quadrant being involved, while 4 cases had a macular BRVO.

**Risk Factors:** Hypertension is a known risk factor for RVO seen in 70% of patients more than 50 years. In this study patients included are patients with age >50 years and hypertension is seen in 62% of cases. Association of hypertension is more with BRVO (65.71%) than CRVO (53.85%) in this study. One of our patients of HCRVO was hypertensive. Incidence of hypertension was more than DM in both CRVO and BRVO groups while neither of the two patients of HCRVO we studied were diabetics. Only two of the 13 CRVO cases had diabetes (15.38%), while eight of 35 BRVO cases had diabetes (23.85%). Association with Diabetes is not a major risk factor in BRVO is proven in this study. Renal diseases are also one of the risk factors studies in RVO, shows 7.69% in CRVO 2.85% in BRVO. This study shows renal disease as a risk factor but not as important as hypertension. Higher prevalence of increased serum cholesterol levels more than 200mg% was found in 46.15% i.e. six of 13 patients of CRVO.

In the BRVO category, though levels more than 200mg% was found in around 28% of cases, levels more than 180mg% was significant comprising of 62.85% of the total (23 of 35 patients).

Dodson et al.<sup>(3)</sup>, has reported a prevalence of hyperlipidemia of 54%. Serum Cholesterol levels were significantly associated with CRVO cases in this series wherein 46.15% of these patients had levels exceeding 200mg%, but when compared to this statistics, the number of patients who actually had systemic manifestation in the form of IHD was only around 10%. While analyzing the risk factors in this study, the association of hypermetropia with CRVO is seen in 23.07% and BRVO in 28.57% is not significant. Due to the small number of cases in the HCRVO group, we cannot comment about the association of risk factors.

## REVIEW ARTICLE

---

### CLINICAL FEATURES:

**Duration of Defective Vision:** 4 of 13 CRVO patients (30%) presented early with sudden painless loss of vision within 1 month while 14 of the 35 cases of BRVO (40%) presented within the same period. Remaining 70% of the CRVO cases and 60% of BRVO cases present after 1 month. This delay of many RVO patients in presenting to us may be explained by the fact that our institute being a tertiary care ophthalmic centre, referred cases from the periphery came to our hospital a prolonged period after the onset of disease.

One of the CRVO case who was presented at 8 months after onset had redness and pain of the affected eye of around 2 months duration. IOP in these cases was 69mm of Hg respectively. This case was diagnosed as cases of NVG with presence of NVI visible on slit lamp examination. This case was treated with anti glaucoma medication to control IOP and with PRP and Avastin. One other case of CRVO who presented 6 months after onset had evidence of NVI. This case was treated with PRP.

Of all cases 4 cases of macular BRVO presented to us within 20 days of onset. Of the remaining, 10 cases of BRVO that presented to us within a month, 7 cases had macular edema suggesting that in cases of macular involvement, patients tend to seek early medical advice.

**Presenting Visual Acuity:** Majority of patients with CRVO presented with grossly diminished vision below 6/60. This number amounted to almost 84% of the total CRVO cases. Only 2 cases had visual acuity over 6/60. Both patients of HCRVO present with diminished visual acuity because of macular edema. Of the 17 patients in the BRVO category who presented with vision less than 6/60, 9 patients were found to have macular edema.

**FFA findings:** 9 of 13 cases of CRVO show evidence of macular edema, 4 cases showed capillary non-perfusion. Of these 4 cases, one case developed NVG, second one developed NVI and remaining 2 cases no evidence of signs of neovascularization. In this study of 35 cases of BRVO, 4 cases showed areas of capillary non-perfusion alone without any neovascularisation, one of which had CNP more than 5DD. 4 cases showed evidence of NVD/NVE, while 20 cases had macular edema shown by late staining of macula. 2 cases showed both neovascularisation and macular edema. All BRVO cases revealed the site of venous occlusion with dilation of vein distal to the A-V crossing and late staining of the vessels. FFA was not conclusive in 2 cases because of no view (due to extensive hemorrhages).

**Treatment:** Out of 13 cases of RVO, 9 cases are treated with repeated injections of intra Vitreal Avastin and followed up. 2 cases are treated with PRP and intra Vitreal Avastin. Remaining 2 cases are managed with general medical treatment and then followed up. Out of 35 cases of BRVO, intra Vitreal Avastin were given in 19 cases, 5 cases require Grid LC because of persistent macular edema 3 months after Avastin. 4 cases are treated with second PRP as they show evidence of NVD/NVE.

**Final Visual Acuity:** Final visual acuity in the CRVO group as expected was significantly less than that of BRVO group. Patients in the CRVO category, final visual acuity of less than 6/60 was around 61% while in the BRVO group around 42% cases. 5 cases of the CRVO group had stationary vision, one case shows deterioration of vision and remaining 7 cases shows improvement. An interesting observation was deterioration & stationery vision are seen mainly in ischemic cases.

## REVIEW ARTICLE

---

In the HCRVO group one case followed with medical treatment and other case treated with Avastin shows improvement in Visual acuity. In 15 cases of BRVO who received Avastin shows improvement in 8 of 15 cases or remains stationary in 7 of 15 cases but there is no deterioration. In case of 7 cases of persistent macular edema with intra Vitreal Avastin, 5 cases are treated with Grid LC shows improvement in 4 of 5 cases or remain stationary in 1 of 5 cases.

**Response to Treatment:** In Ischaemic CRVO Group (4 Patients) only one patient had visual improvement from 3/60 to 6/60. This patient had Neovascularization of the iris and the angle for which she was given 2 sittings of PRP in combination with 3 monthly intra Vitreal Avastin. 2 cases had their vision stationary at the end of the study period without improvement or deterioration. Of these, one case had neovascularization of iris & neovascular glaucoma with IOP of 69mm of Hg was treated with anti glaucoma medications, 2 sittings of PRP and Intra vitreal Avastin. Second case had CNP>10DD and no raised IOP is advised for follow up. On follow up there is no improvement of vision or no signs of neovascularisation. One case had a CNP and advised for follow up every month but lost for follow up and again came after 6 months with deterioration of vision.

The patient had a vision of CFCF at the time of presentation and final VA was CFCF and advice the treatment for NVG and also PRP and again patient lost for follow-up. In Venous Statis Retinopathy Group (9 Patients) all these patients had macular edema and were managed with Intra Vitreal Avastin with monthly follow up and repeat depending on the response. Vision improved by an average of two lines in the Snellen's Chart in 7 patients. Stationary vision was seen in 3 patients. In HCRVO Group (2 patients) both patients have macular edema and one was managed with intra vitreal avastin and another patient is followed with general medical treatment. These two patients show improvement in VA. In BRVO Group (35 patients) Treatment of all patients was tailored to their requirement depending on clinical and FFA findings but a broad outline of the course of management is as follows:

ME:	Intravitreal avastin / Grid laser photocoagulation
NVD/NVE:	Sectoral PRP
CNP<5DD:	Medical management
CNP<5DD:	Medical management

Variable results were found in this category and are described below.

In 8 of 35 cases (22.85%) vision remained stationary. Three of these 8 cases, 3 had ischemic BRVO, one treated with sectoral PRP and another two are followed with medical therapy. Of remaining 6 cases, 2 are treated with Avastin but they did not show any improvement. Remaining four cases are followed with medical treatment. There is Deterioration of Vision of the 2 patients in whom vision fell in spite of treatment, one case with ME received both Avastin and Grid LC, still it shows deterioration of vision.

Another case which was treated with sectoral PRP does not show any regression on neovascularization and present with deterioration of vision and vitreous hemorrhage. The bulk however was formed by patients who had an improvement in their vision post treatment. This was 25 of 35 i.e. 71.42% of cases. This group included patients with multivariate presentation. OF these cases 11 cases show improvement with AVASTIN, 5 cases show improvement with AVASTIN & GRID LC and remaining cases shows improvement with Medical treatment and follow up.



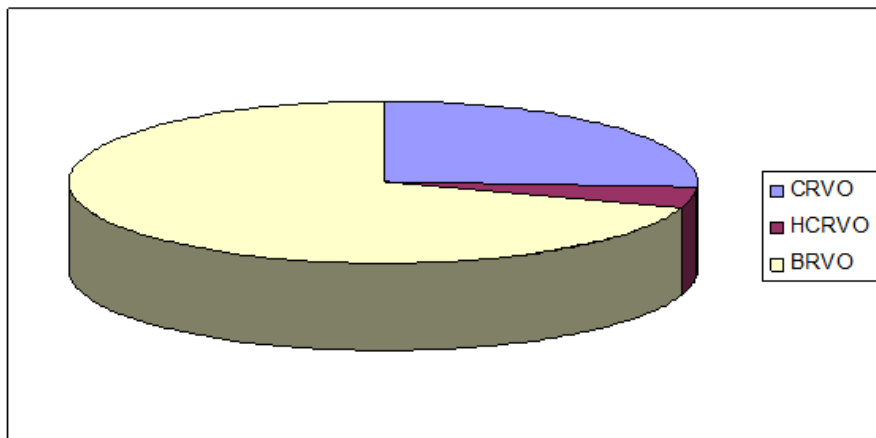
## REVIEW ARTICLE

### REFERENCES

- 1) Hayreh S. S. Retinal Vein Occlusion, Indian J Ophthalmol 42:3, 109-132, 1997.
- 2) Michell p, et al, Prevalence and association of retini vein occlusion in Australia. The blue mountain study. Arch ophthalmol. 1996 Oct; 114 (10); 1243-7.
- 3) Dodson PM, Galton DJ, Winder AF. Retinal Vascular abnormalities in the hyperlipidaemias. Trans Ophthalmol Soc U.K. 1981; 101(1):17.

	<b>Our Study (50)</b>	<b>Australian Study (59)</b>
CRVO (%)	13 (26%)	15 (25%)
HCRVO (%)	2 (4%)	3 (5.1%)
BRVO (%)	35 (70%)	41 (69.5%)

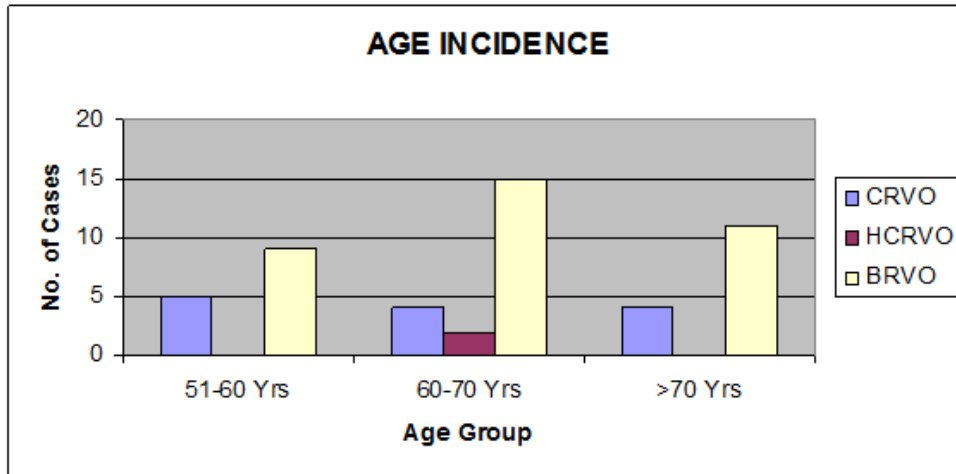
**Table 1 (Incidence of Various Types of RVO)**



<b>Age Incidence</b>	<b>CRVO</b>	<b>HCRVO</b>	<b>BRVO</b>
51-60 Yrs	5(38.46%)	-	9(25.71%)
60-70 Yrs	4(30.76%)	2(100%)	15(42.87%)
>70 Yrs	4(30.76%)	-	11(31.42%)

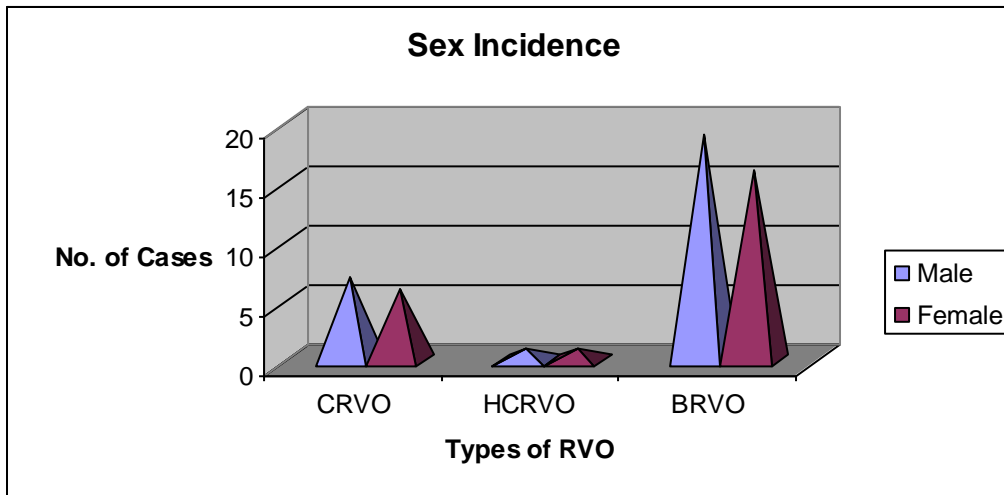
**Table 2 (Age Incidence)**

# REVIEW ARTICLE



	Male	Female	Total
CRVO	7 (53.84%)	6 (46.15%)	13
HCRVO	1 (50.00%)	1 (50.00%)	2
BRVO	19 (54.28%)	16 (45.71%)	73

**Table 3 (Sex Incidence)**

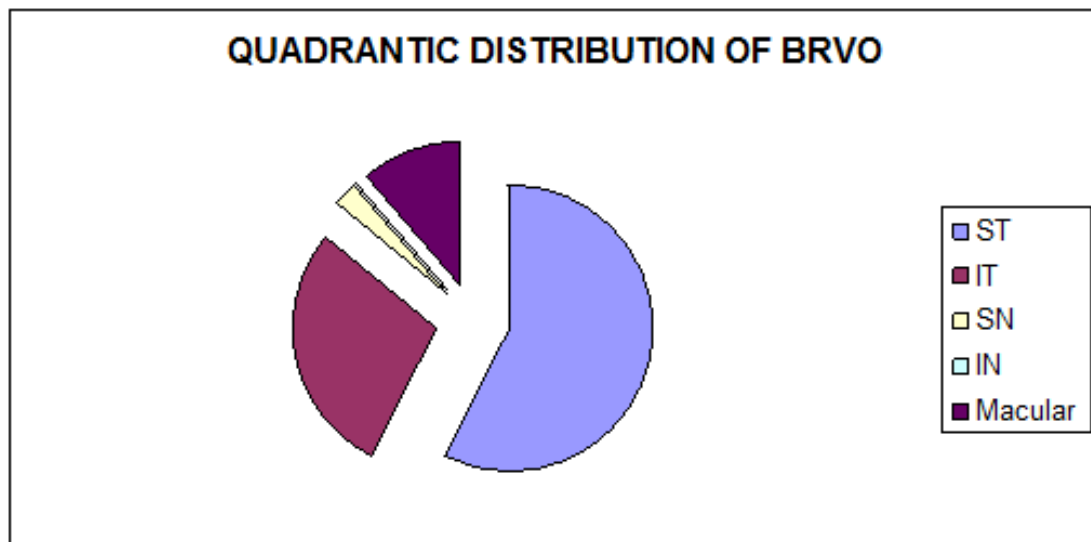


BRVO	Number	Percentage (%)
ST	20	57.14%
IT	10	28.58%
SN	1	2.86%
IN	0	0
Macular	4	11.42%

**Table 4 (HCRVO - Branch Involved)**



## REVIEW ARTICLE



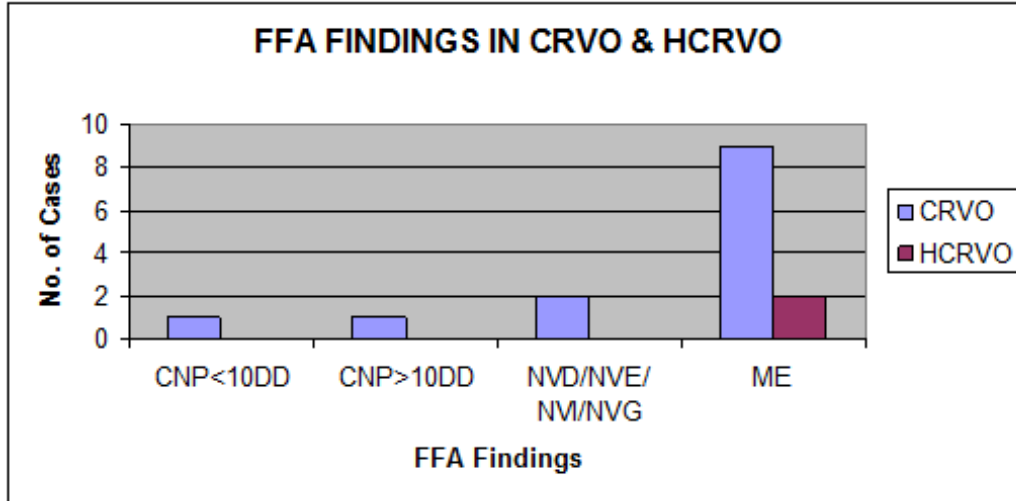
Risk Factors	CRVO (13)	HCRV (2)	BRVO (35)	TOTAL (50)
Male Gender	7(53.85%)	1(50%)	19(54.28%)	27
Hypertension	7(53.85%)	1(50%)	23(65.71%)	33
Diabetes	2(15.38%)	0	8(23.85%)	10
CVS Disease	2(15.38%)	0	3(8.57%)	5
Renal Disease	1(7.69%)	0	1(2.85%)	2
CVA	1(7.69%)	0	1(2.85%)	1
H/O Smoking	3(23.07%)	1(50%)	9(25.71%)	13
Hyperopia	3(23.07%)	0	10(28.57.85%)	22
Cholesterol >200mg%	6(46.15%)	1(50%)	10(28.57%)	17
Elevated IOP >20mm Hg	2(15.38%)	0	4(11.42%)	6
No risk factors	2(15.38%)	0	4(11.42%)	6

**Table 5 (HIGH RISK FACTORS)**

	CNP<10DD	CNP>10DD	NVD/NVE/ NVI/NVG	ME
CRVO	1	1	2	9
HCRVO	-	-	-	2

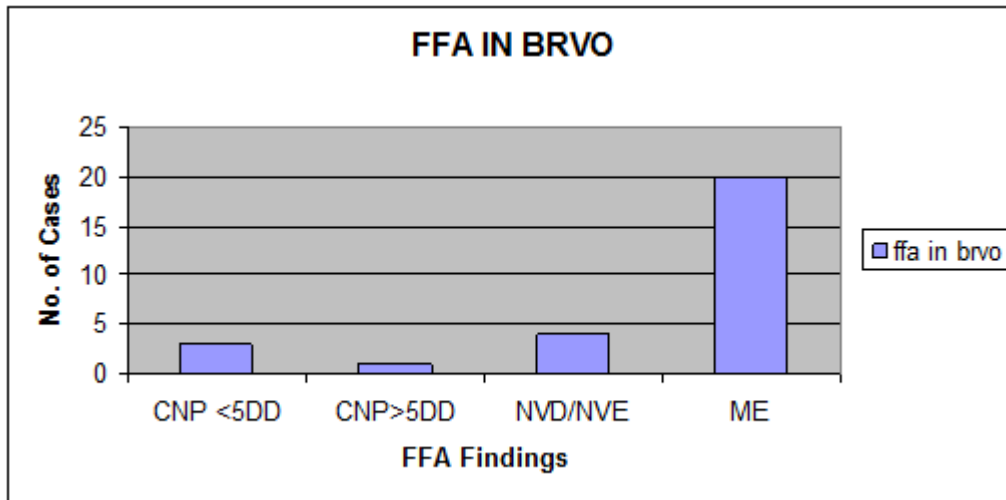
**Table 6 (FFA FINDINGS IN CRVO & HCRVO)**

## REVIEW ARTICLE



CNP < 5DD	CNP > 5DD	NVD/NVE	ME
3	1	4	20

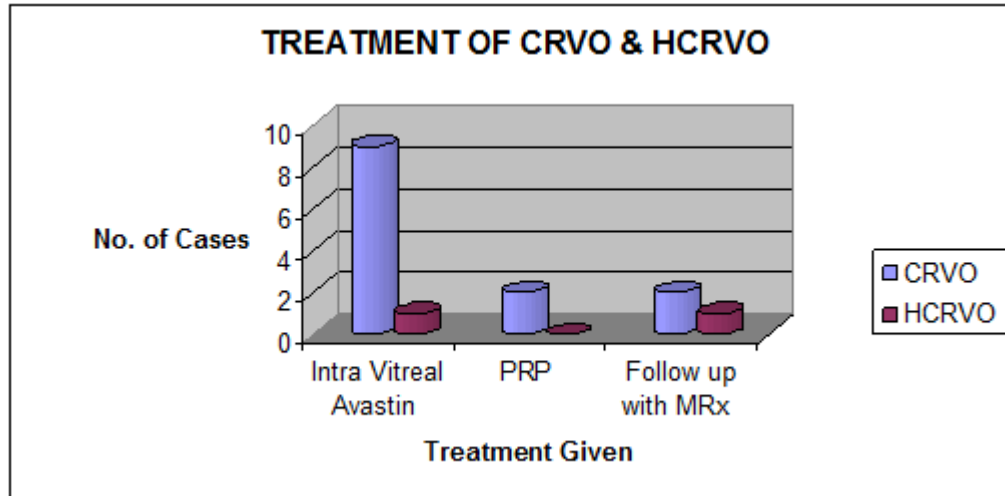
**Table 7 (FFA FINDINGS IN BRVO)**



	CRVO	HCRVO
Intra Vitreal Avastin	9	1
PRP	2	0
Follow up with MRx	2	1

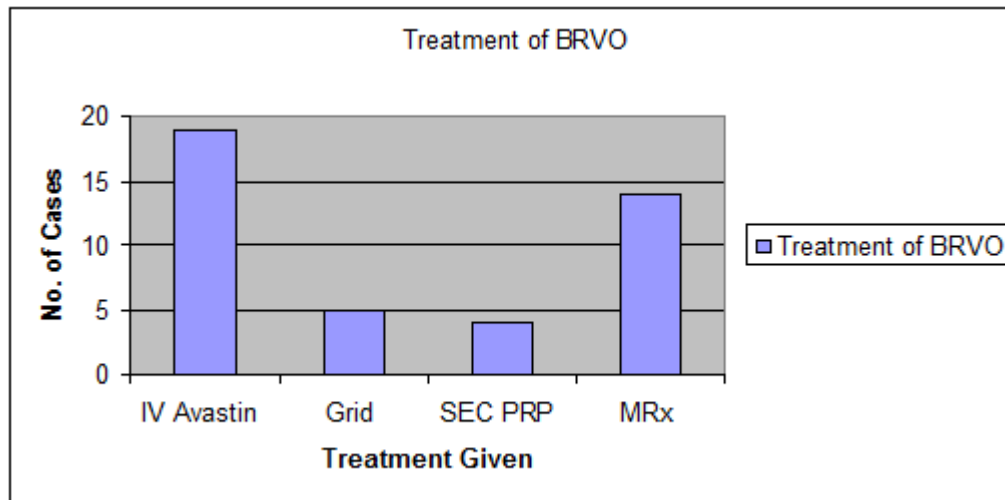
**Table 8 (TREATMENT OF CRVO & HCRVO)**

## REVIEW ARTICLE



Treatment Given	No. of Cases
IV Avastin	19
Grid	5
SEC PRP	4
MRx	14

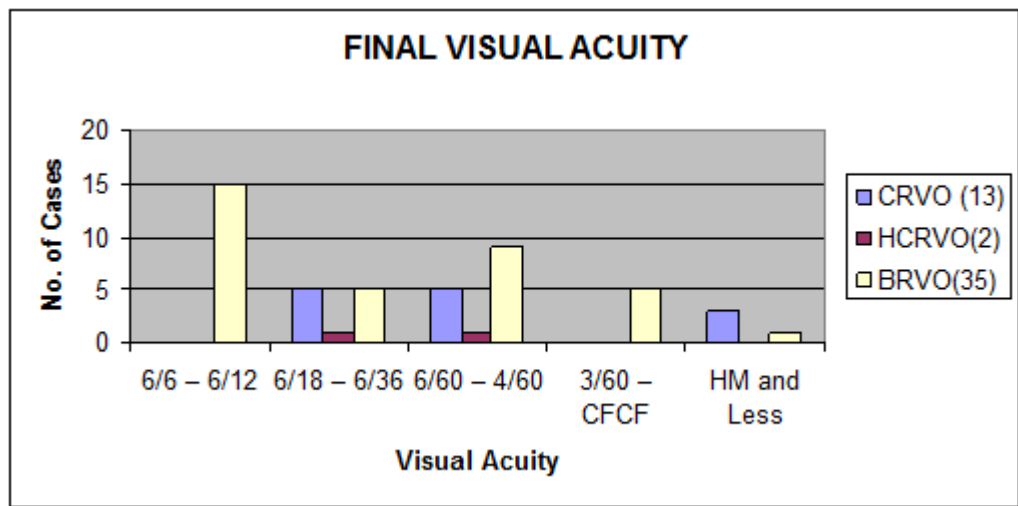
**Table 9 (TREATMENT OF BRVO)**



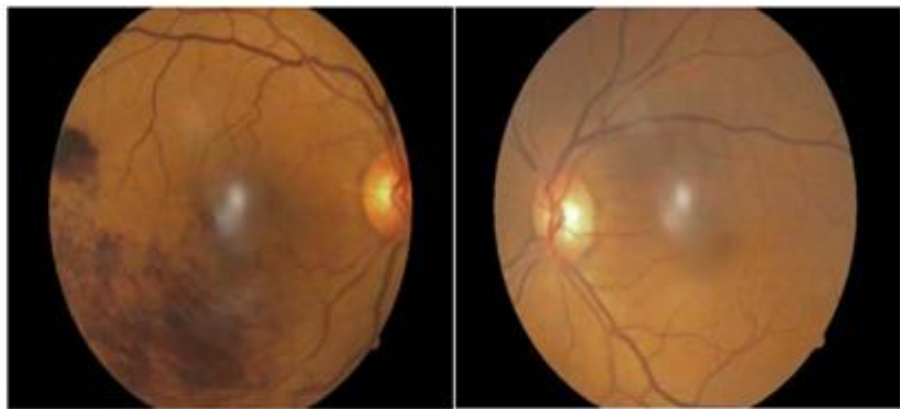
Visual Acuity	CRVO (13)	HCRVO(2)	BRVO(35)
6/6 – 6/12	-	-	15(42.85%)
6/18 – 6/36	5(38.46%)	1(50%)	5(14.28%)
6/60 – 4/60	5(38.46%)	1(50%)	9(25.71%)
3/60 – CFCF	0	-	5(14.28%)
HM and Less	3(23.07%)	-	1(2.85%)

# REVIEW ARTICLE

**Table 10 (Final Visual Acuity)**



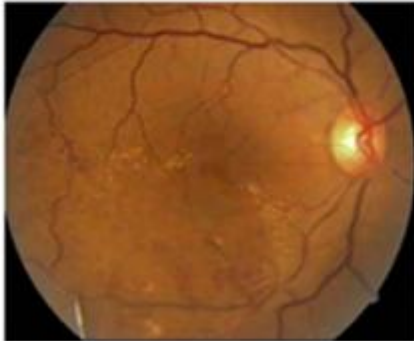
**RIGHT EYE: INFEROTEMPORAL BRVO WITH MACULAR EDEMA WITH GRADE 2 HYPERTENSIVE RETINOPATHY**      **LEFT EYE: GRADE 2 HYPERTENSIVE RETINOPATHY**



# REVIEW ARTICLE

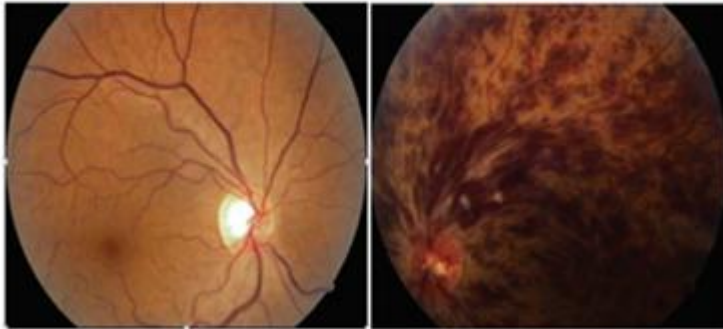
---

RIGHT EYE FOLLOW UP PICTURE AFTER INTRAVITREALAVASTIN

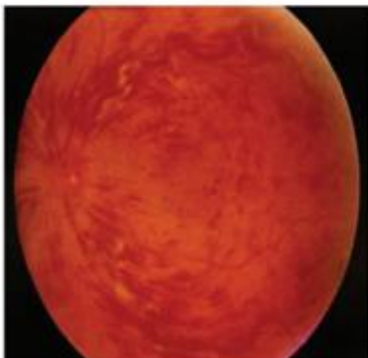


RIGHT EYE: NORMAL FUNDUS

LEFT EYE: CRVO WITH MACULAR EDEMA



LEFT EYE FOLLOW UP PICTURE AFTER INTRA  
VITREAL AVASTIN



## REVIEW ARTICLE

---

### **AUTHORS:**

1. G. Satyavathi
2. G. Serina
3. B. Anusha

### **PARTICULARS OF CONTRIBUTORS:**

1. Assistant Professor, Department of Ophthalmology, Guntur Medical College, Guntur.
2. Assistant Professor, Department of Ophthalmology, Guntur Medical College, Guntur.
3. Resident, Department of Ophthalmology, Guntur Medical College, Guntur.

### **NAME ADDRESS EMAIL ID OF THE CORRESPONDING AUTHOR:**

Dr. G. Satyavathi,  
Flat No. 6,  
Sri Sainadh Towers,  
Post Office Road,  
Kothapet, Guntur.  
E-mail: gsatyavathi1962@yahoo.com

Date of Submission: 13/01/2015.  
Date of Peer Review: 14/01/2015.  
Date of Acceptance: 16/01/2015.  
Date of Publishing: 21/01/2015.