INFLAMMATORY PSEUDOTUMOR OF PAROTID GLAND – A CASE REPORT.

N.S. Thirumaran[1], Smruti Milan Tripathy[2]

HOW TO CITE THIS ARTICLE:
NS Thirumaran, Smruti Milan Tripathy. "Inflammatory pseudotumor of parotid gland – a case report". Journal of Evolution of Medical and Dental Sciences 2013; Vol. 2, Issue 42, October 21; Page: 8115-8118.

ABSTRACT: An inflammatory pseudotumor is a rare clinical condition of unknown etiology and benign course, mimicking sometimes other malignant entities under the clinic and pathologic viewpoint[3]**.** Inflammatory pseudotumor" is a broad descriptive term used to describe a localized collection of inflammatory and fibroblastic cells [4, 8]. It is an uncommon lesion that can present clinically like a tumor[9]. Due to presence of abundant polyclonal plasma cells, its etiology (post inflammatory vs immunologic) is still being debated[6]. We report a case of inflammatory pseudotumor of the parotid in a 61 year old man.
KEYWORDS: parotid gland, inflammatory pseudotumor.

INTRODUCTION: An inflammatory pseudotumor can be defined as a localized mass made up of a fibrous stroma and chronic inflammatory infiltrates with a predominance of plasma cells or histiocytes and an absence of anaplasia and mitotic figures[7,9]. These lesions can be categorized as one of three histopathologic subtypes: (1) those that have a prominent histiocytic component (xanthogranuloma subtype), (2) those that have a prominent plasma cell component (plasma cell granuloma subtype), and (3) those that have marked sclerosing features (hyalinized sclerosing subtype) [11, 15].

These uncommon lesions usually occur in the lung parenchyma; other reported sites include the liver, kidney, thyroid, adrenal glands and choroid plexus of the brain[13]. An inflammatory pseudotumor of the parotid is rare[6]. In this article, we describe a case of inflammatory pseudotumor of parotid and review the histologic and clinical characteristics of this lesion[8].

CASE REPORT: 61 year old man presented with complaints of left sided pre auricular swelling of one year duration. The swelling was gradually increasing in size. It was not associated with pain or difficulty in mouth opening. There was no history of facial weakness or previous history of irradiation. On examination 4x5cm ovoid swelling was seen in the left parotid region, which was non tender and firm in consistency. Swelling had a smooth surface. There was no associated lymphadenopathy. Facial nerve functions were normal. Ear, nose, throat examination were within normal limits.

Fine Needle Aspiration of the swelling was reported as pleomorphic adenoma. However excisional biopsy was advised for confirmation. CT scan of neck plain and contrast showed a well defined homogenous mass in the left parotid gland (fig.1). Patient was investigated and taken up for surgery. Under G.A left total parotidectomy with facial nerve conservation was done (fig. 2). Specimen was sent for histopathological analysis which showed a well circumscribed lesion made up of dense lymphoid & plasma cells in background of scattered spindle cells. Reported as inflammatory pseudotumor of the parotid gland (fig. 3).

DISCUSSION: Inflammatory pseudotumor is a rare tumor like pseudo neoplastic lesion[5]. It has been postulated that they might be the result of a post inflammatory repair process, a metabolic

disturbance, or an antigen-antibody interaction with an agent that was no longer identifiable in aspiration or biopsy material[6]. It occurs more commonly in the lungs, other sites of involvement are liver, kidney, thyroid, adrenal, bladder, skin, spleen and lymph nodes [8, 9]. Inflammatory pseudotumor of the parotid is a very rare condition[4]. It is equally distributed in males and females[9]. The peak age incidence is in the 7th decade[3]. The clinical feature depends on the structures involved and the rate of growth[7].

Morphological appearance in parotid is that of a well circumscribed mass[4]. Cut surface is grey white in color and shows a whorled appearance[5]. Microscopically the tumor shows spindle cells admixed with variable amount of plasma cells, lymphocytes, foamy cells, and polymorphs. Spindle cells show vague fascicles or storiform structures[8]. The plasma cells contain Russell bodies. No mitotic figures were found suggesting the benign nature of the disease[8]. Laboratory findings may be normal or may show elevated erythrocyte sedimentation rate, and C-reactive protein levels and sometimes a high white blood cell count. There is no suggestive literature regarding the presence of positive tumor markers (e.g. alpha fetoproteins, carcinoembryonic antigens) in these lesions. Immunoperoxidase tissue section staining has confirmed the polyclonal nature of the plasma cells, which are primarily positive for immunoglobulins G and A. Neither bacteria nor fungi have been shown to grow in tissue cultures[3]. Calcifications are seldom present in an inflammatory pseudotumor, when they are present they represent a similar but distinct pathologic entity called calcifying fibrous pseudotumor[3]. These pseudotumors usually originate in the soft tissues of the extremities, and they exhibit extensive concentric psammomatous or dystrophic calcifications[9].

CONCLUSION: Inflammatory pseudotumor of parotid is rare entity and can clinically mimic any malignant growth. Clinical scenario and CT scan findings are usually non specific so other diseases including inflammatory or malignant processes should be ruled out. FNAC may not be conclusive, thus a biopsy is necessary to confirm the diagnosis. When a patient has a very slow growing lesion, the possibility of an inflammatory pseudotumor should be considered.

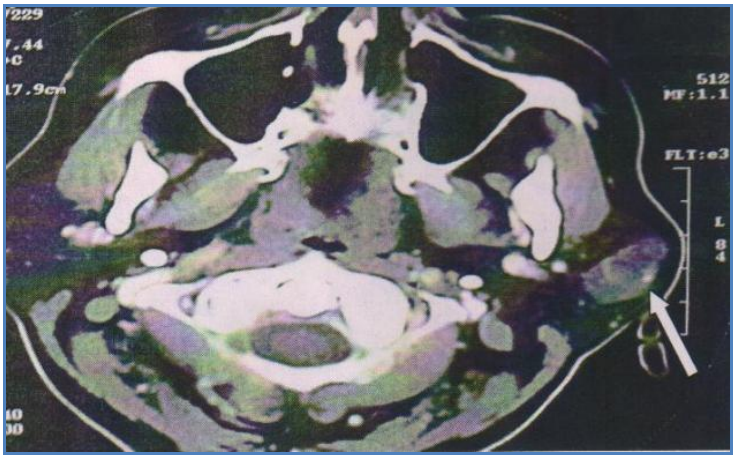

Fig.1: CT Scan picture of parotid tumor.

Fig.2: Tumor with preserved facial nerve.

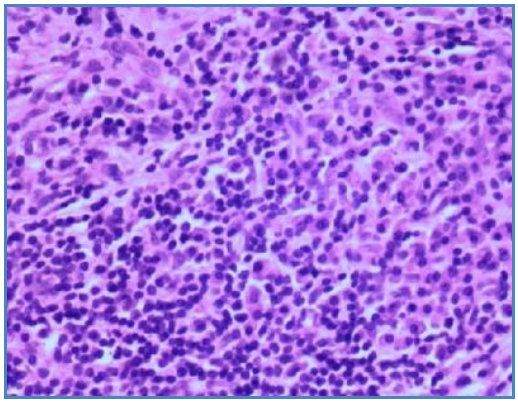

Fig.3: Histopathological slide.

REFERENCE:

1. Bahadori, M. and A. A. Liebow. Plasma cell granulomas of the lung. Cancer 1973. 31:191–208.
2. Spencer, H. The pulmonary plasma cell/histiocytoma complex. Histopathology 1984. 8:903–916.
3. Hurt, M. A. and D. J. Santa Cruz. Cutaneous inflammatory pseudotumor lesions resembling "inflammatory pseudotumors" or "plasma cell granulomas" of extra cutaneous sites. Am J Surg Pathol 1990. 14:764–773.
4. Thomas, R. M., E. S. Jaffe, A. Zaerate-Osorno, and L. J. Medeiros. Inflammatory pseudotumor of the spleen. Arch Pathol Lab Med 1993. 117:921–926.
5. Coffin, C. M., J. Watterson, J. R. Priest, and L. P. Dehner. Extrapulmonary inflammatory myofibroblastic tumor (inflammatory pseudotumor): a clinicopathologic and immunohistochemical study of 84 cases. Am J Surg Pathol 1995. 19:859–872.
6. Ballesteros, E., B. M. Osborne, and A. Y. Matsushima. Plasma cell granuloma of the oral cavity: a report of two cases and review of the literature. Mod Pathol 1998. 11:60–64.

7. Isaacson, P. G. and A. J. Norton. Extranodal Lymphomas. New York, NY: Churchill Livingstone; 1994.
8. Hussong, J. W., S. L. Perkins, B. Schnitzer, H. Hargreaves, and G. Frizzera. Extramedullary plasmacytoma: a form of marginal zone cell lymphoma? Am J Clin Pathol 1999. 111:111–116.
9. Schmid, U., D. Helbron, and K. Lennert. Development of malignant lymphoma in myoepithelial sialoadenitis (Sjögren's syndrome). Virchows Arch A Pathol Anat Histopathol 1982. 395:11–43.
10. Williams, S. B., R. D. Foss, and G. L. Ellis. Inflammatory pseudotumors of the major salivary glands: clinicopathologic and immunohistochemical analysis of six cases. Am J Surg Pathol 1992. 16:896–902.
11. Wan, J. H., K. J. Trainor, M. J. Brisco, and A. A. Morley. Monoclonality in B cell lymphoma detected in paraffin wax embedded sections using the polymerase chain reaction. J Clin Pathol 1990. 43:888–890.
12. Arber, D. A., O. W. Kamel, and M. van De Rijn. et al. Frequent presence of the Epstein-Barr virus in inflammatory pseudotumor. Hum Pathol 1995. 26:1093–1998.
13. Hyjek, E., W. J. Smith, and P. G. Isaacson. Primary B-cell lymphoma of salivary glands and its relationship to myoepithelial sialoadenitis. Hum Pathol 1988. 19:766–776.
14. Patsouris, E., H. Noël, and K. Lennert. Lymphoplasmacytic/ lympho plasmacytoid immunocytoma with a high content of epithelioid cells: histologic and immunohistochemical findings. Am J Surg Pathol 1990. 14:660–670.
15. Diss, T. C., A. C. Wotherspoon, P. Speight, L. Pan, and P. G. Isaacson. B-cell monoclonality, Epstein-Barr virus, and t (14; 18) in myoepithelial sialoadenitis and low-grade B-cell MALT lymphoma of the parotid gland. Am J Surg Pathol 1995. 19:531–536.

AUTHORS:

1. N.S. Thirumaran
2. Smruti Milan Tripathy

PARTICULARS OF CONTRIBUTORS:

1. Associate Professor, Department of ENT (Otorhinolaryngology), Saveetha Medical College and Hospital.
2. Assistant Professor, Department of ENT (Otorhinolaryngology), Saveetha Medical College and Hospital.

NAME ADDRESS EMAIL ID OF THE CORRESPONDING AUTHOR:

Dr. N.S. Thirumaran,
Plot No. 4, 2nd Street,
Kongu Nagar,
Mugappair, Chennai – 37.
Email – nsthirumaran@yahoo.com
Coolmilan80@gmail.com

Date of Submission: 07/10/2013.
Date of Peer Review: 08/10/2013.
Date of Acceptance: 11/10/2013.
Date of Publishing: 17/10/2013.